


Medbone®
BIOMATERIALS

Medbone® | Biomaterials, engineering life.™

Clinical Cases

adbone[®] TCP



Medbone[®]
BIOMATERIALS

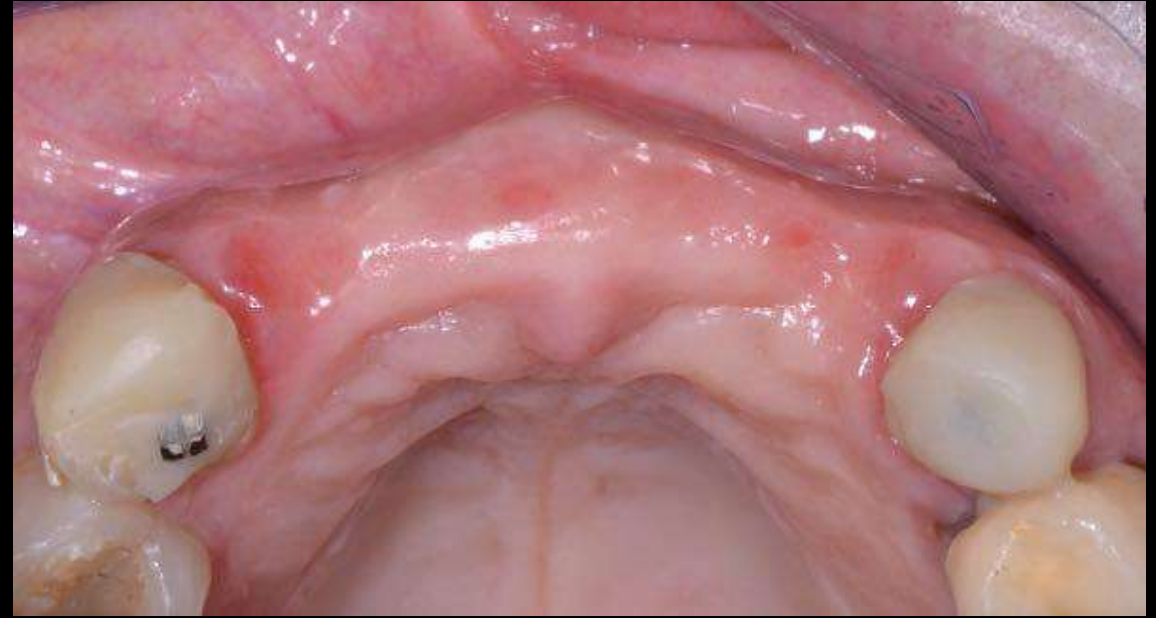
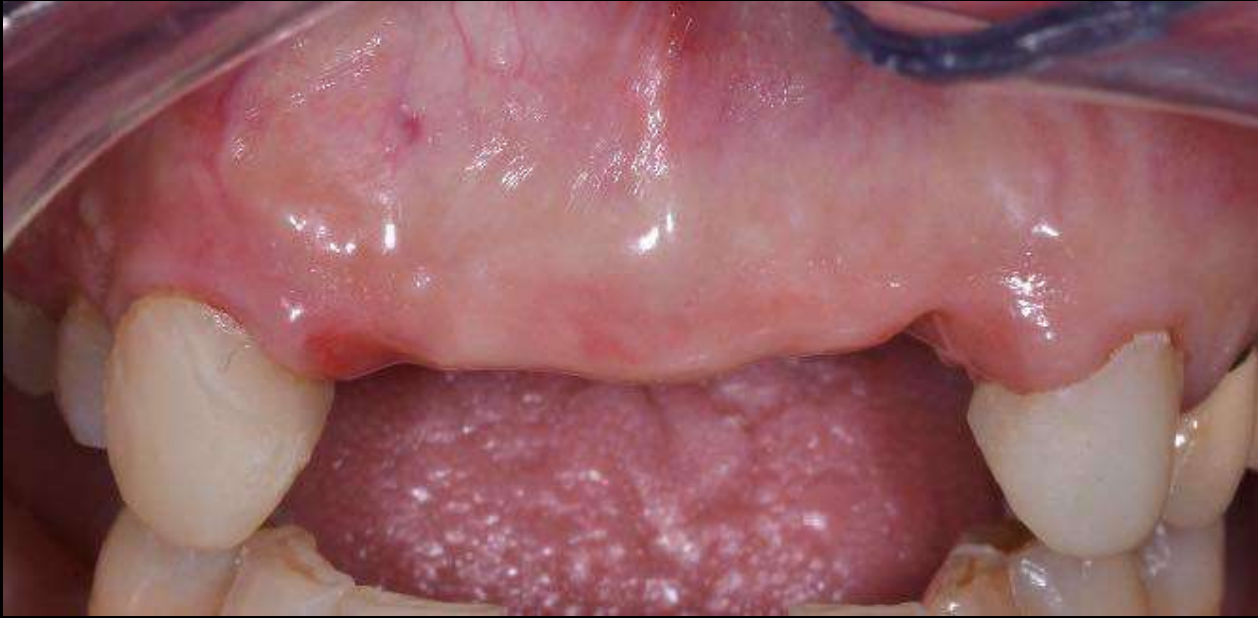Dr. João Gaspar



Medbone®
BIOMATERIALS

CASE 1

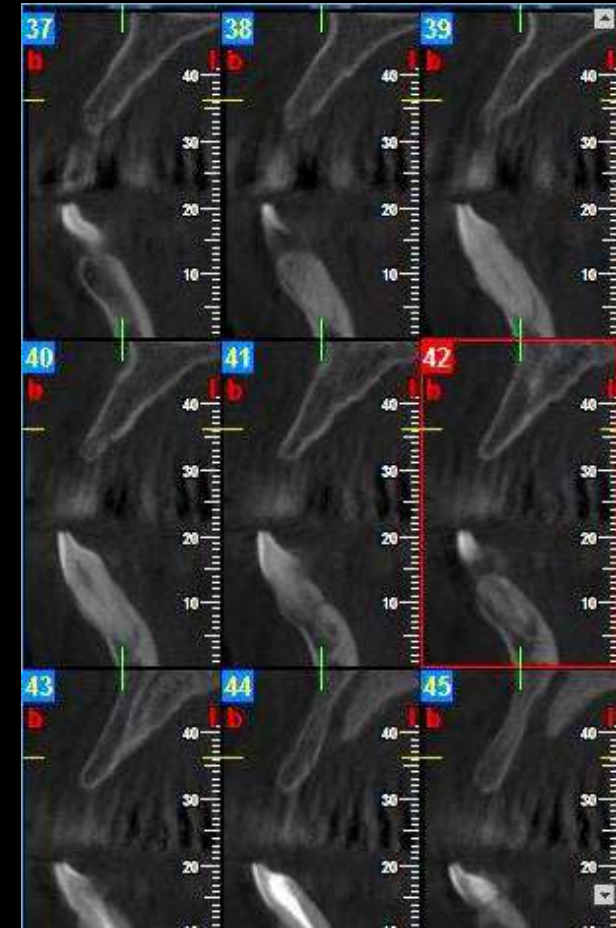
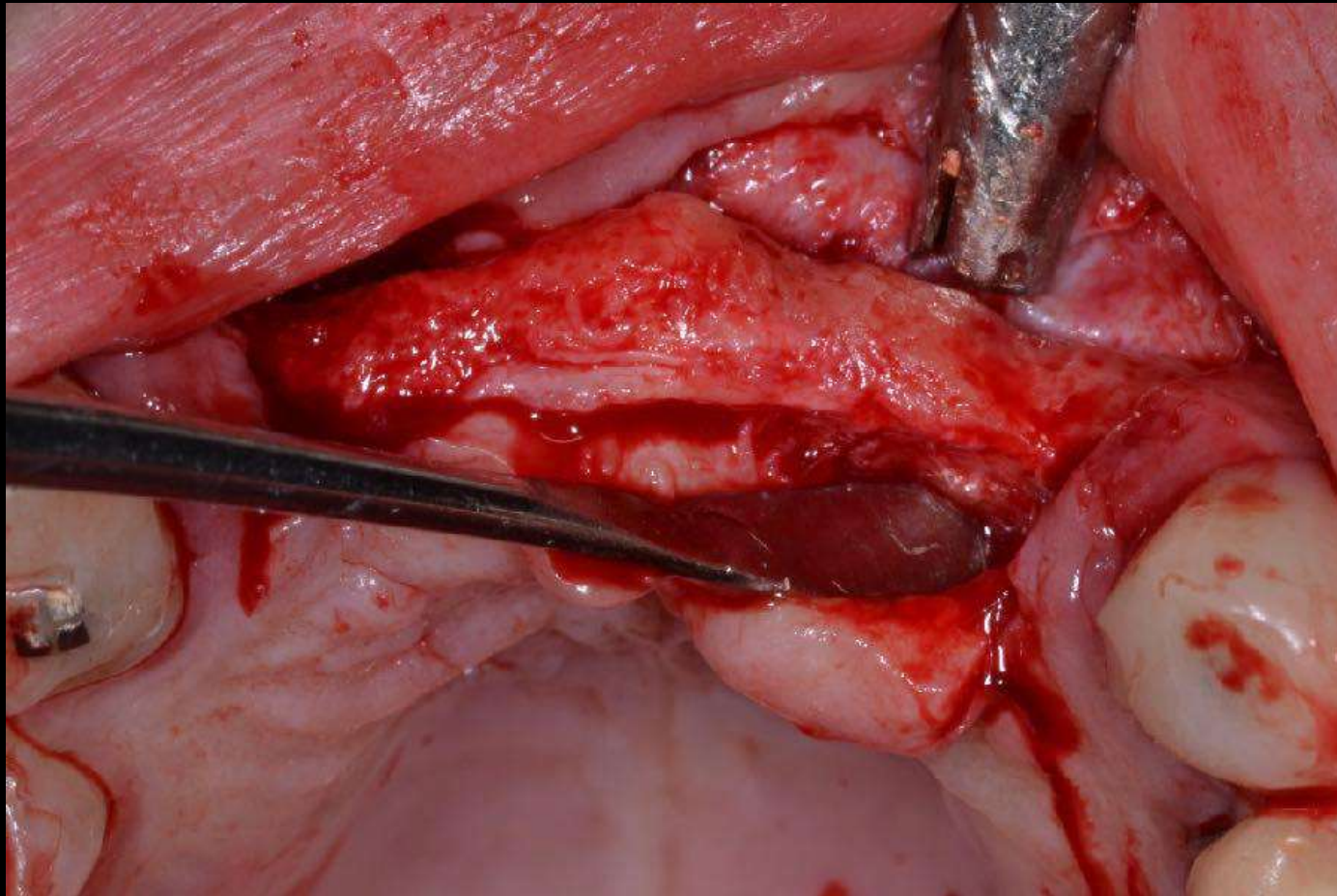
adbone® TCP



Dr. João Gaspar



www.medbone.eu

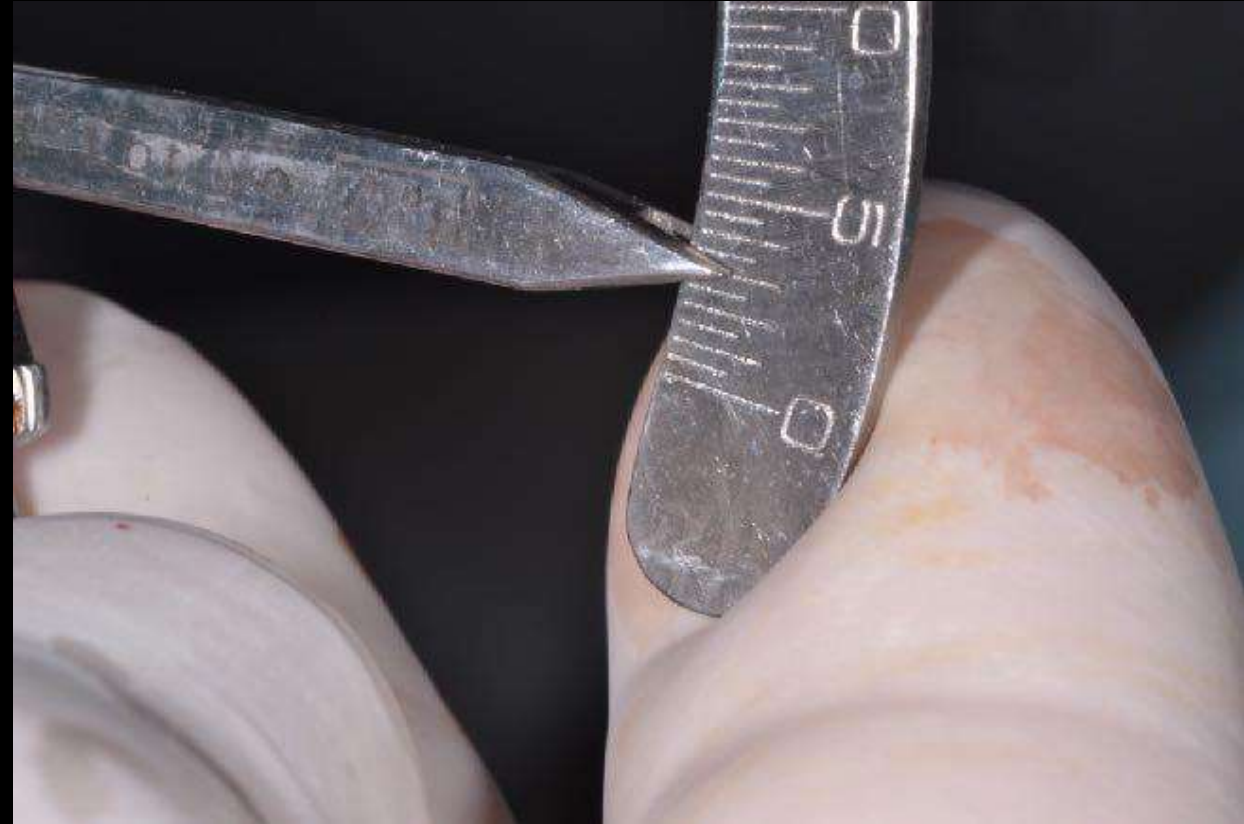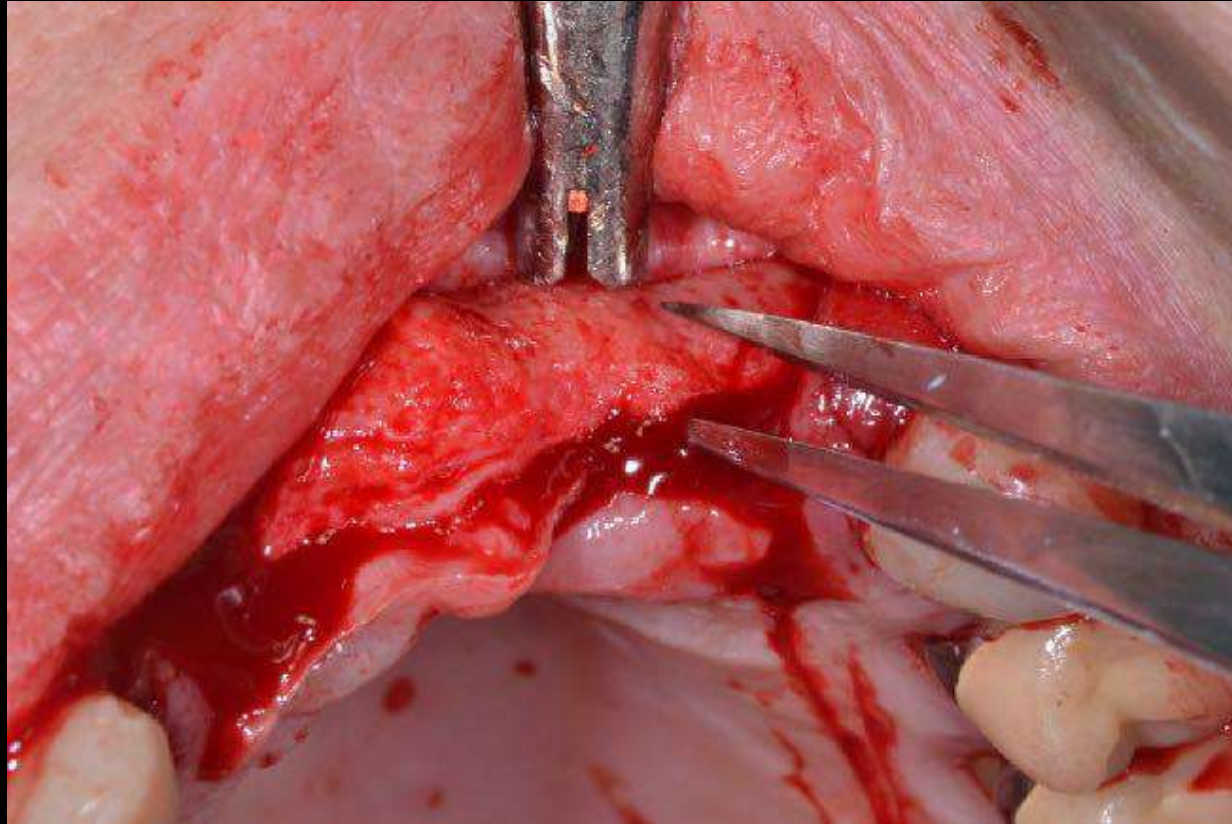


Dr. João Gaspar



www.medbone.eu

3,0 mm espessura de crista

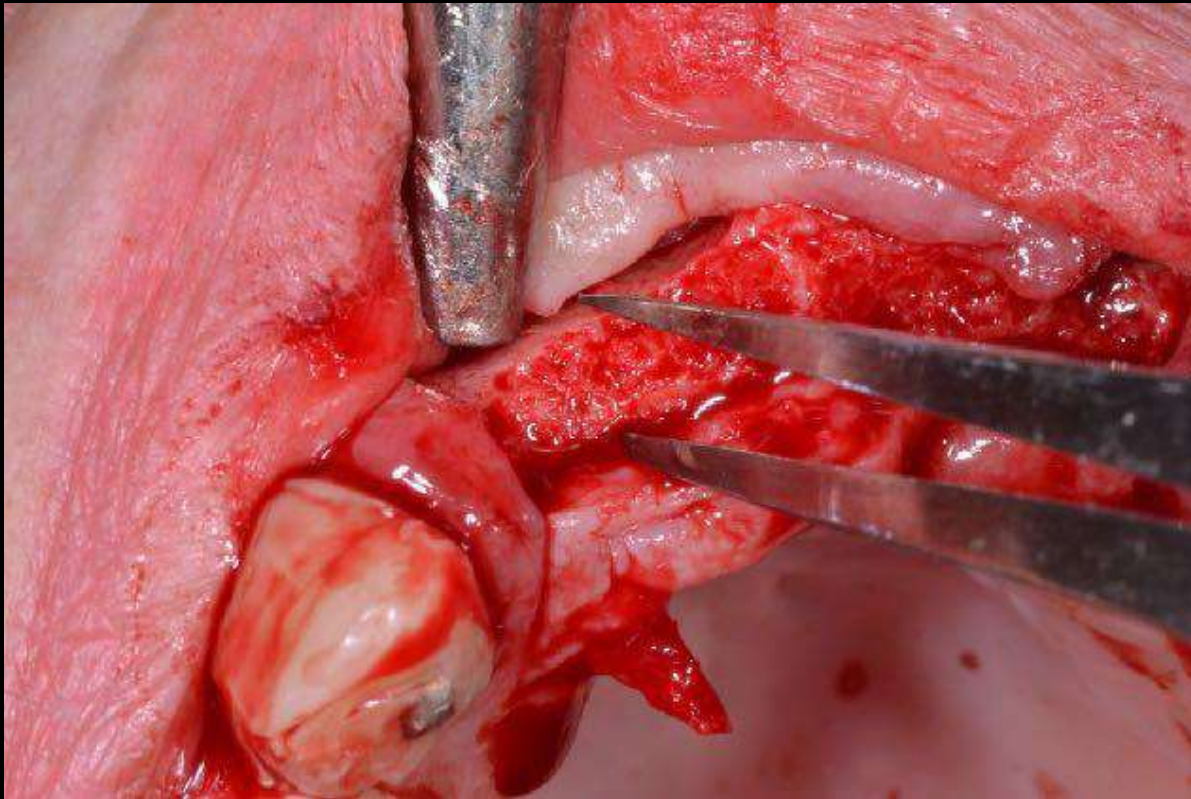


Dr. João Gaspar



www.medbone.eu

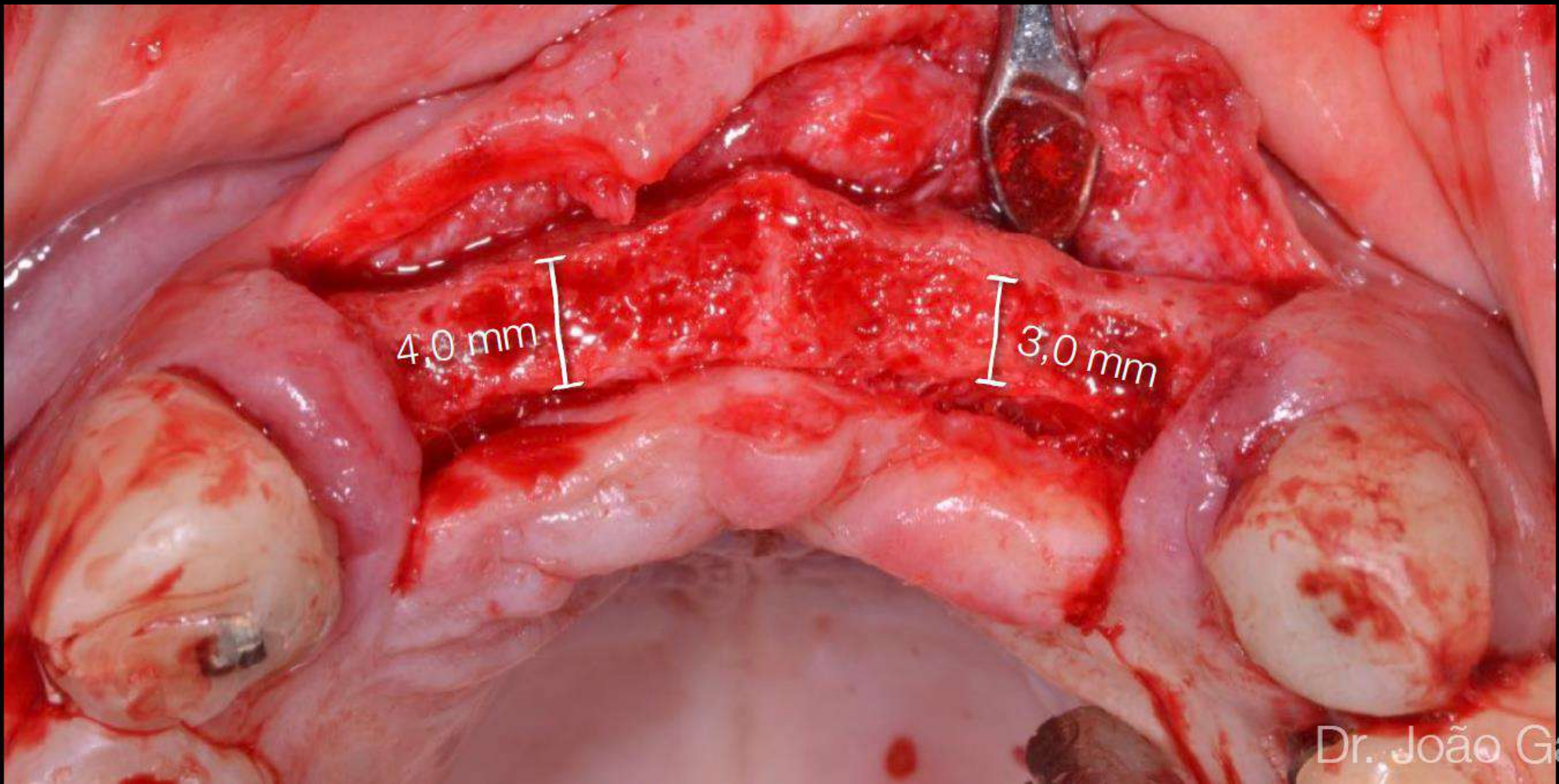
4,0 mm espessura de crista



Dr. João Gaspar



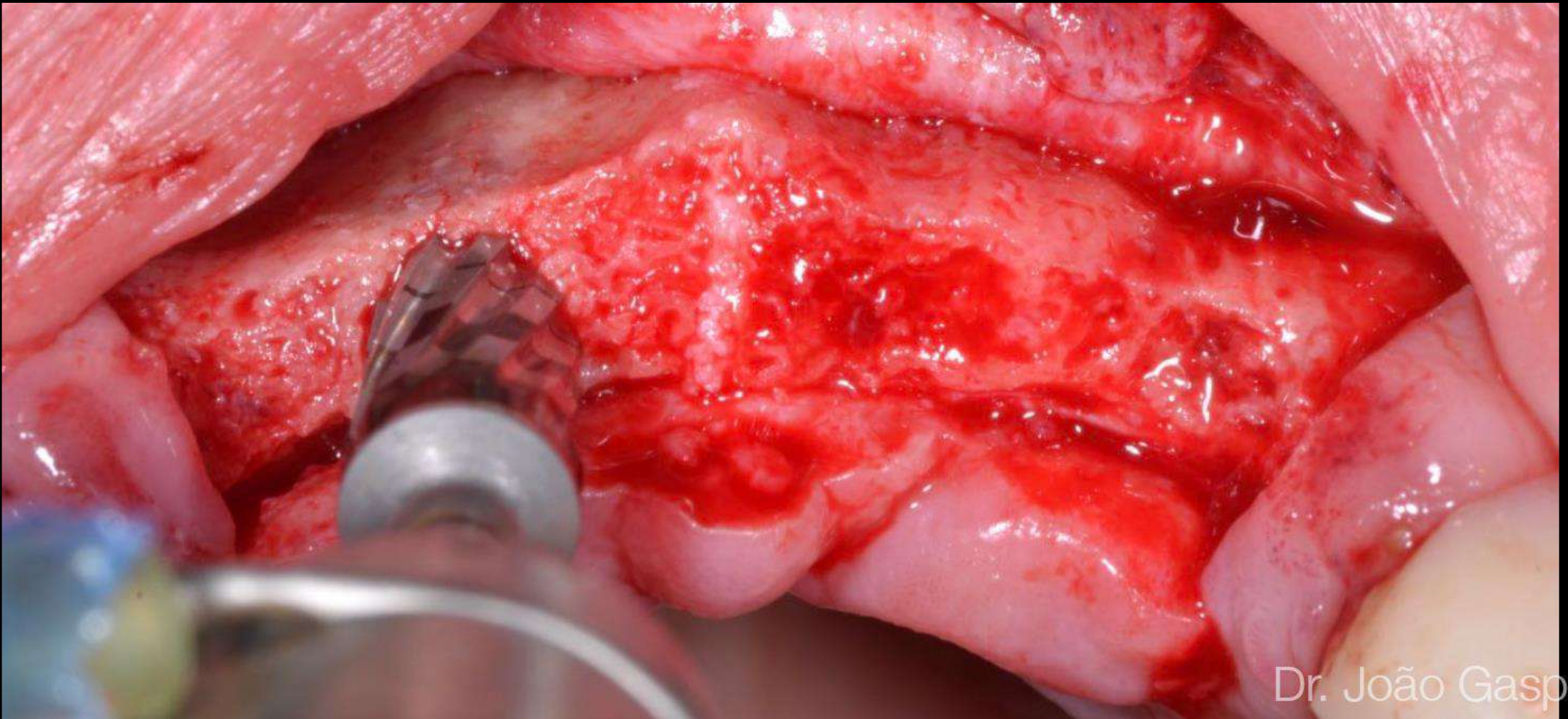
www.medbone.eu



Dr. João Gaspar



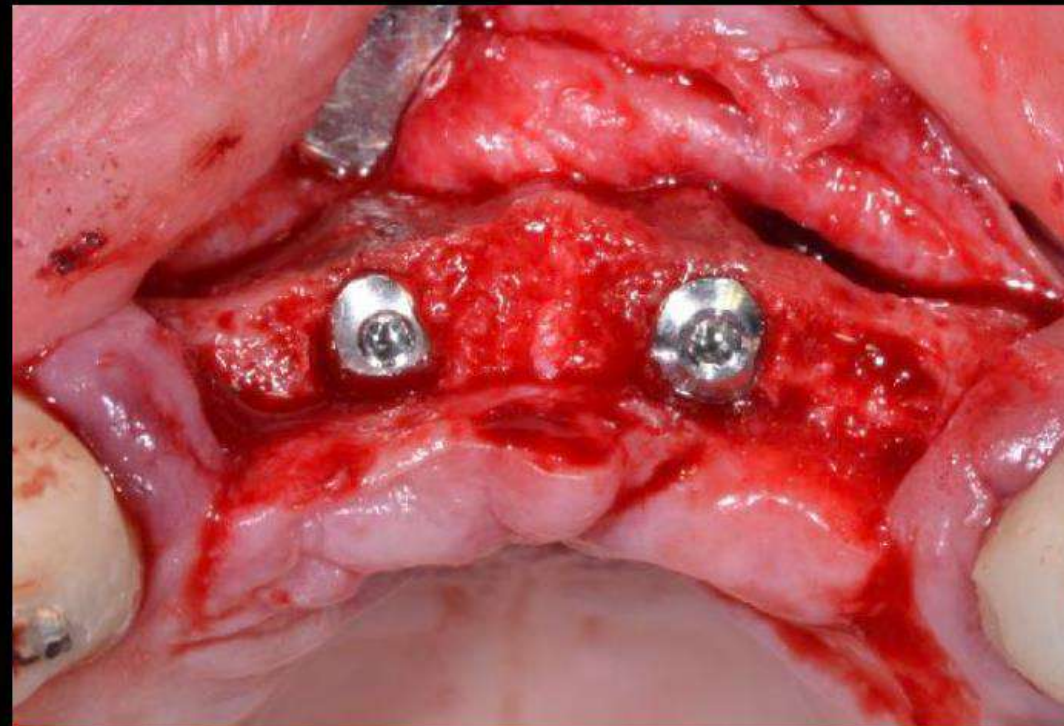
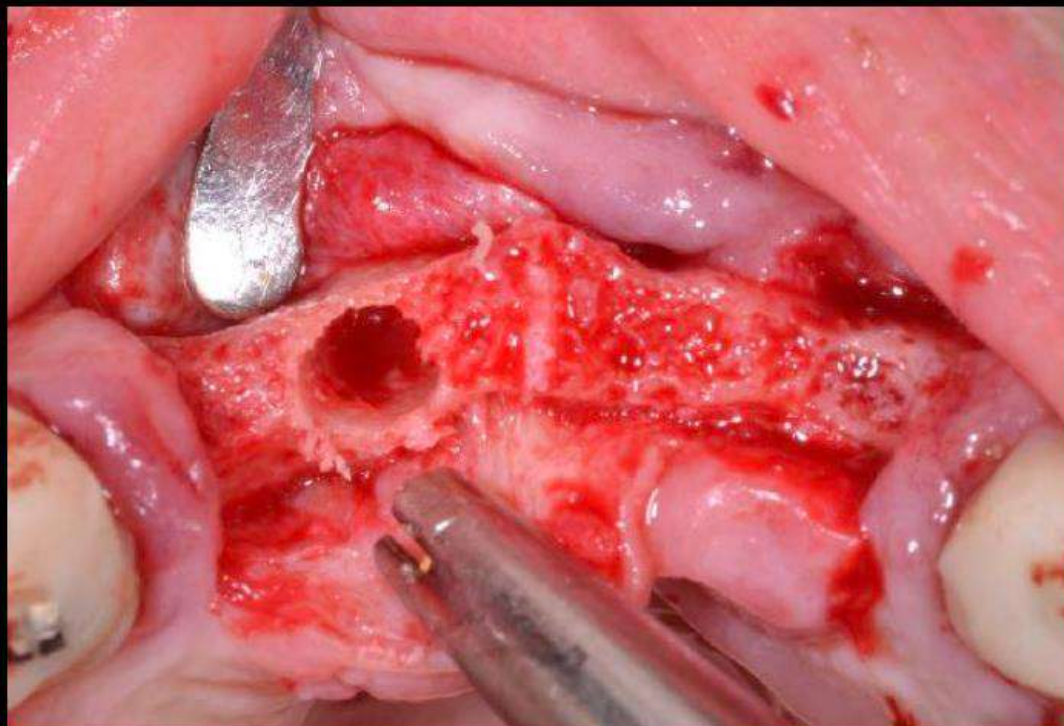
www.medbone.eu



Dr. João Gaspar



www.medbone.eu

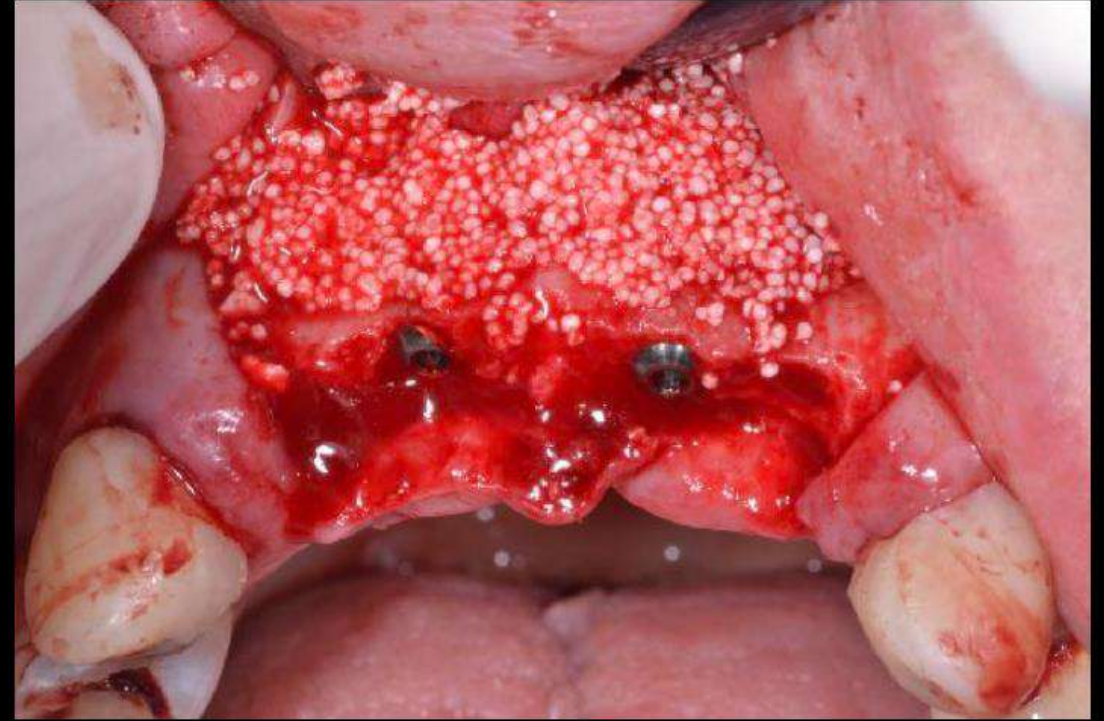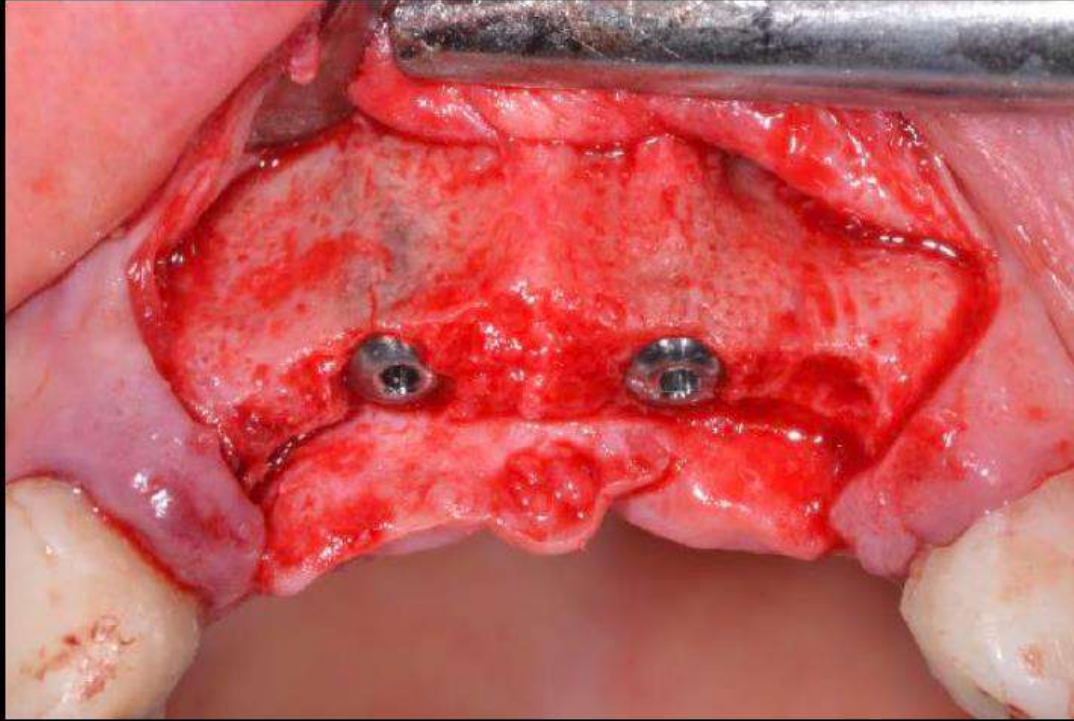


Dr. João Gaspar

Dr. João Gaspar



www.medbone.eu



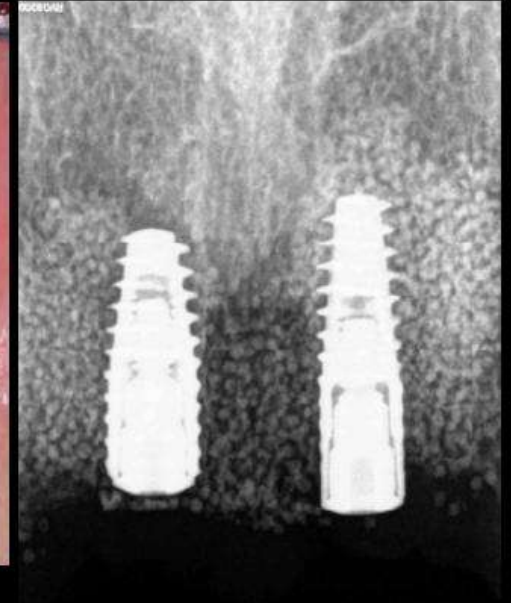
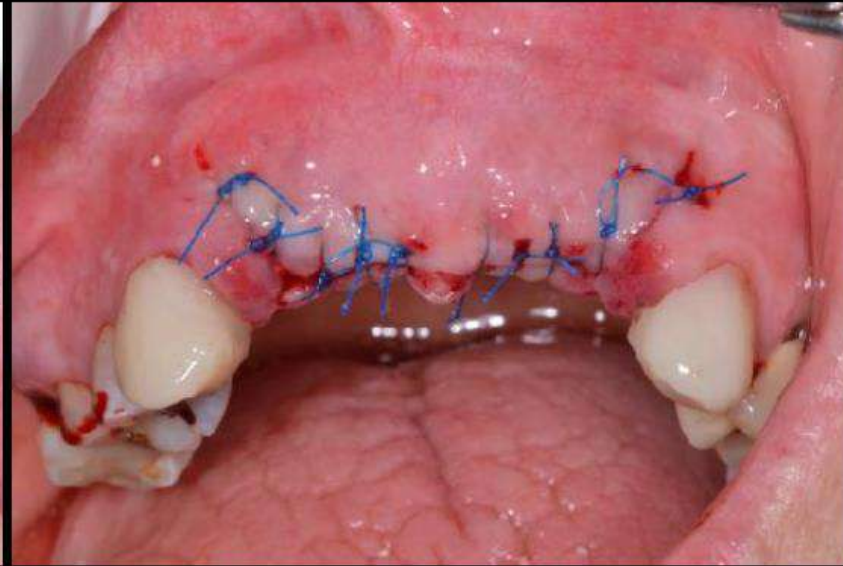
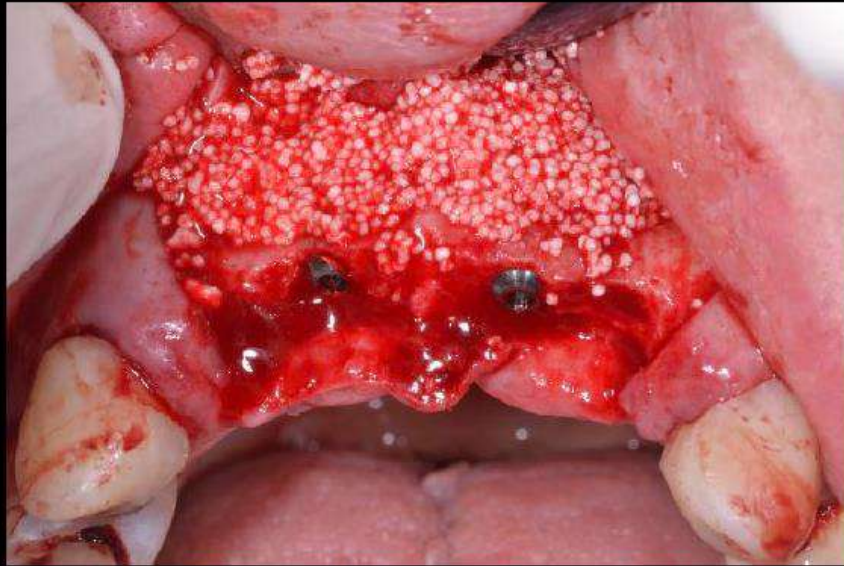AdBone TCP

Dr. João Gaspar

Dr. João Gaspar



www.medbone.eu



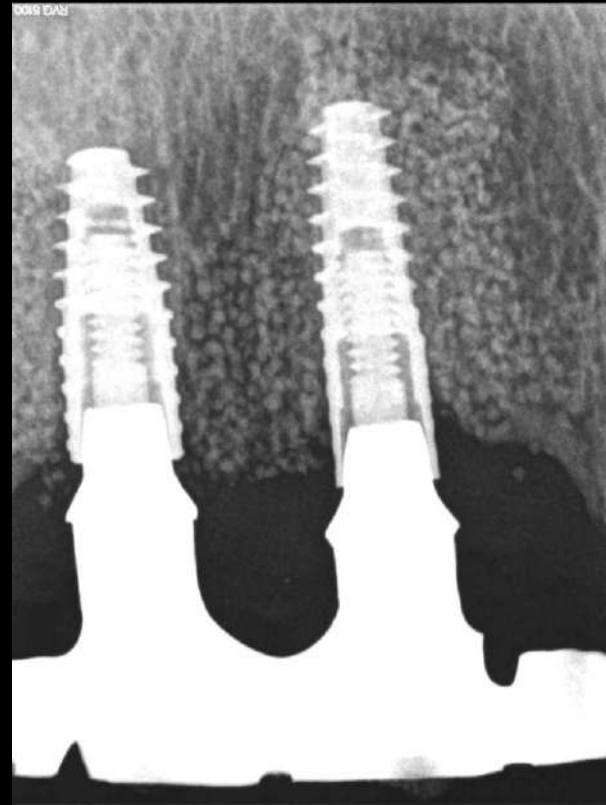
Dr. João Gaspar

Dr. João Gaspar



www.medbone.eu

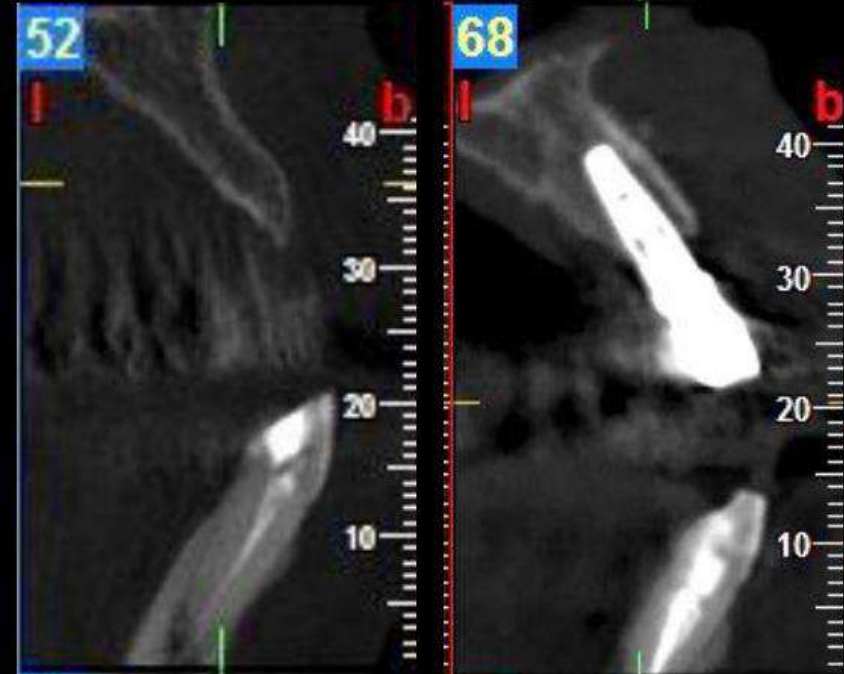
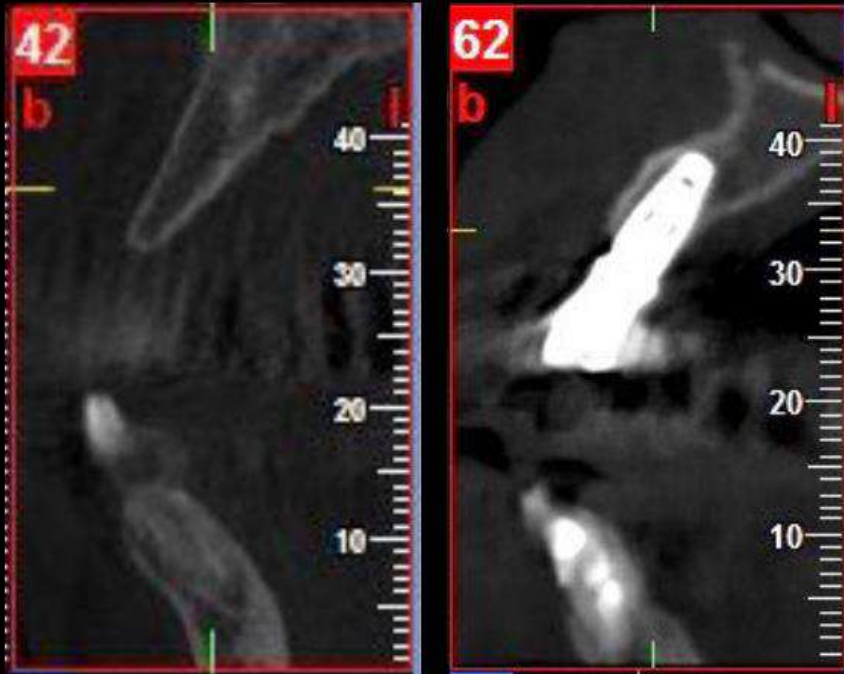
6 meses pós-op



Dr. João Gaspar



www.medbone.eu



1 ano pós-op

Dr. João Gaspar

Dr. João Gaspar



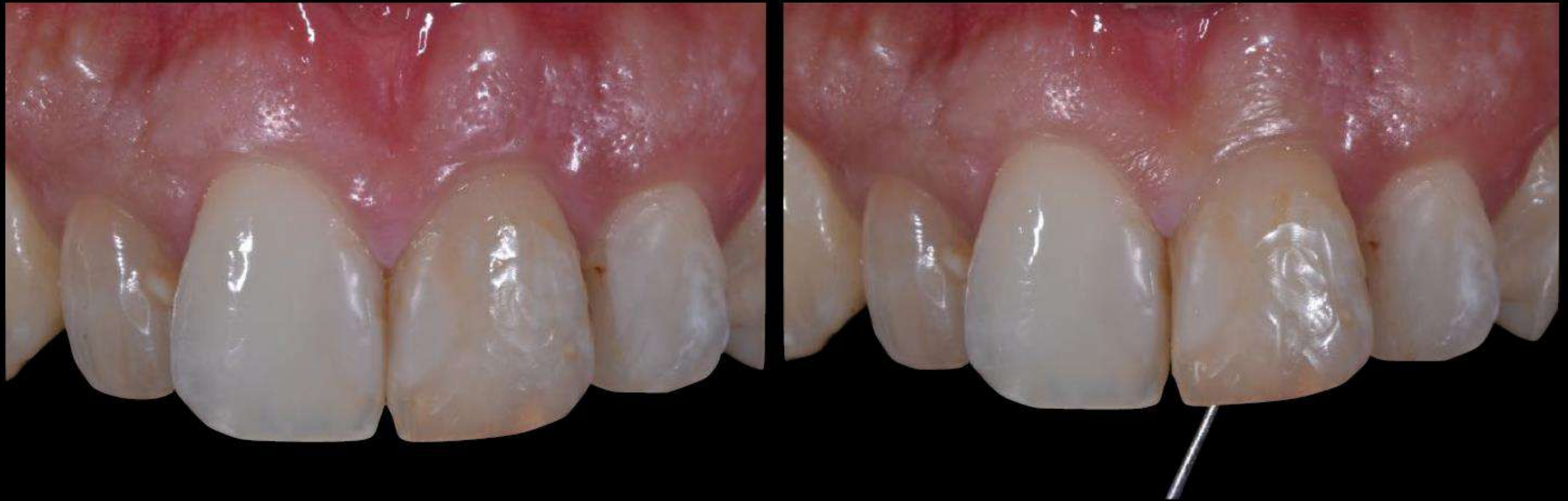www.medbone.eu



Medbone®
BIOMATERIALS

CASE 2

adbone® TCP

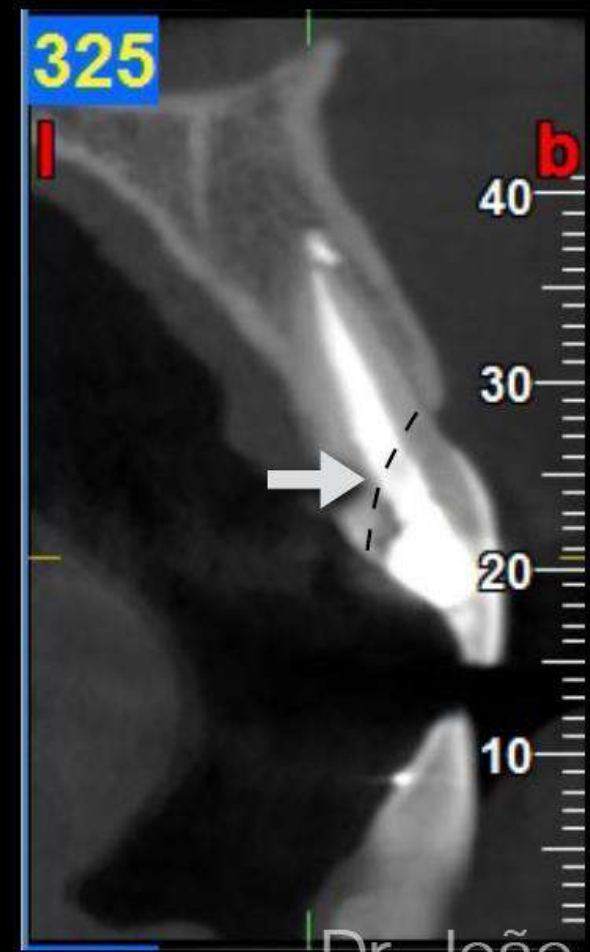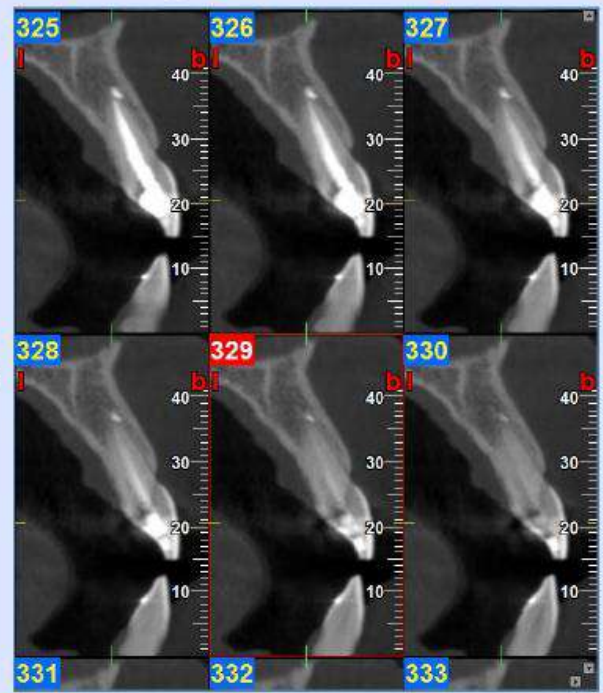
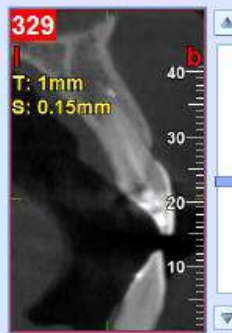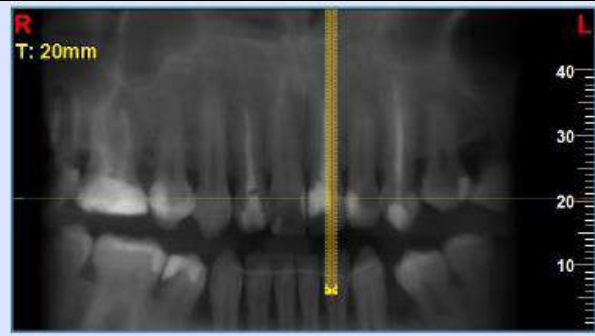
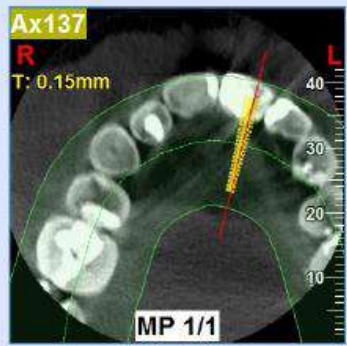


Dr. João Gaspar

Dr. João Gaspar



www.medbone.eu

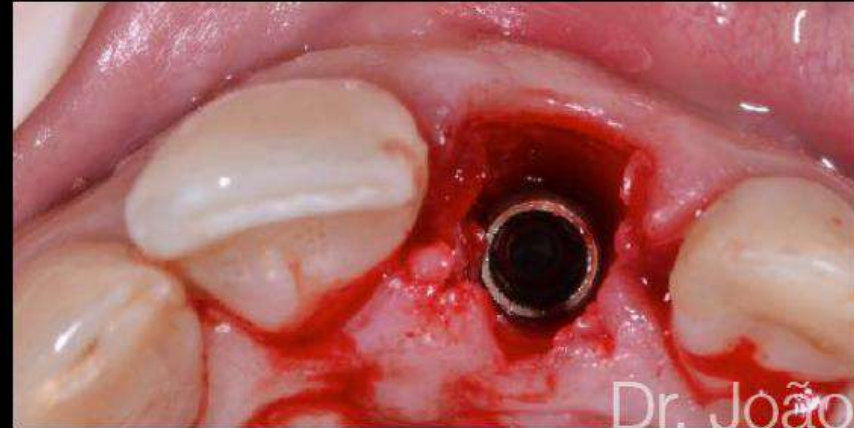
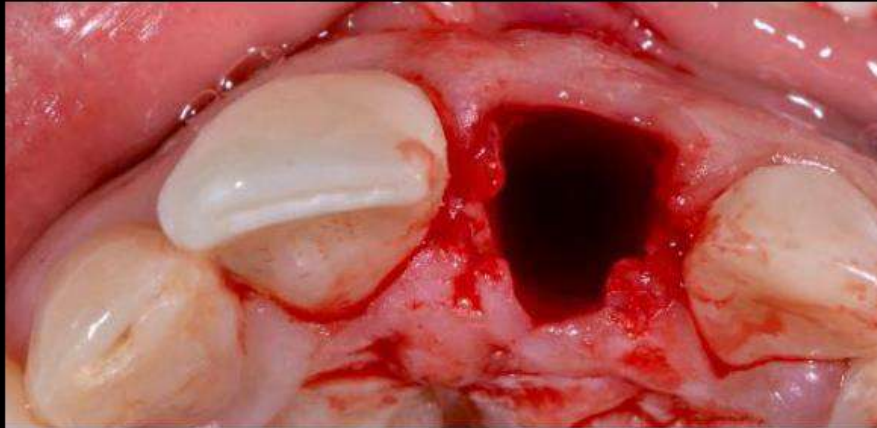
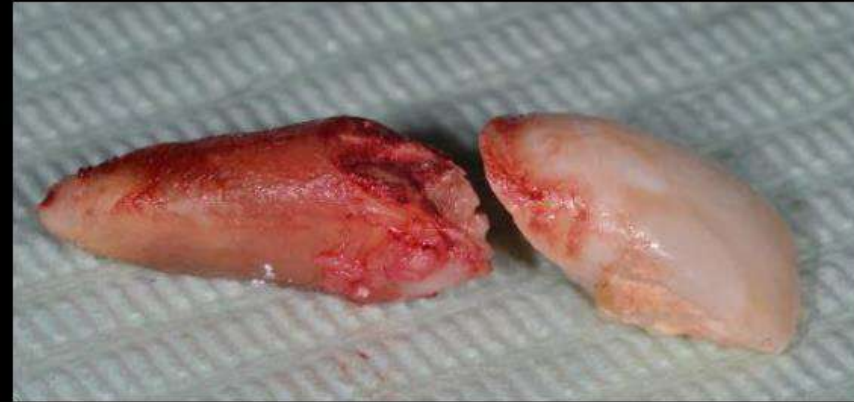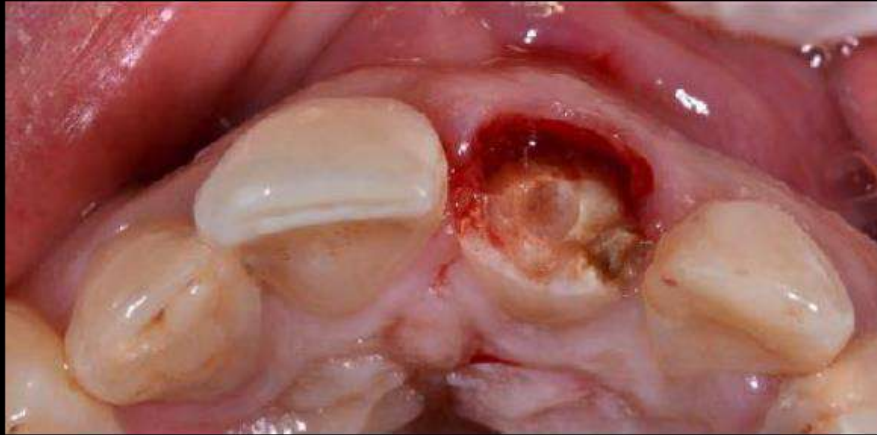


Dr. João Gaspar

Dr. João Gaspar



www.medbone.eu

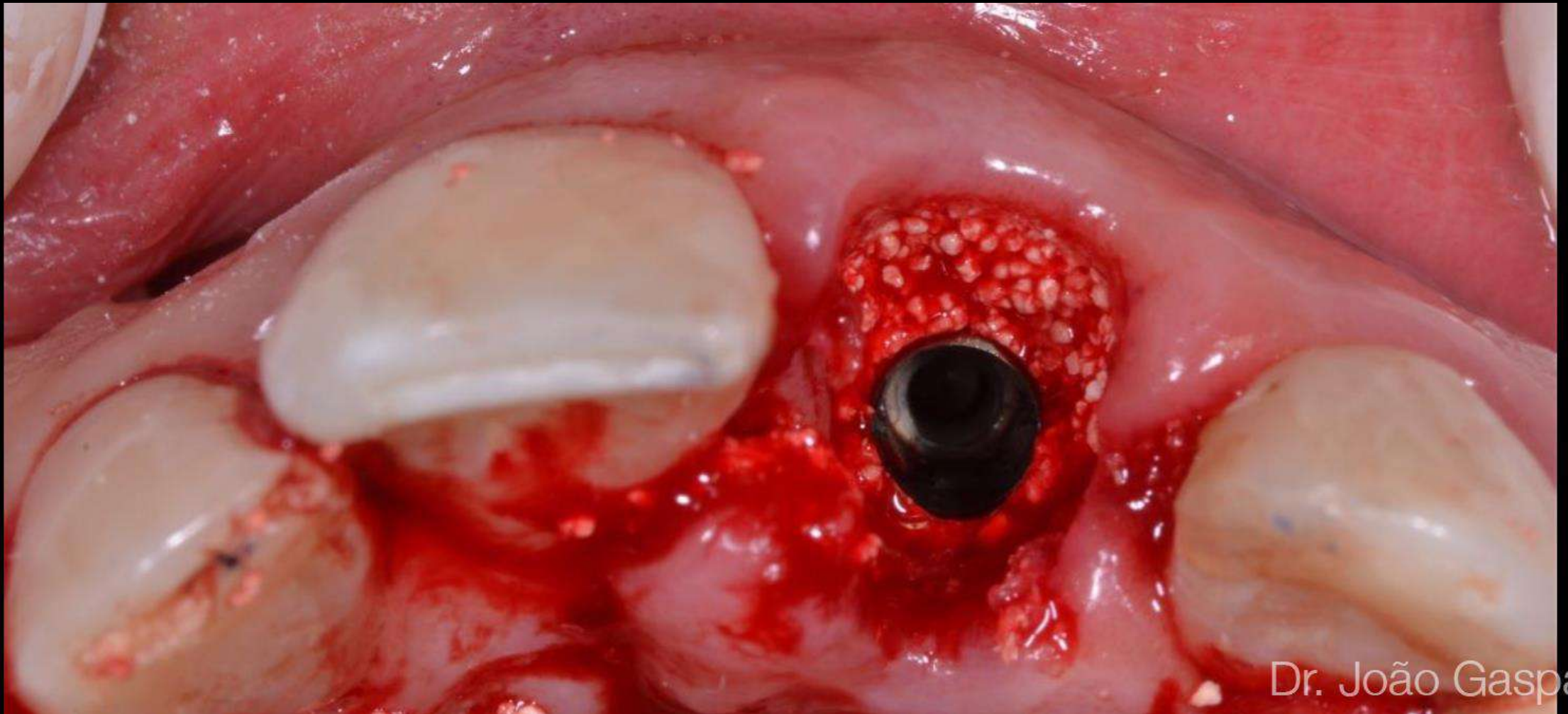


Dr. João Gaspar

Dr. João Gaspar



www.medbone.eu

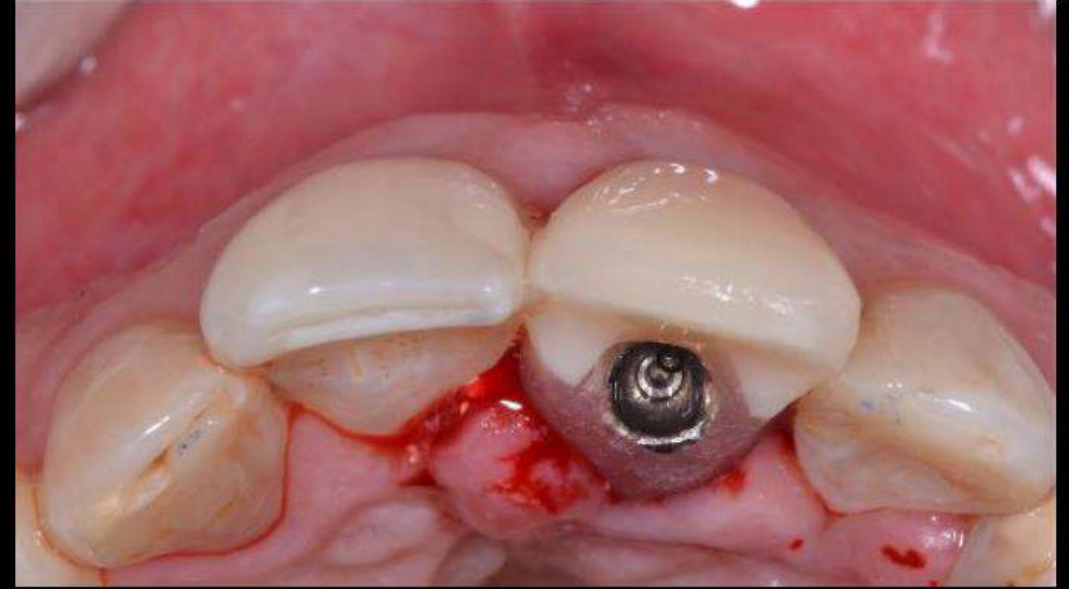
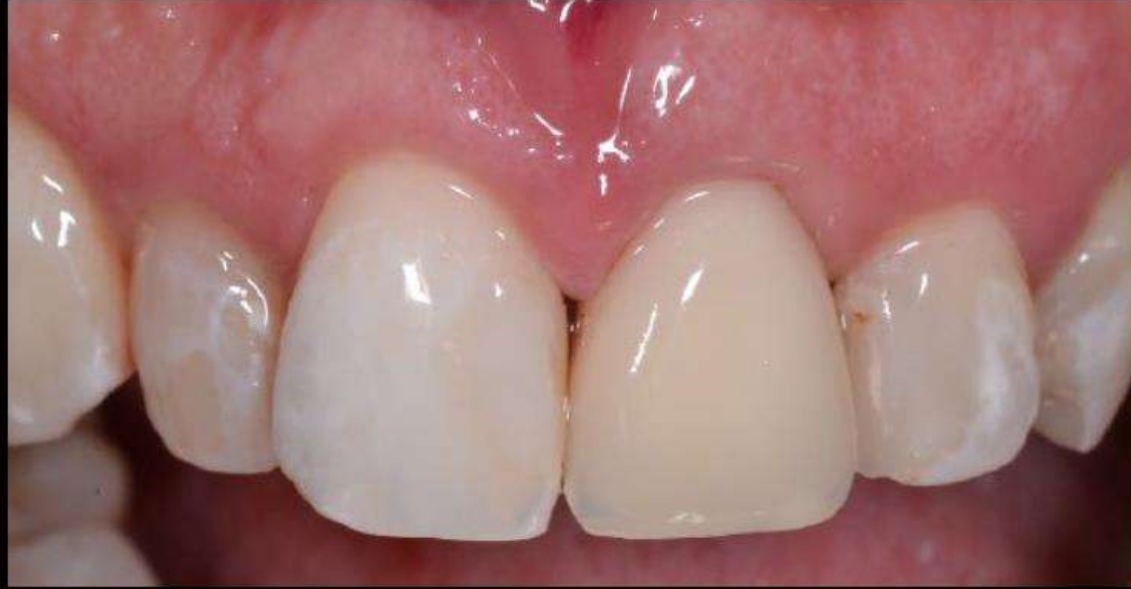

Dr. João Gaspar

Dr. João Gaspar



www.medbone.eu

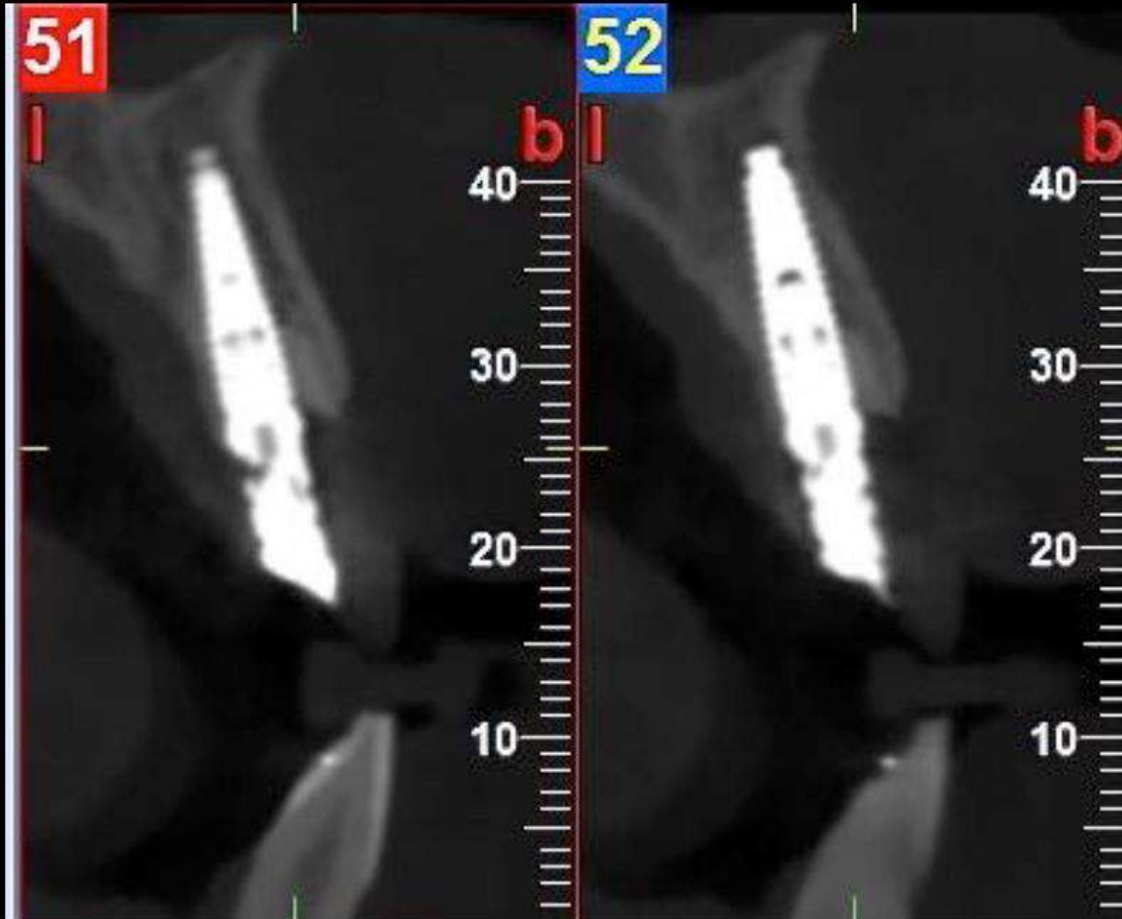


Dr. João Gaspar

Dr. João Gaspar



www.medbone.eu



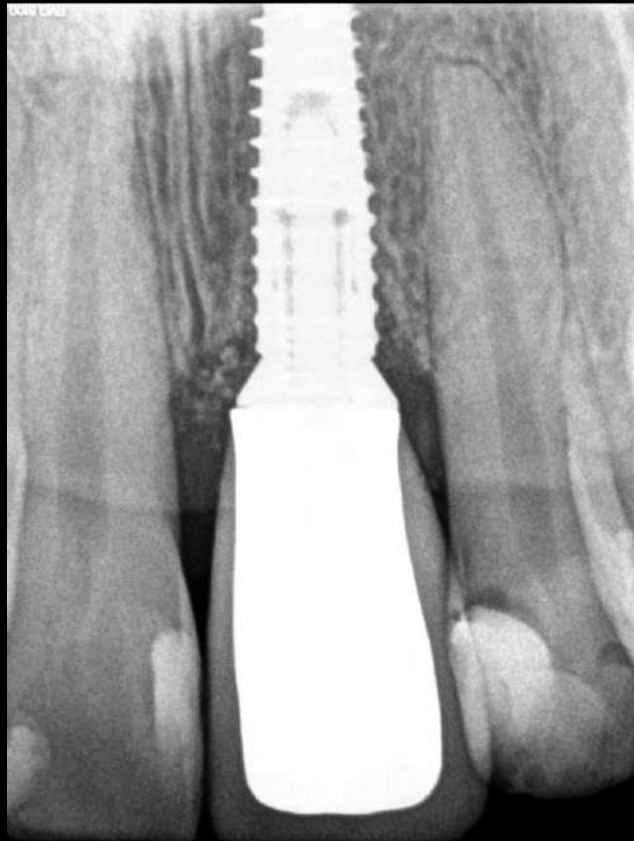
post-op
CBCT

Dr. João Gaspar

Dr. João Gaspar



www.medbone.eu

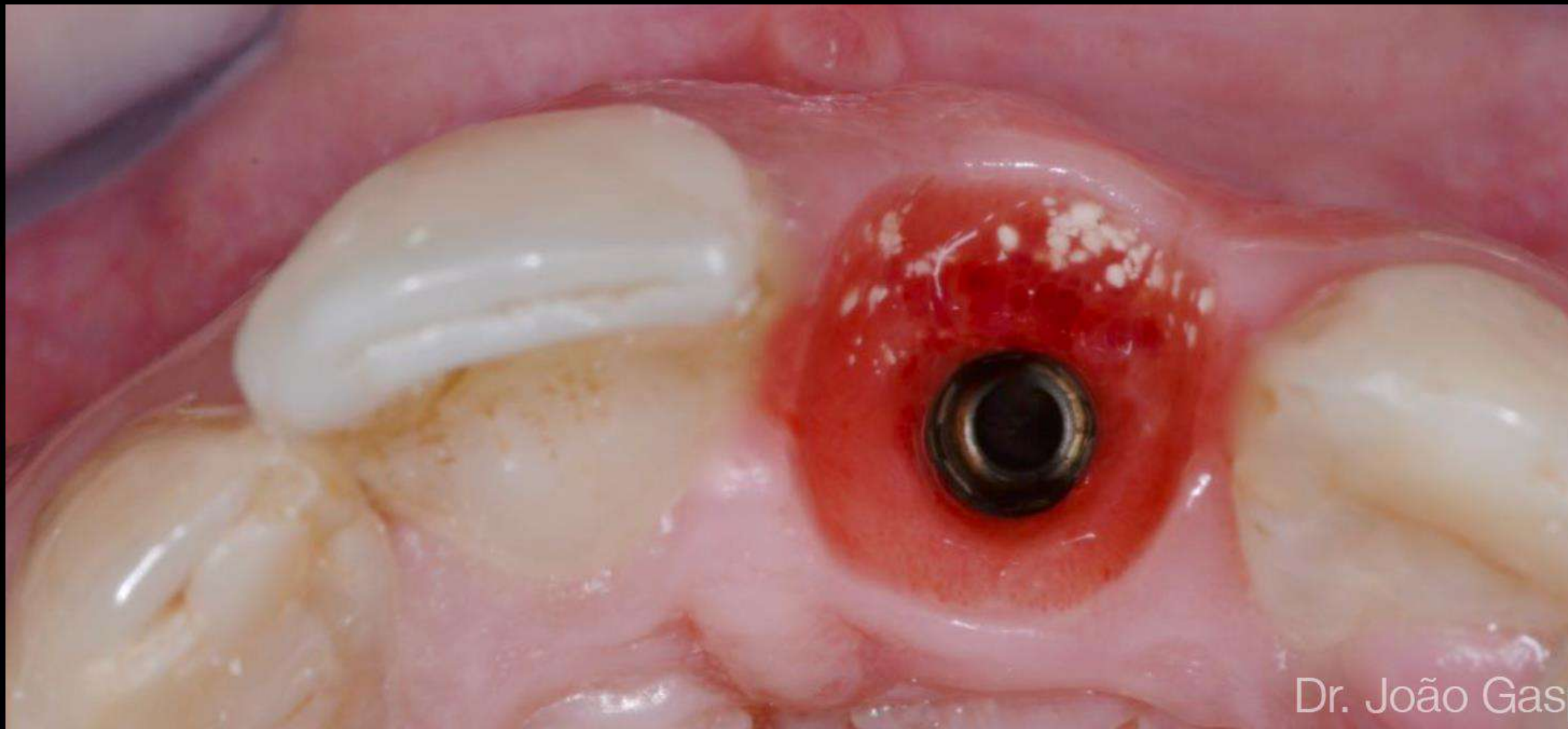


6 meses pós-op

Dr. João Gaspar



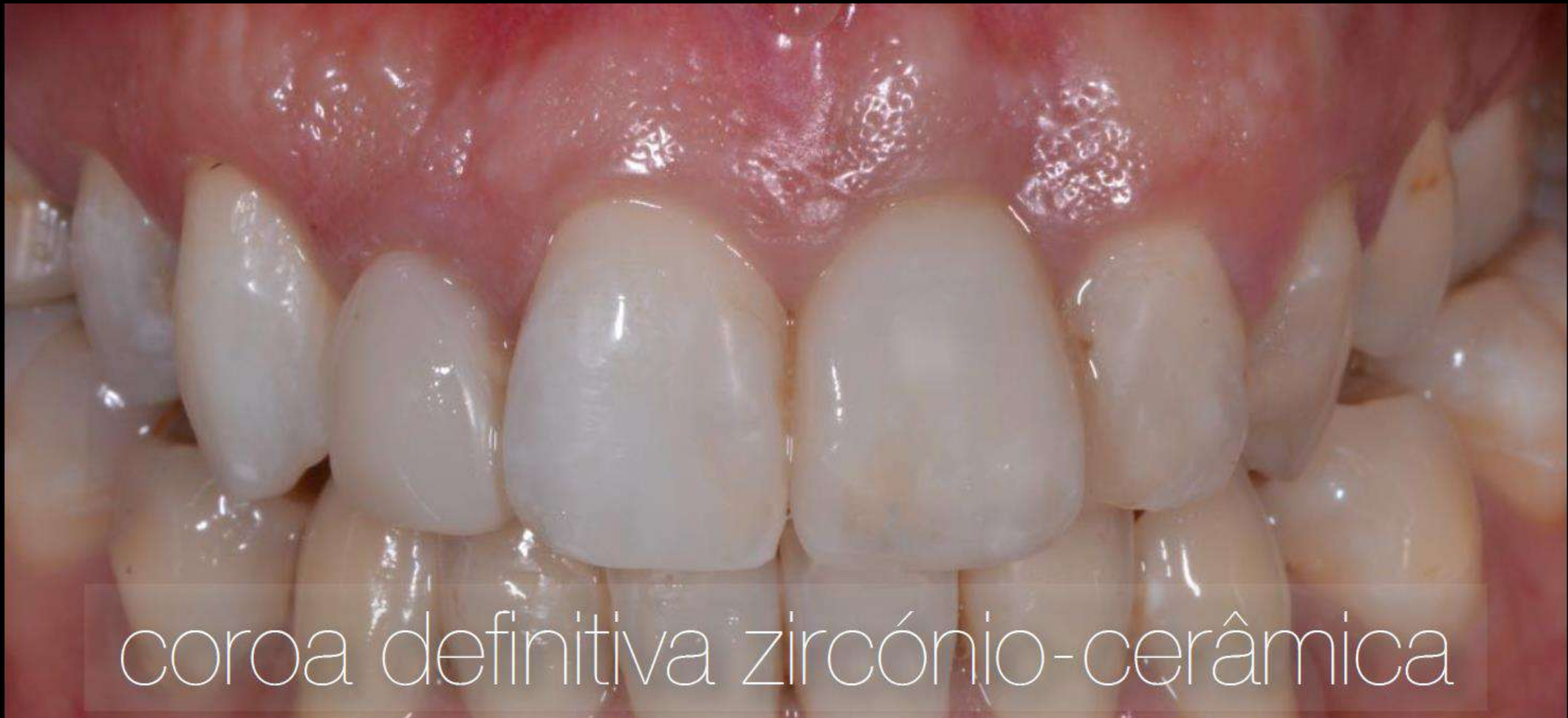www.medbone.eu



Dr. João Gaspar



www.medbone.eu



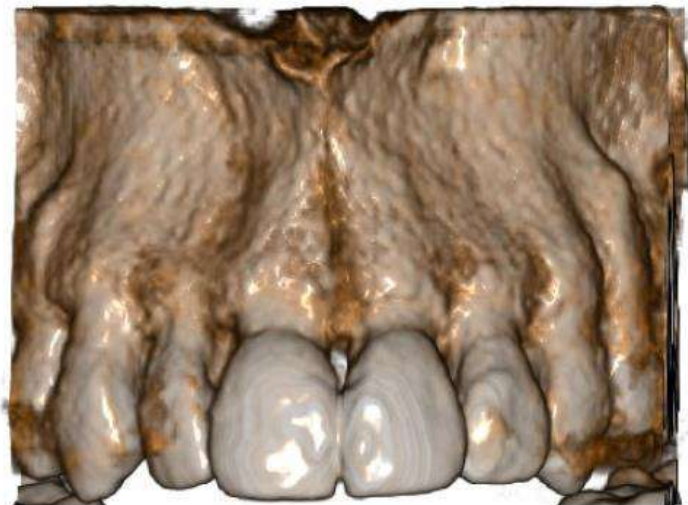coroa definitiva zircónio-cerâmica

Dr. João Gaspar



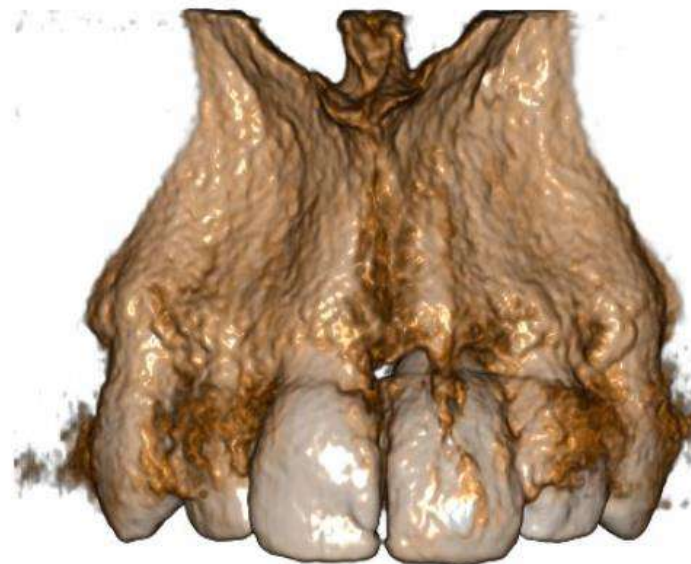
www.medbone.eu

D2

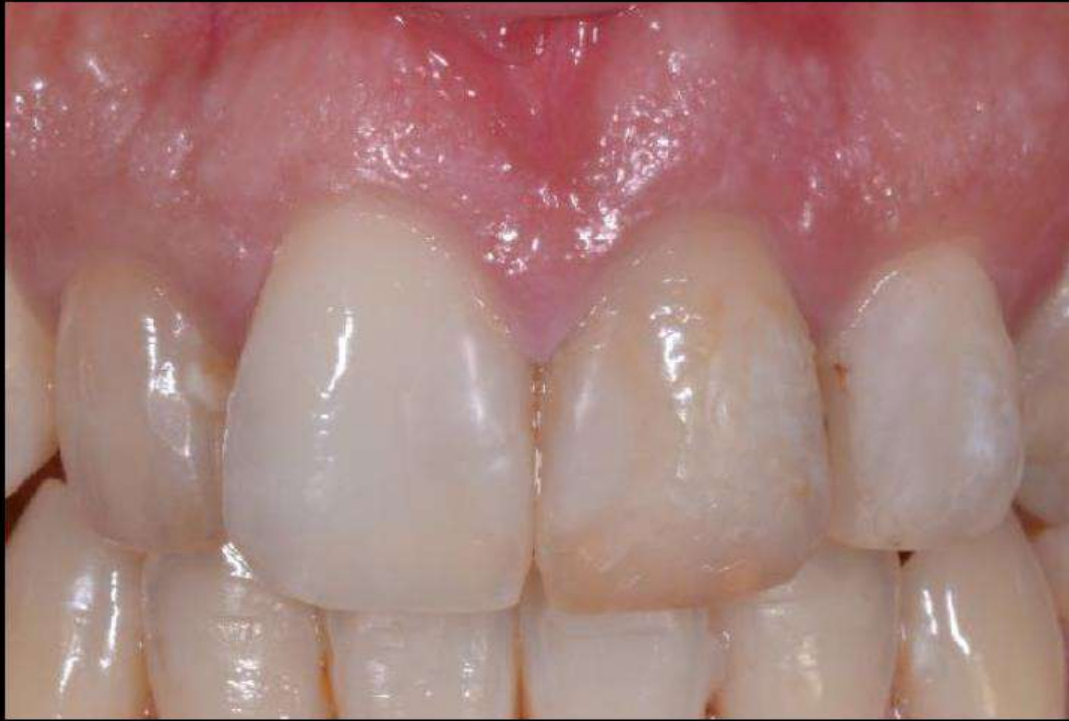

antes

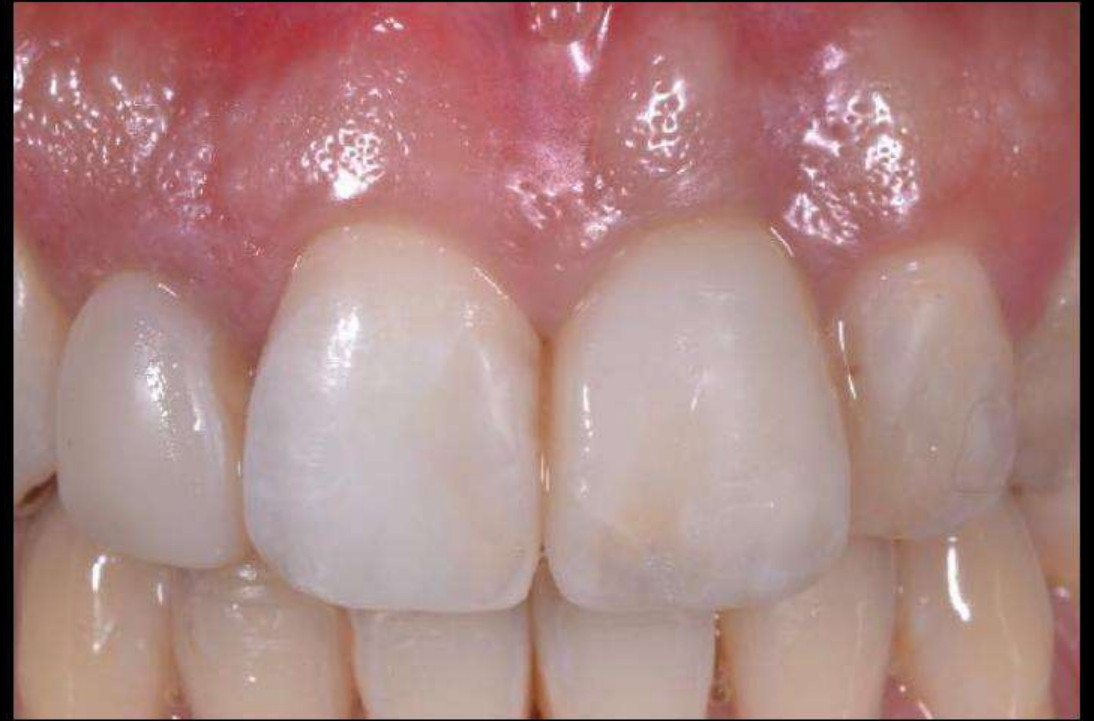
D1



1 ano e meio post-op



antes



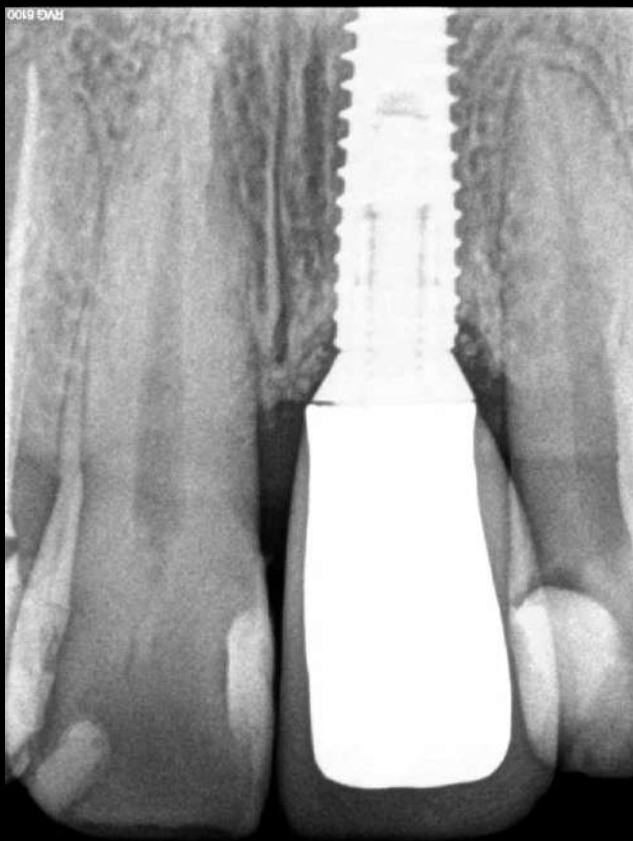
1 ano e meio

Dr. João Gaspar

Dr. João Gaspar



www.medbone.eu



2 anos pós-op

Dr. João Gaspar



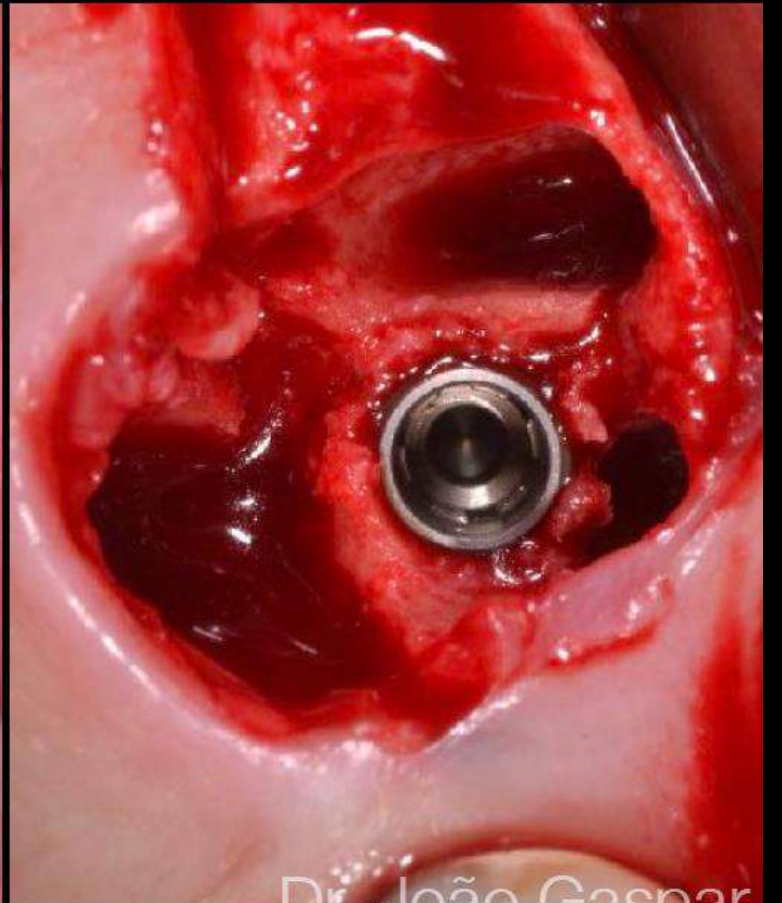
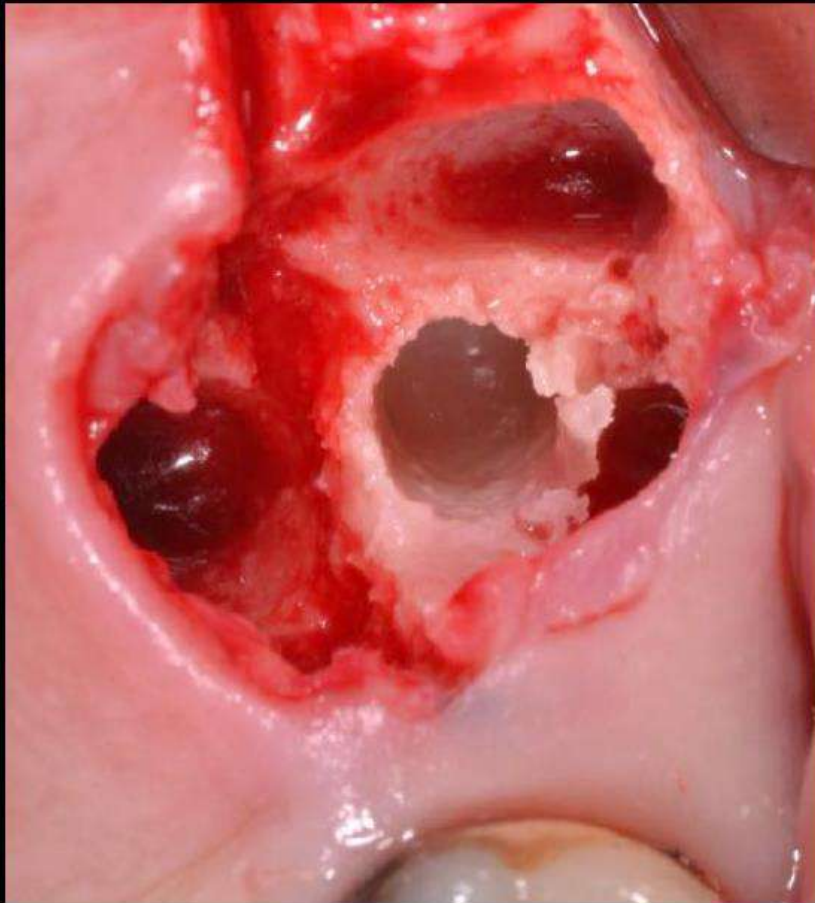
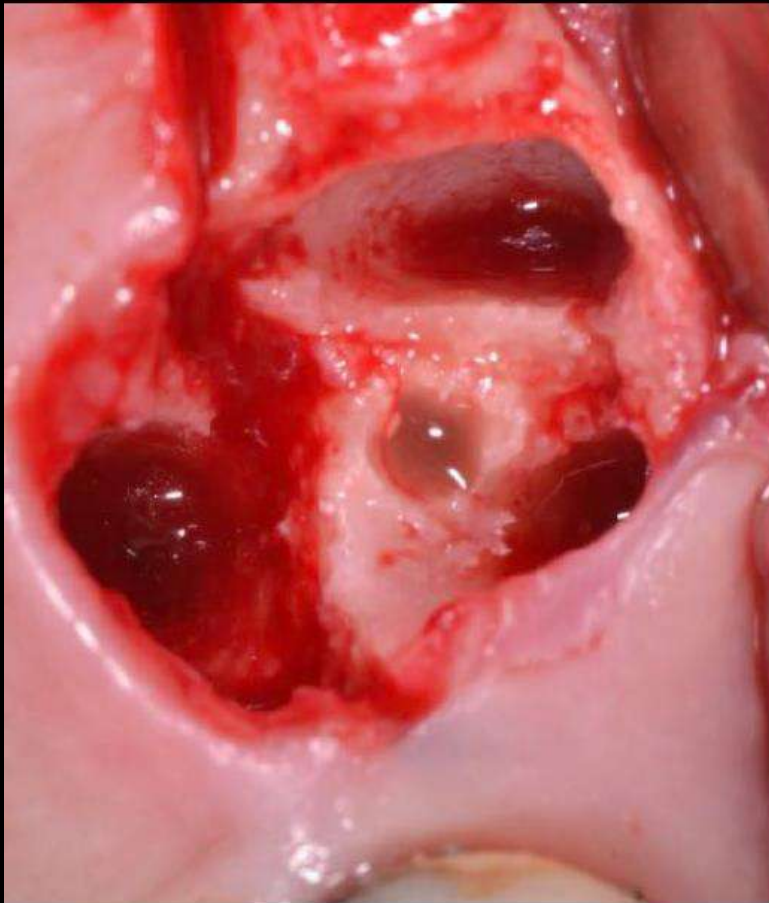
www.medbone.eu



Medbone®
BIOMATERIALS

CASE 3

adbone® TCP

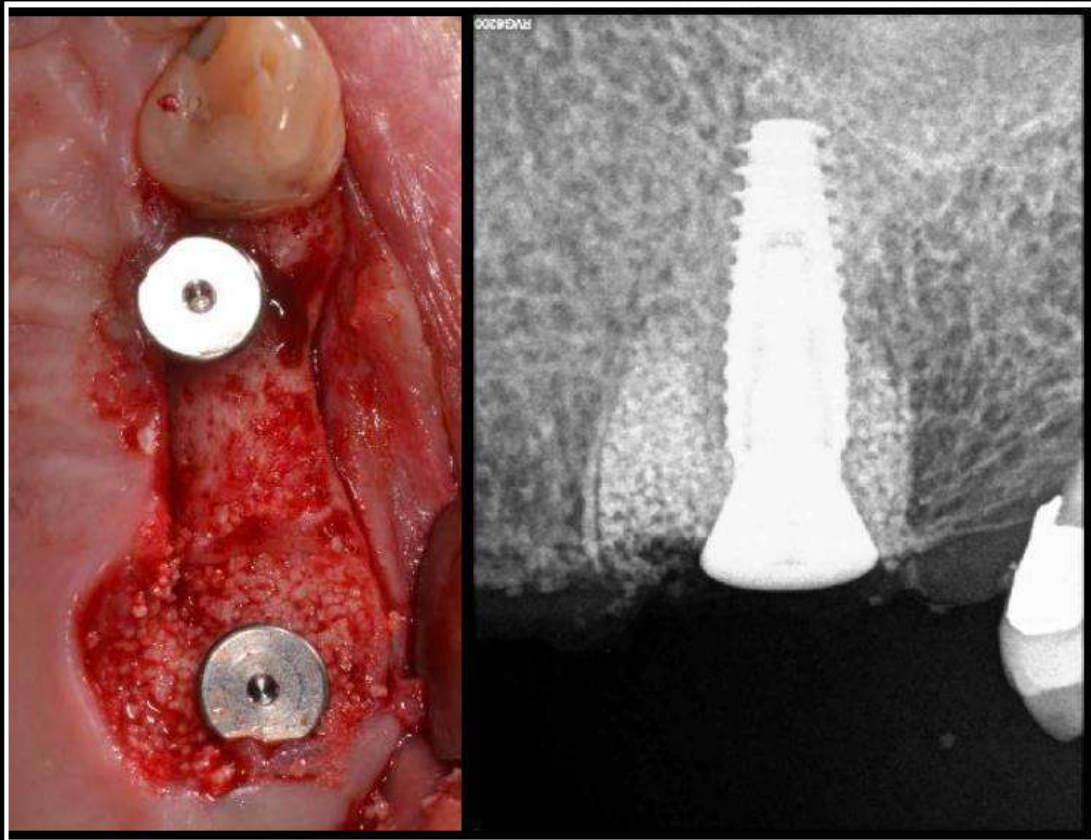


Dr. João Gaspar

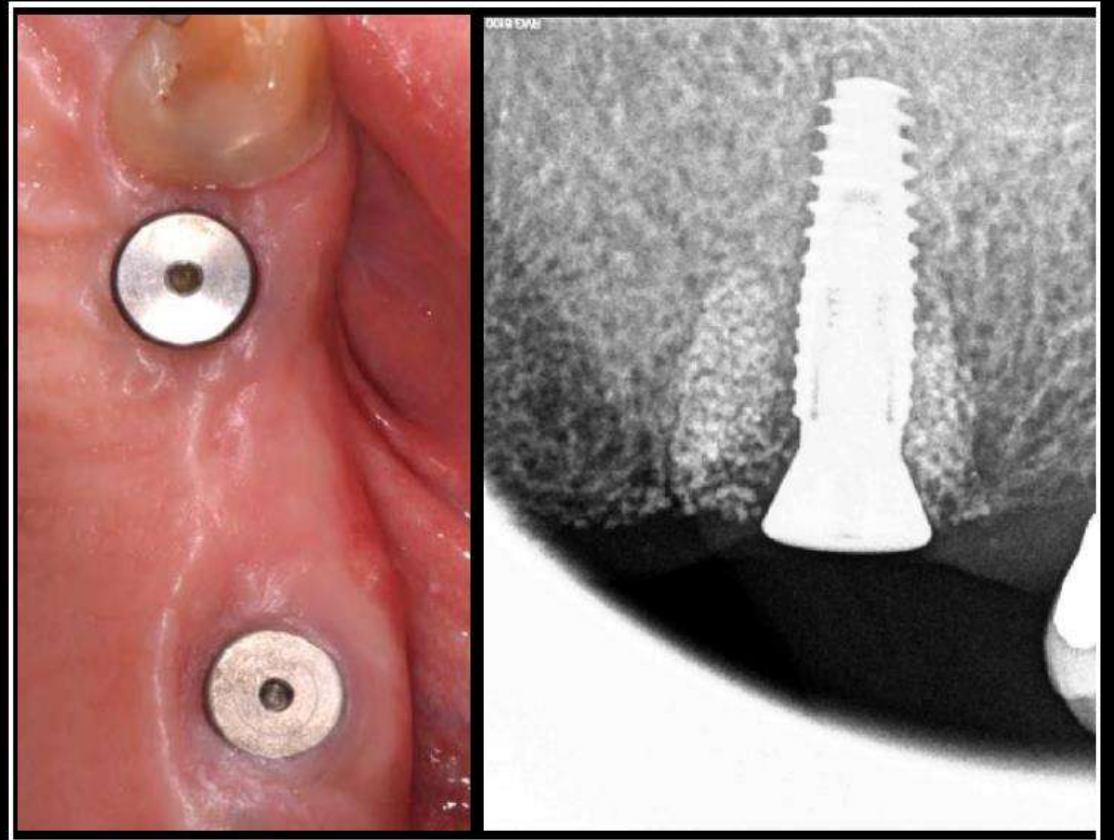
Dr. João Gaspar



www.medbone.eu



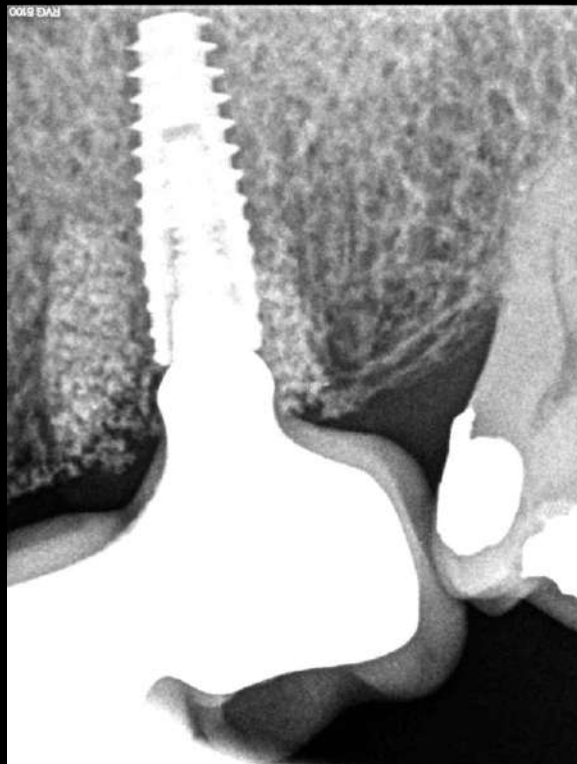pós-operatório imediato



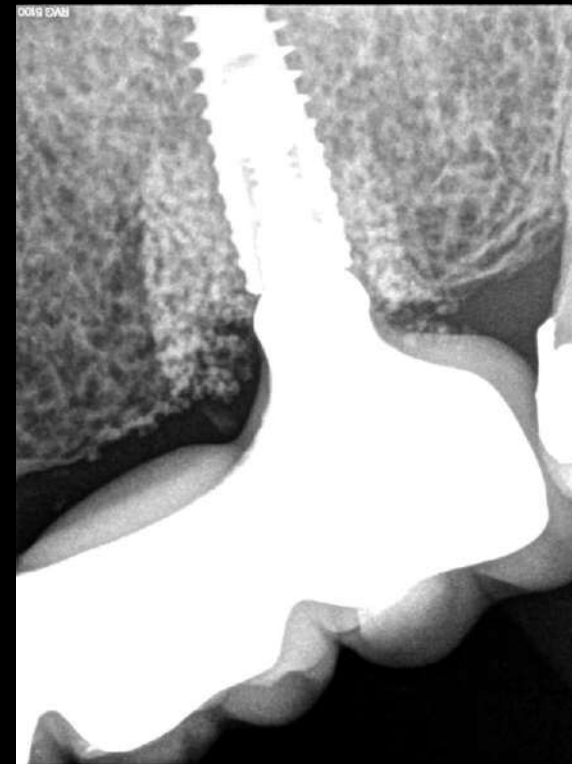3 meses

Dr. João Gaspar

6 meses pós-op



1,5 anos pós-op



Dr. João Gaspar



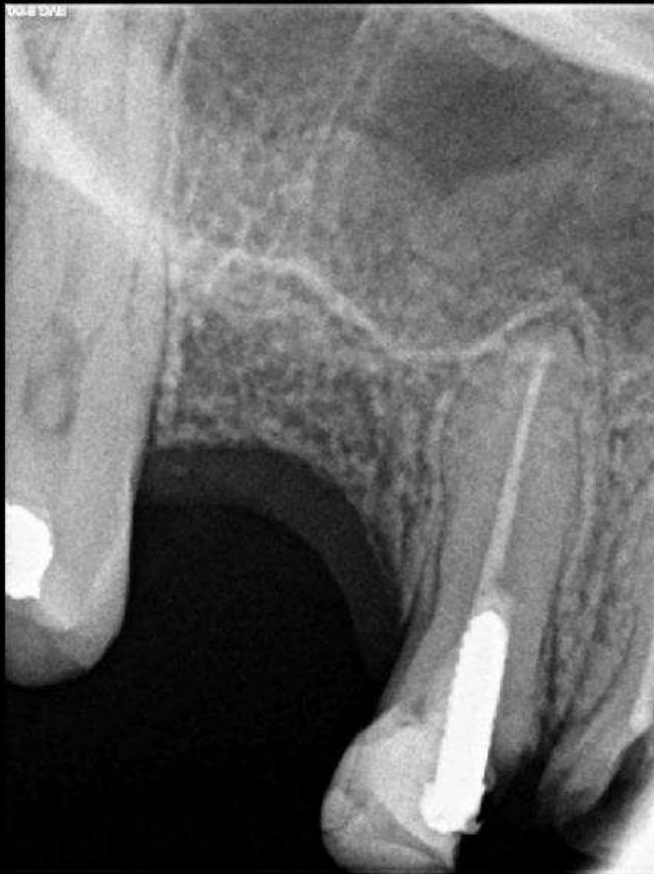www.medbone.eu



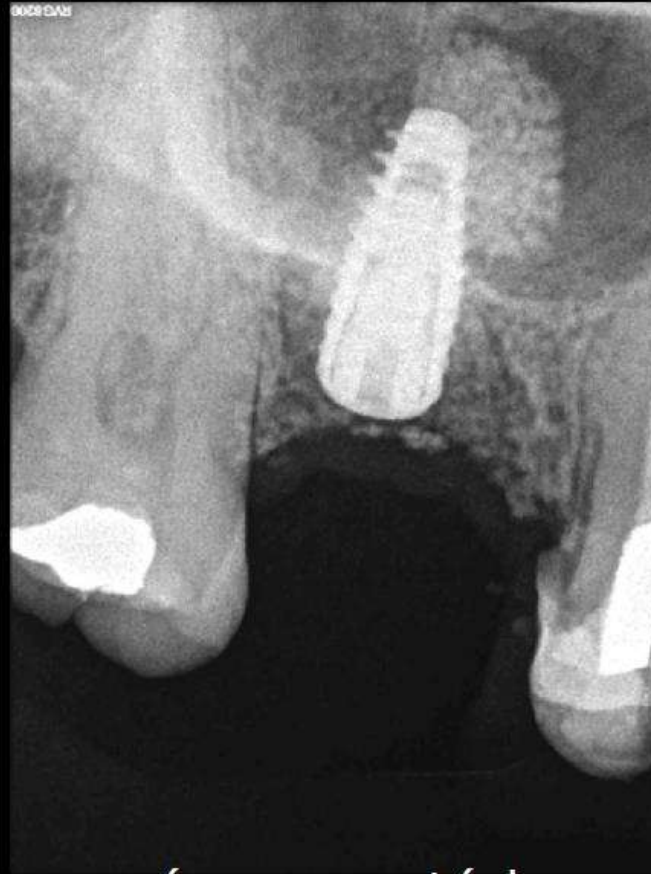Medbone®
BIOMATERIALS

CASE 4

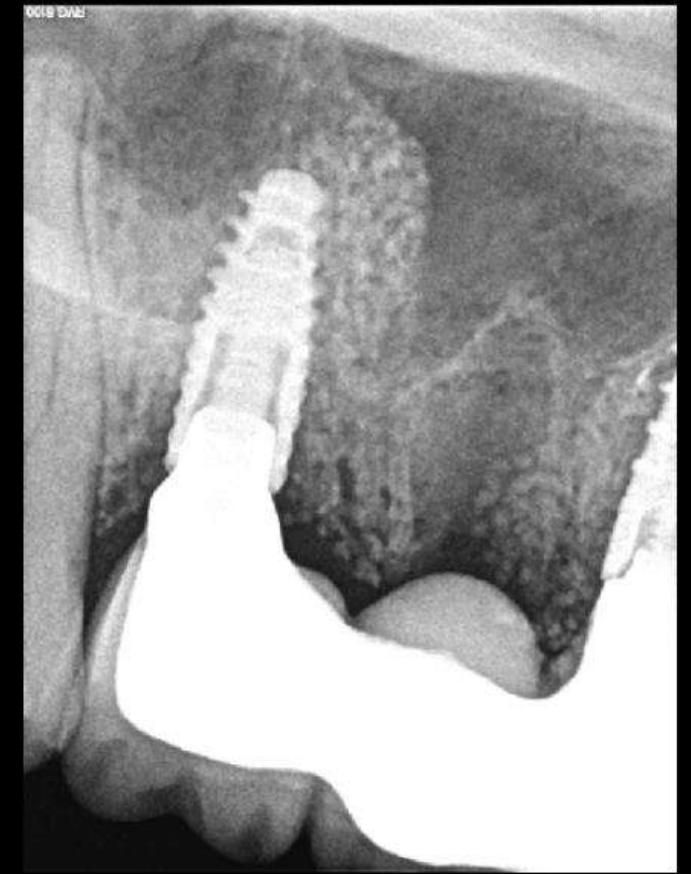
adbone® TCP



inicial



pós-operatório
imediatos

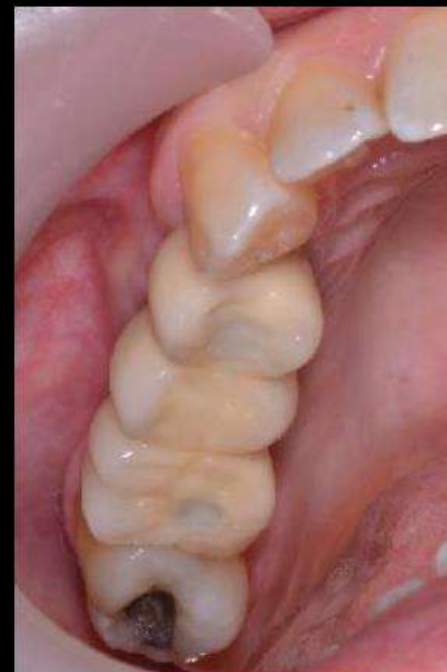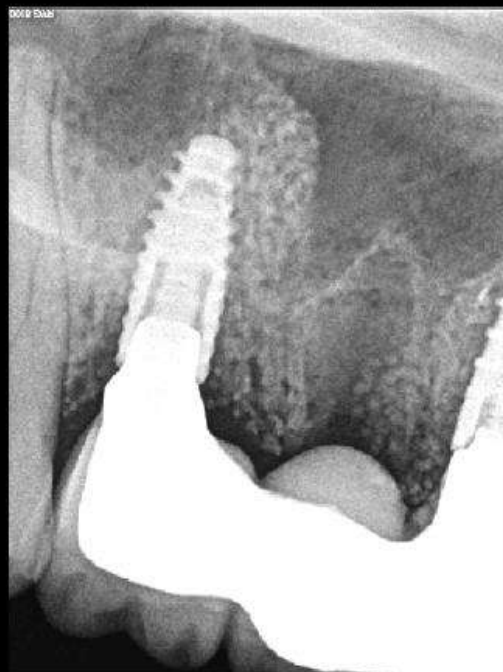

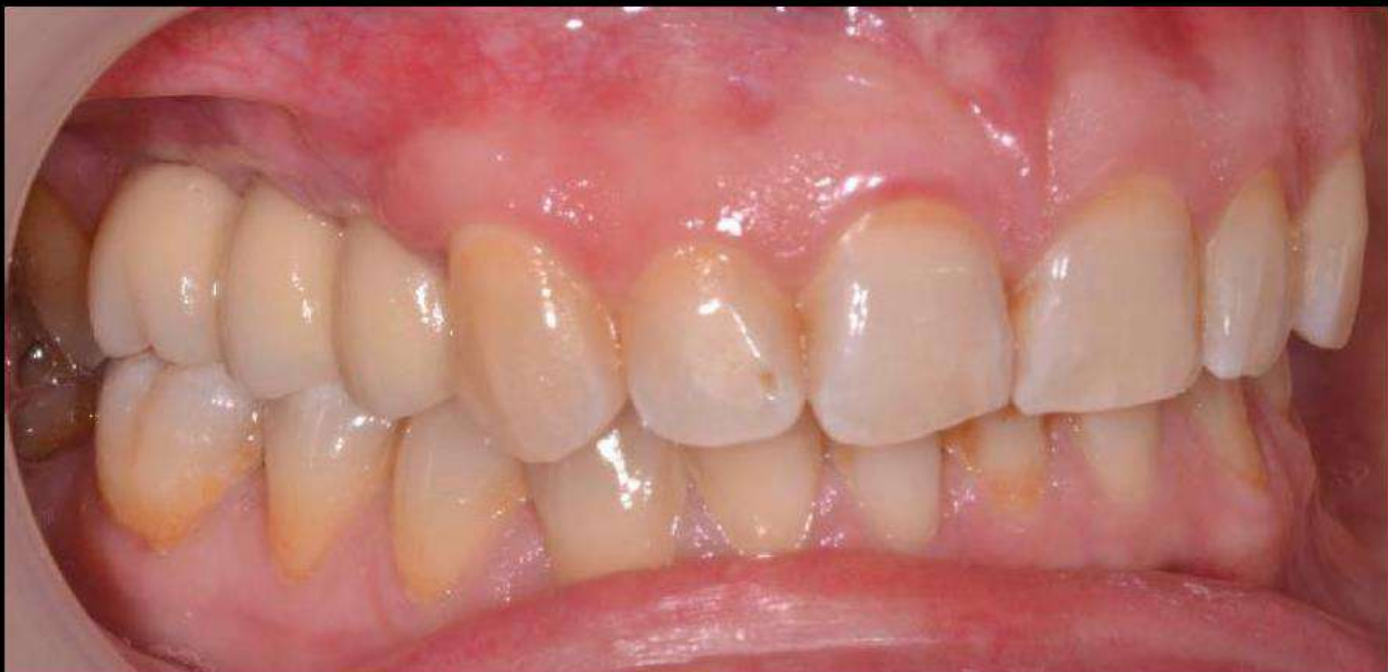
6 meses

Dr. João Gaspar



www.medbone.eu



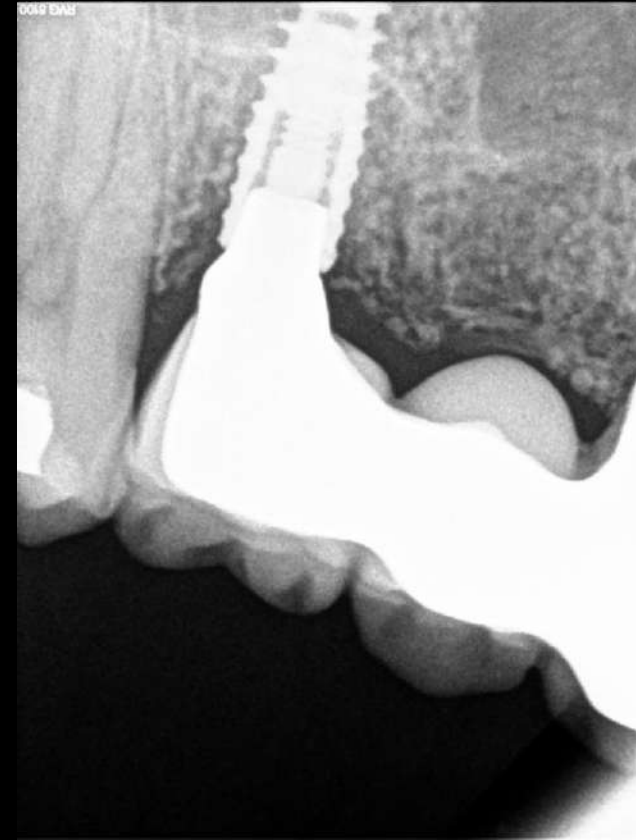Dr. João Gaspar

Dr. João Gaspar



www.medbone.eu

2 anos pós-op



Dr. João Gaspar



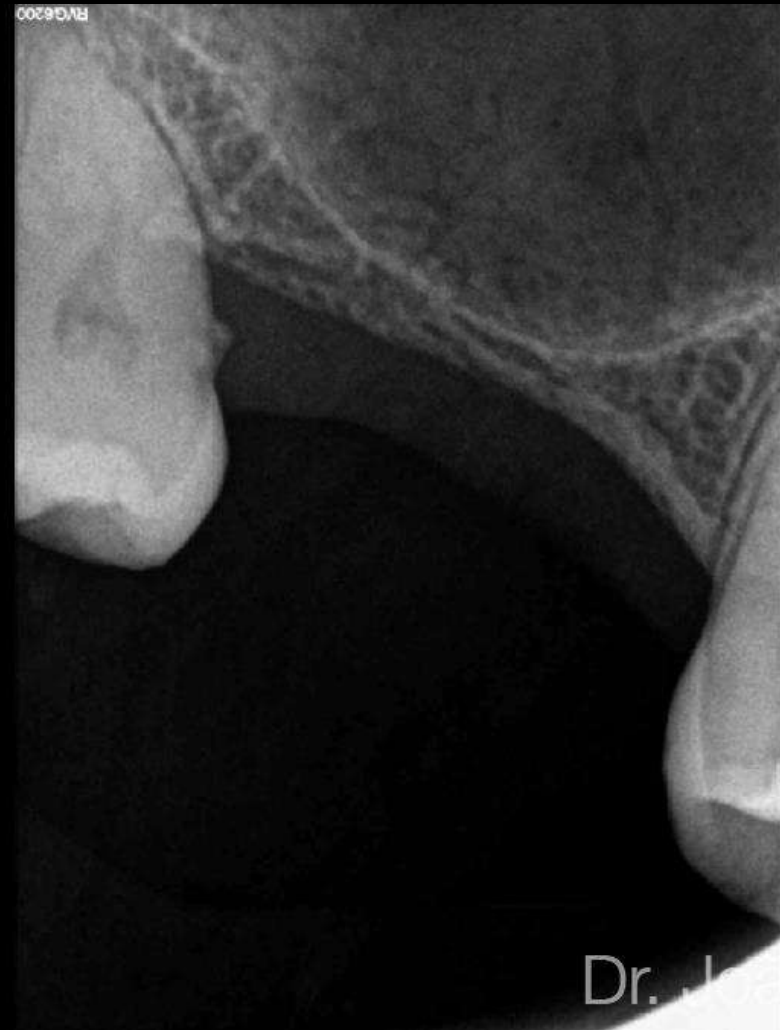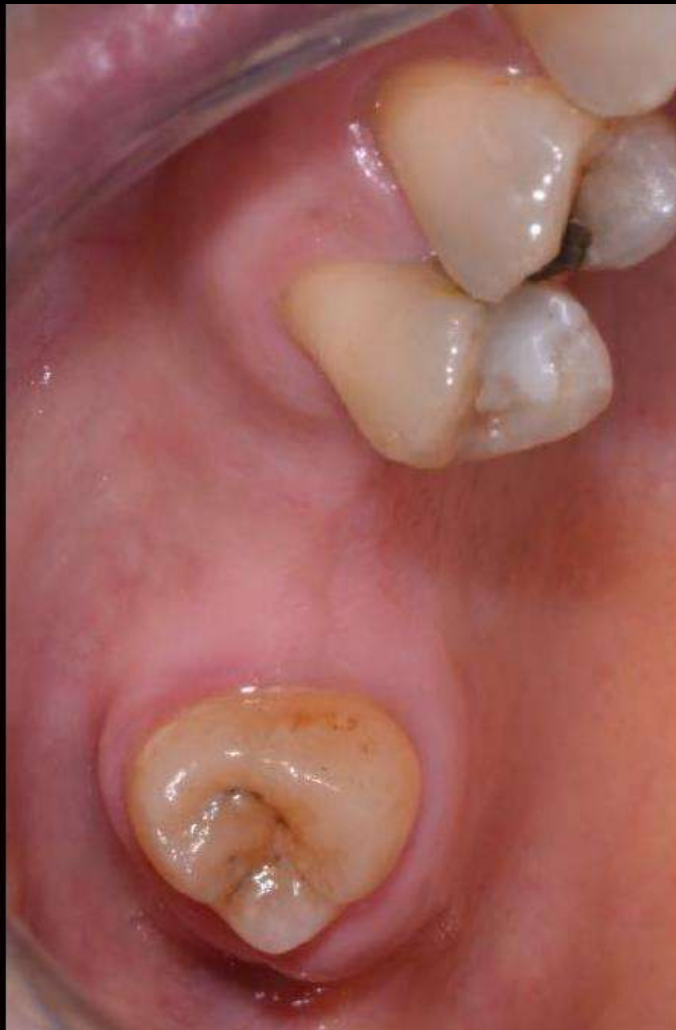www.medbone.eu



Medbone®
BIOMATERIALS

CASE 5

adbone® TCP

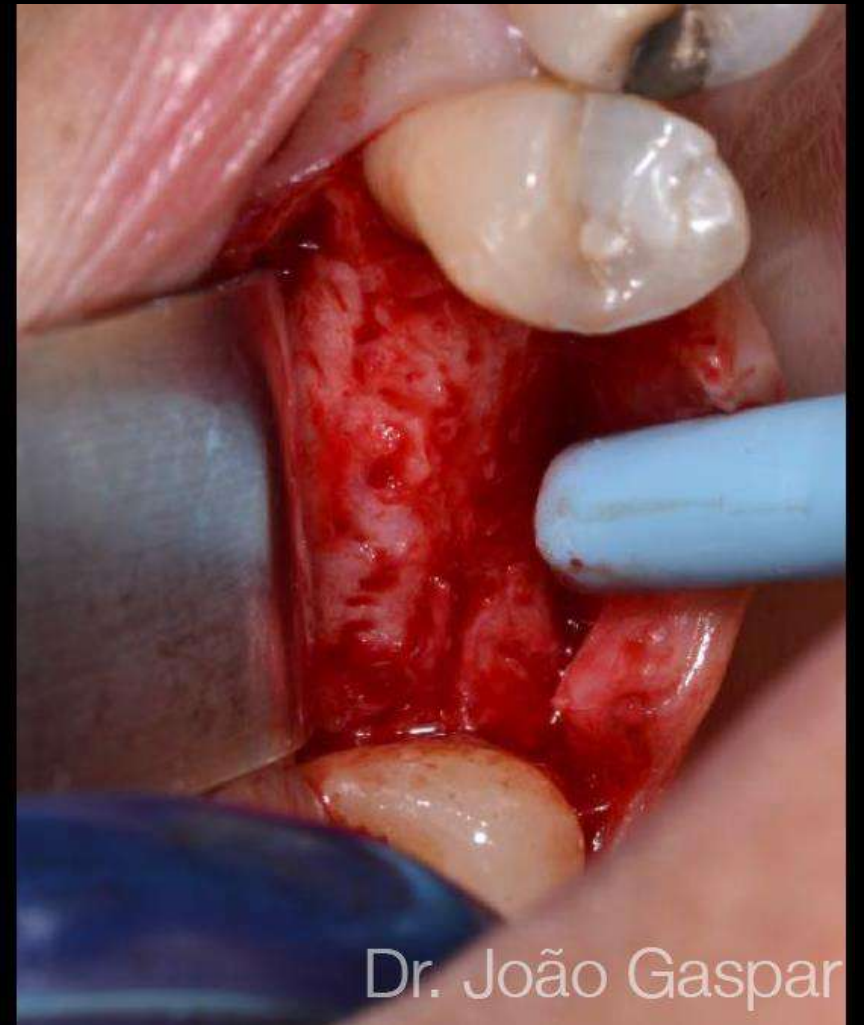
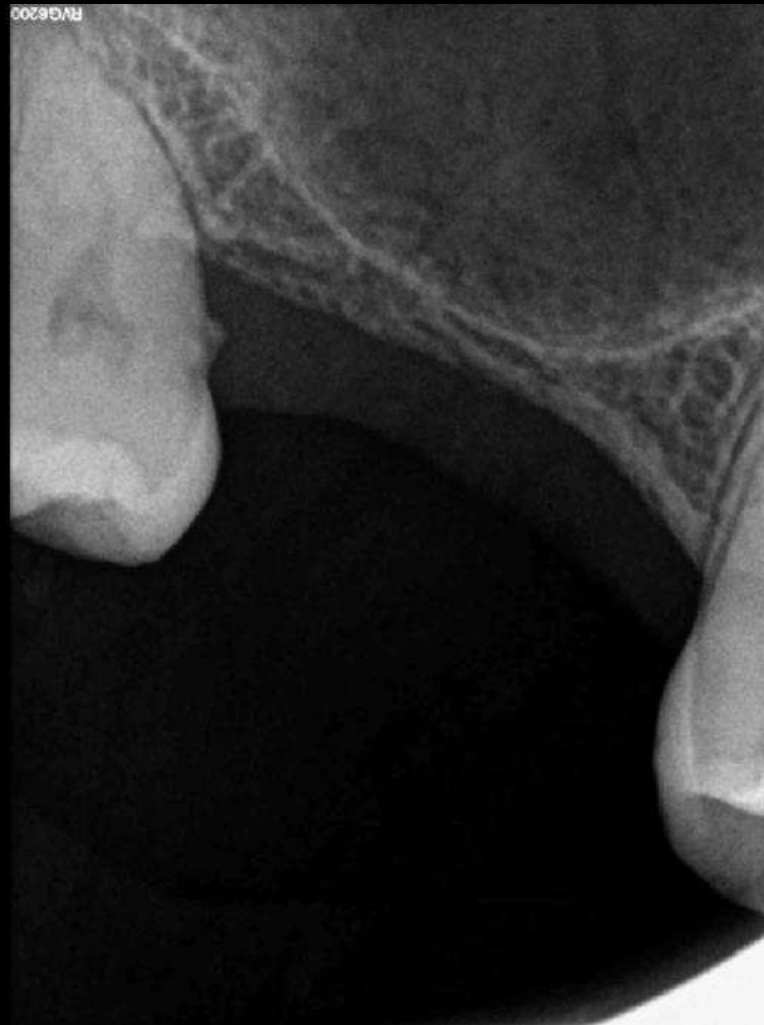
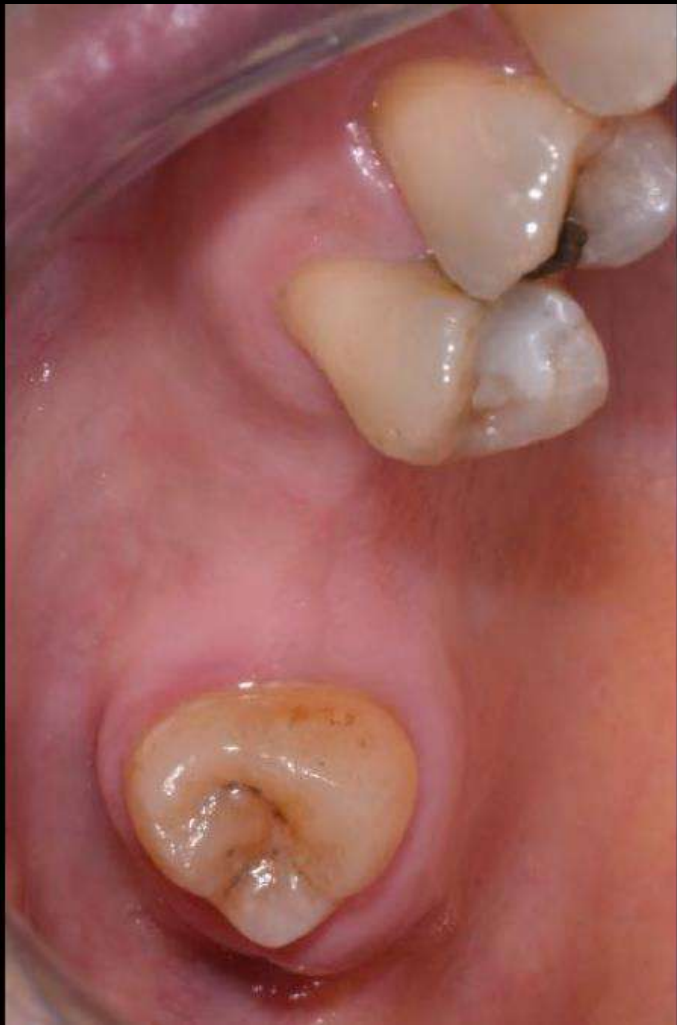Dr. João Gaspar

Dr. João Gaspar



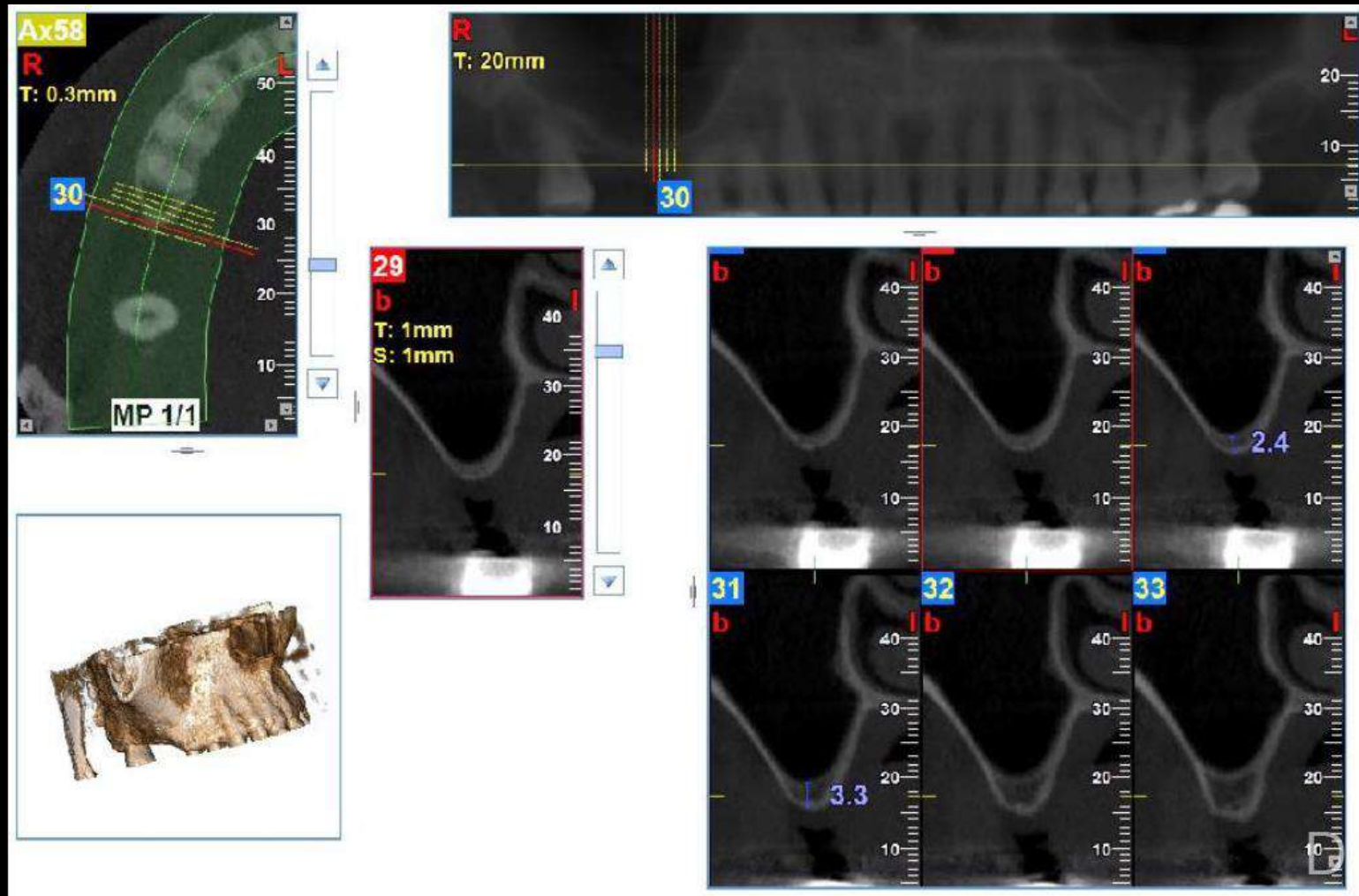
www.medbone.eu



Dr. João Gaspar



www.medbone.eu

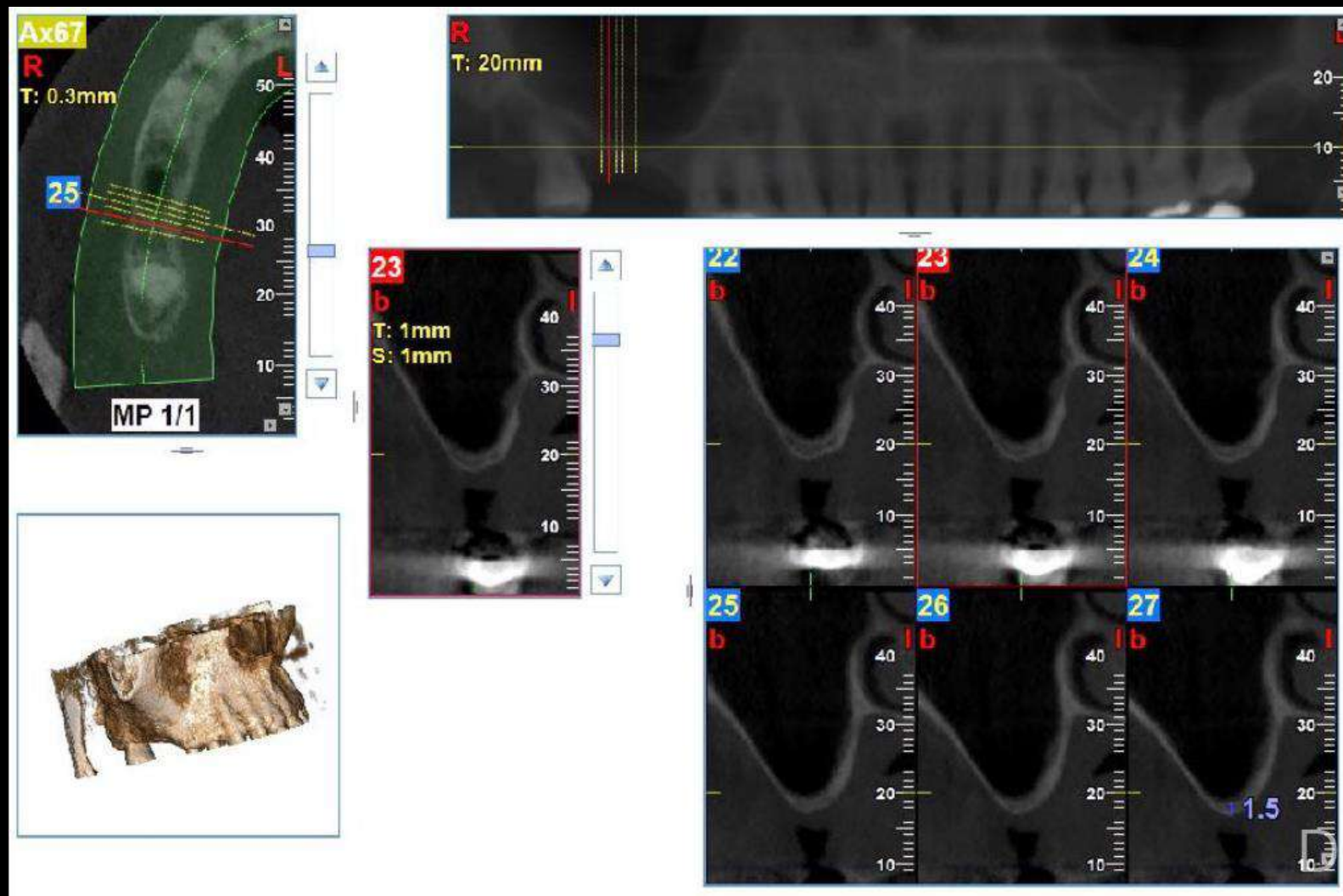


João Gaspar

Dr. João Gaspar



www.medbone.eu

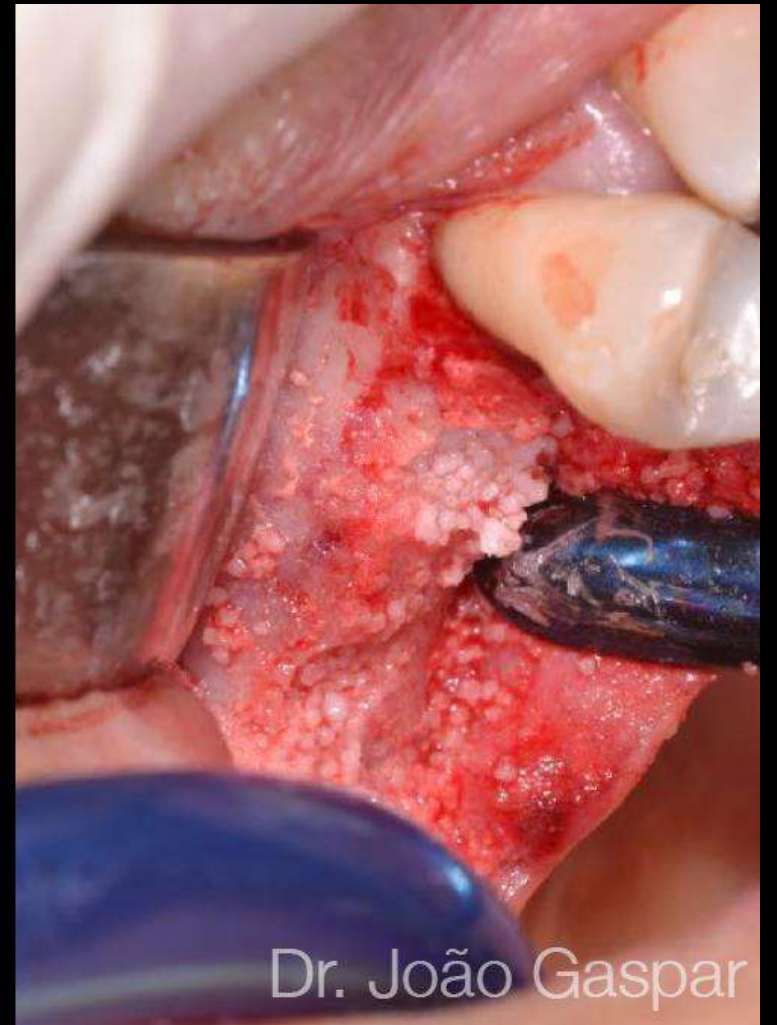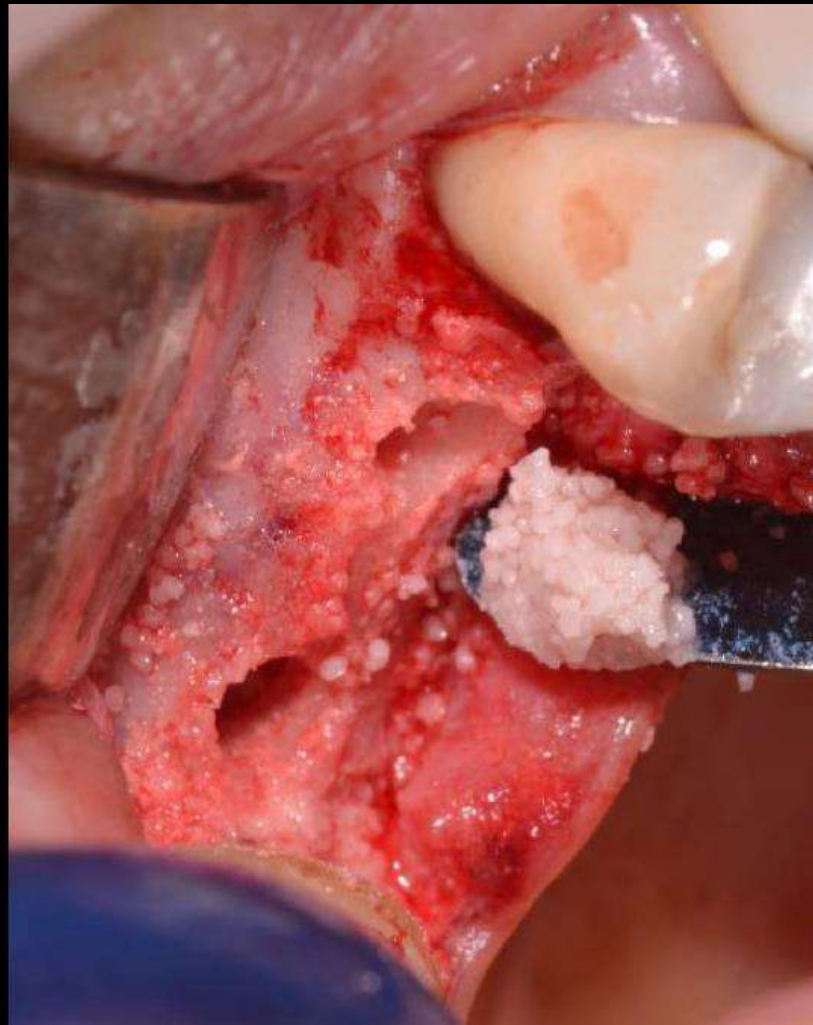
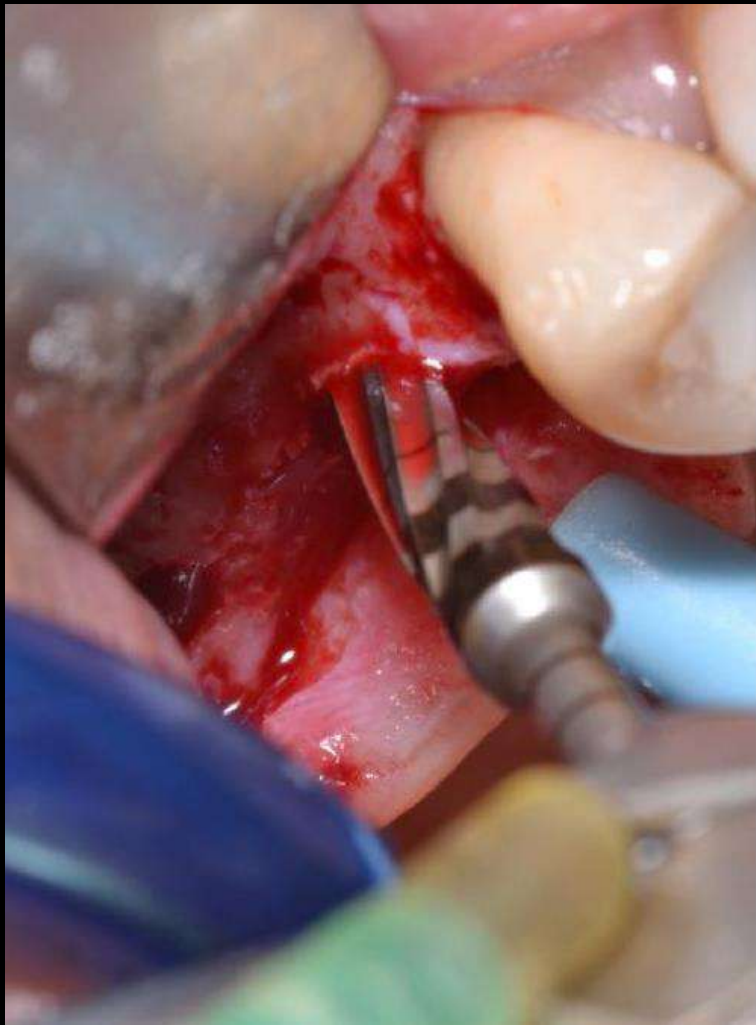


João Gaspar

Dr. João Gaspar



www.medbone.eu

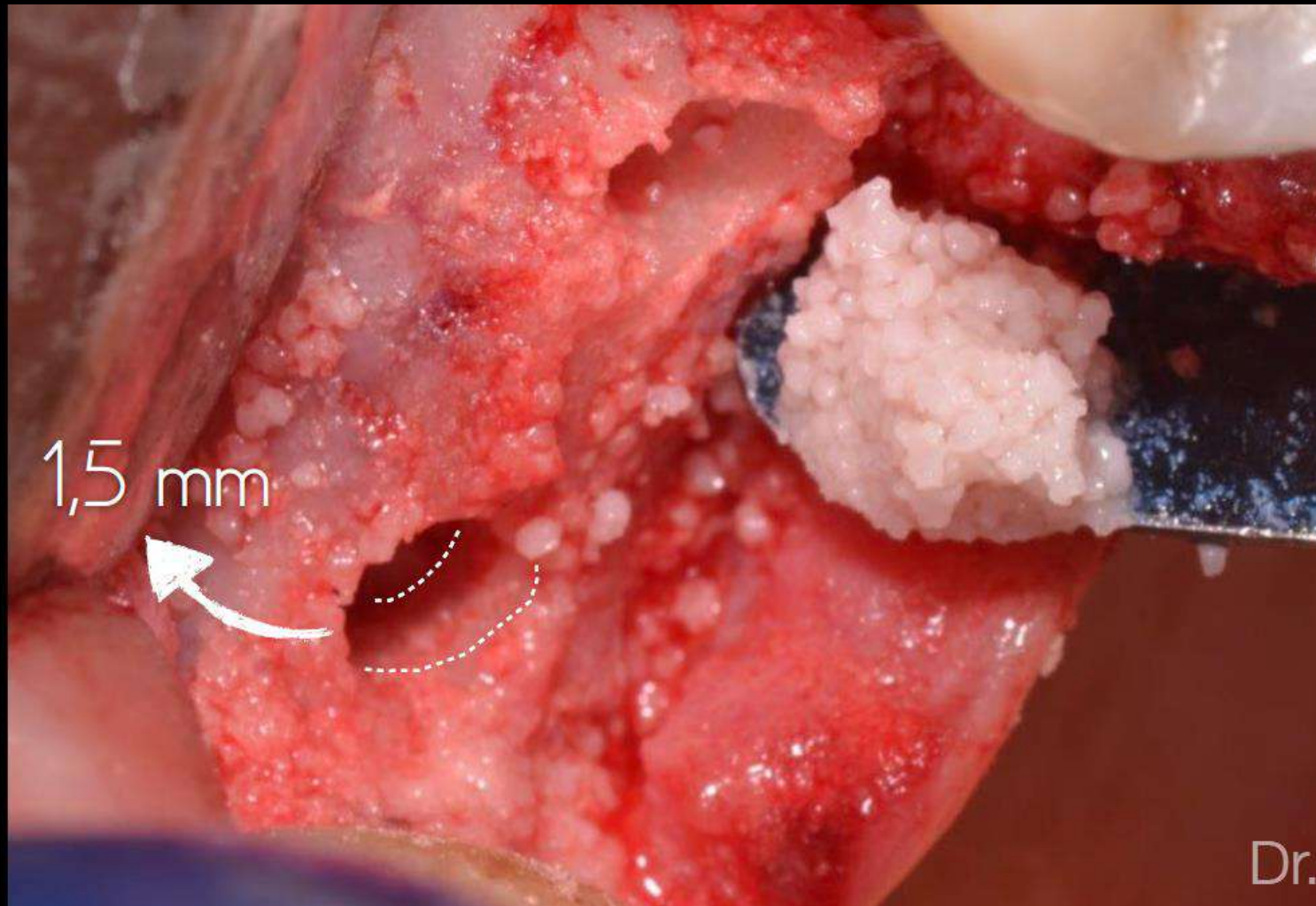


Dr. João Gaspar

Dr. João Gaspar



www.medbone.eu

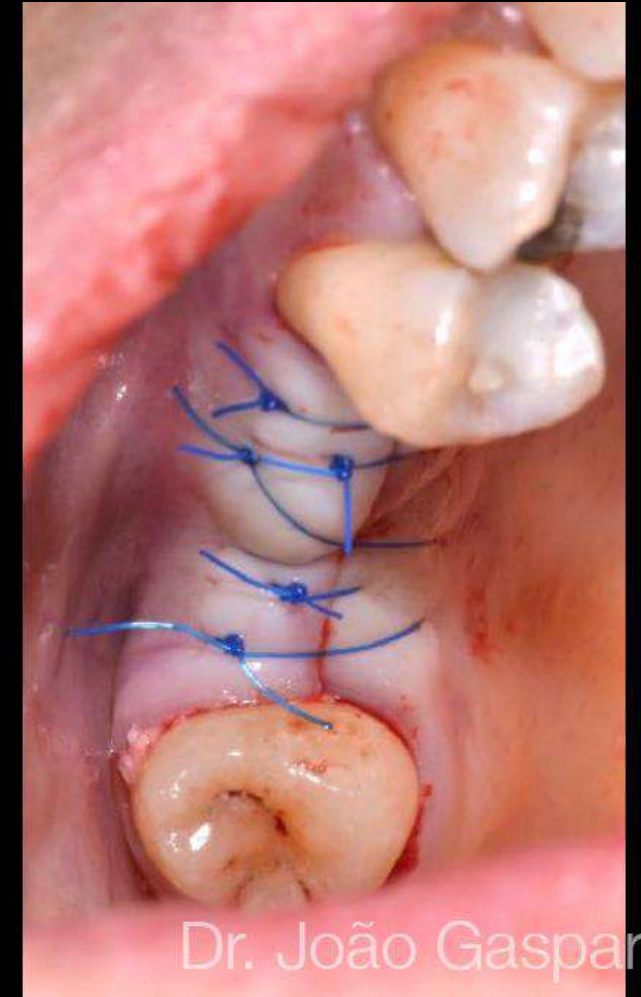
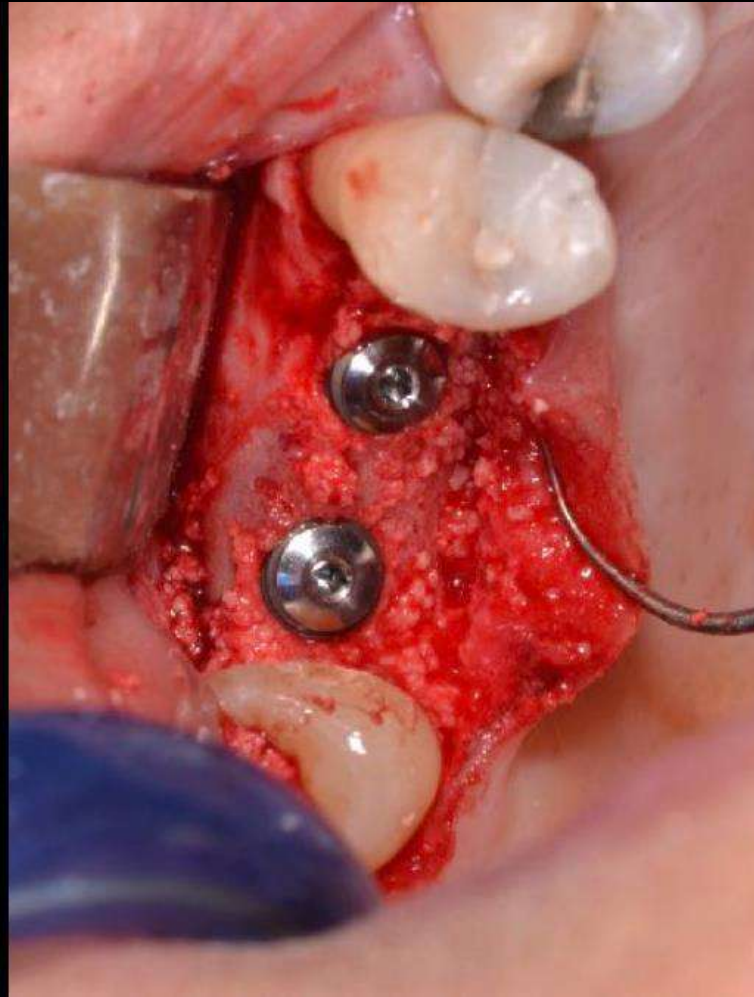
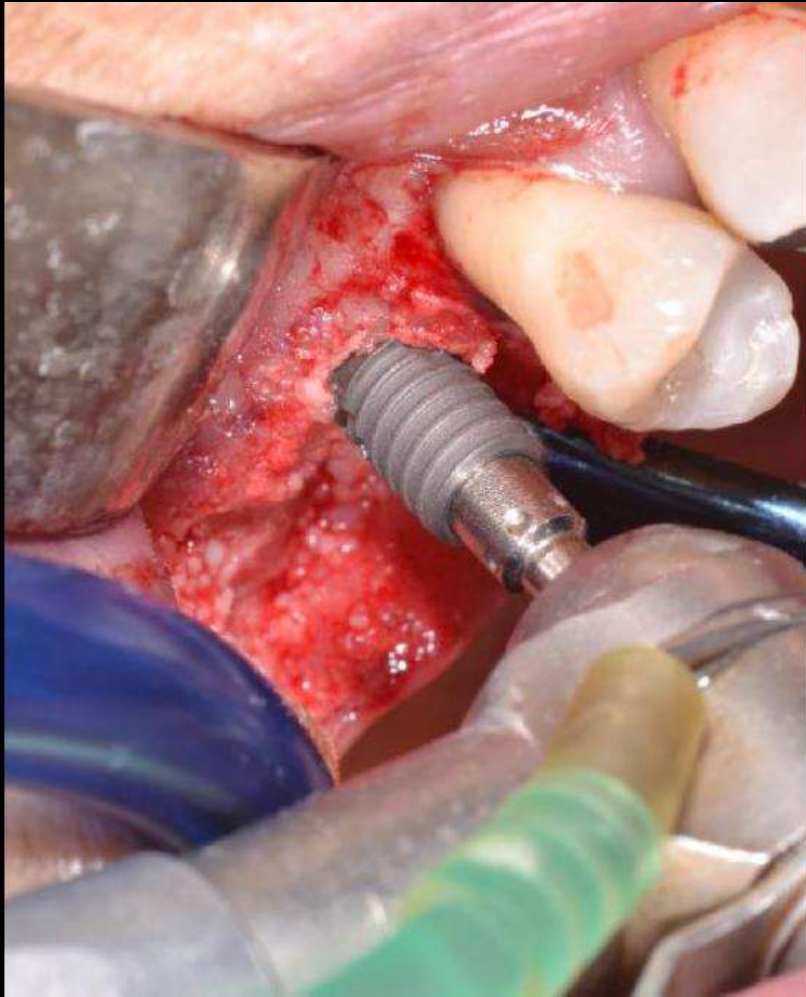


Dr. João Gaspar

Dr. João Gaspar



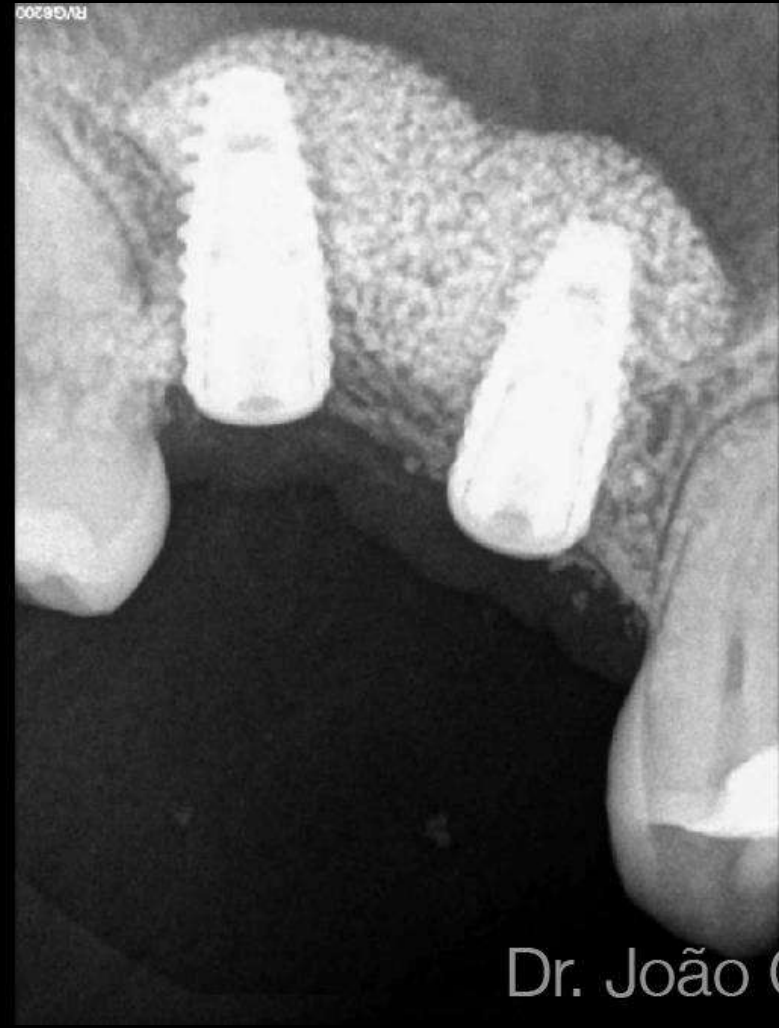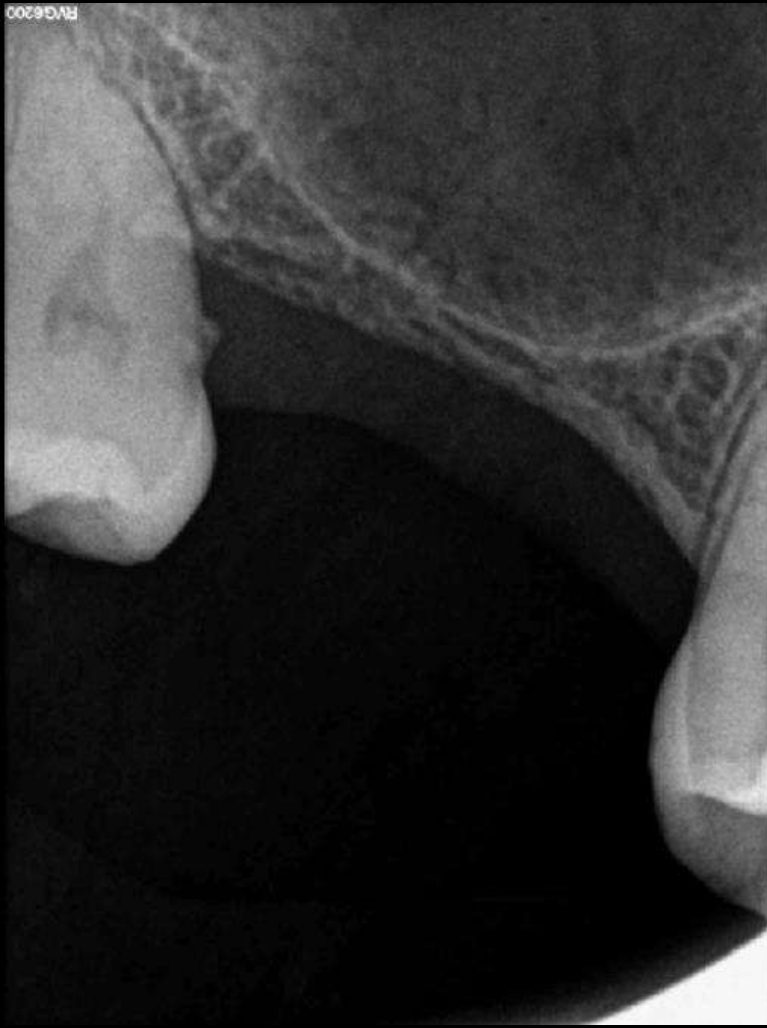www.medbone.eu



Dr. João Gaspar

Dr. João Gaspar





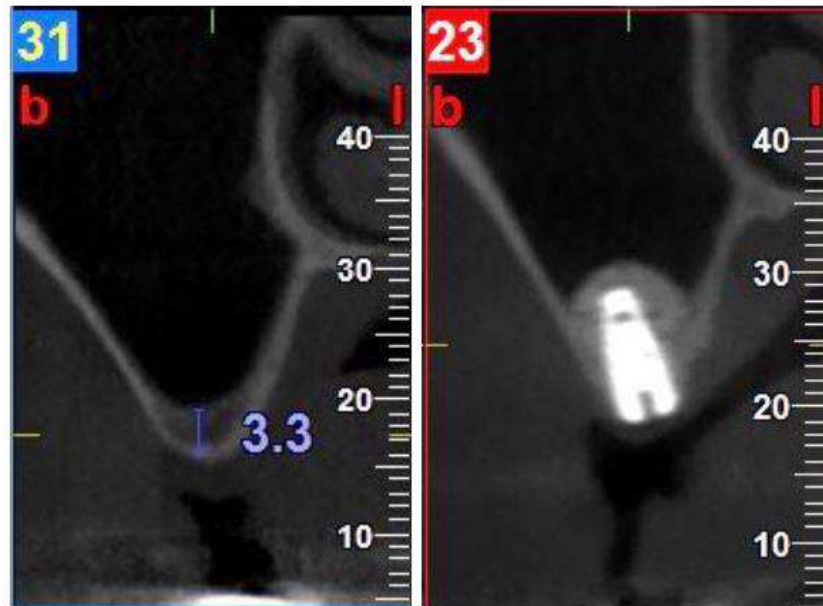
Dr. João Gaspar

Dr. João Gaspar



www.medbone.eu

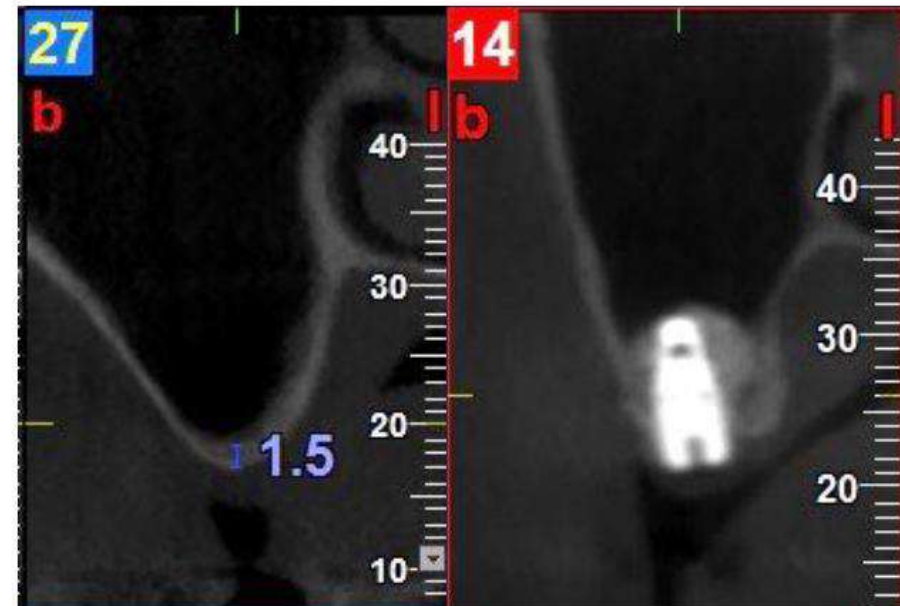
#15



Antes

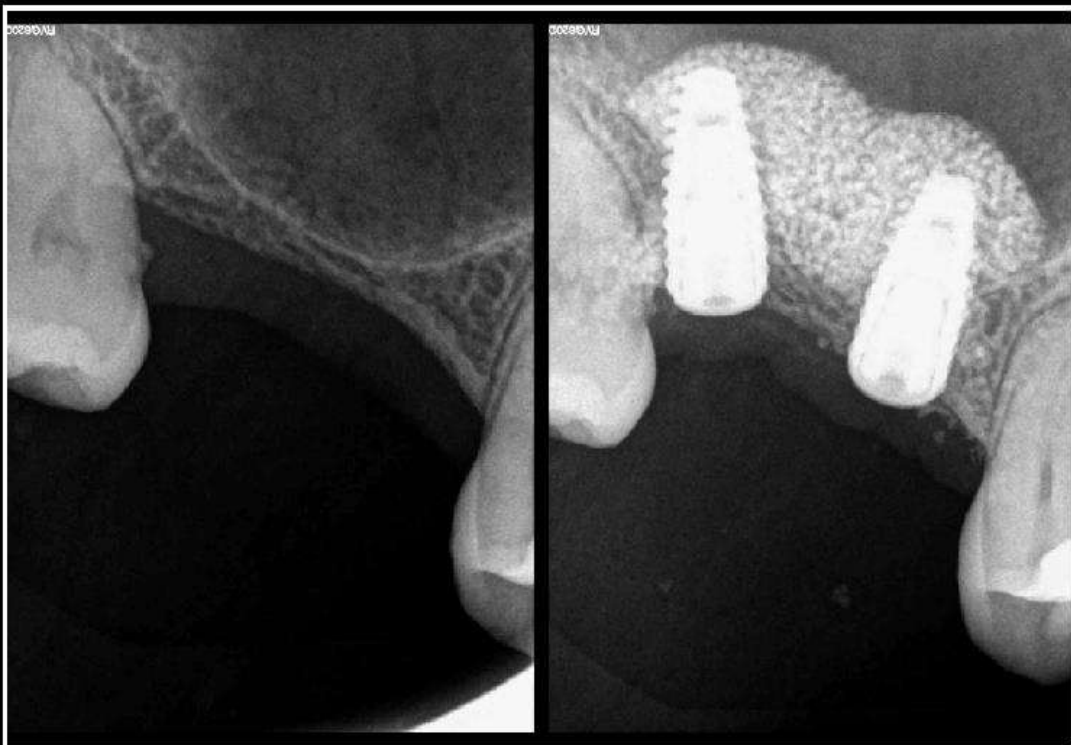
Depois

#16

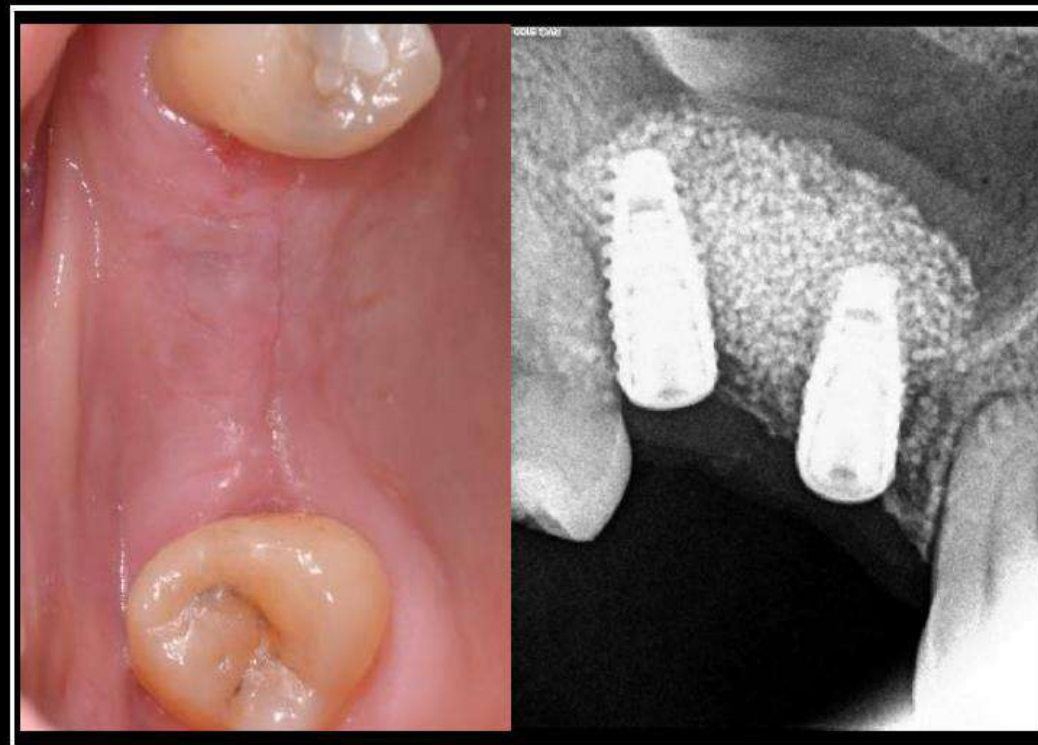


Antes

Depois



22 Junho 2018



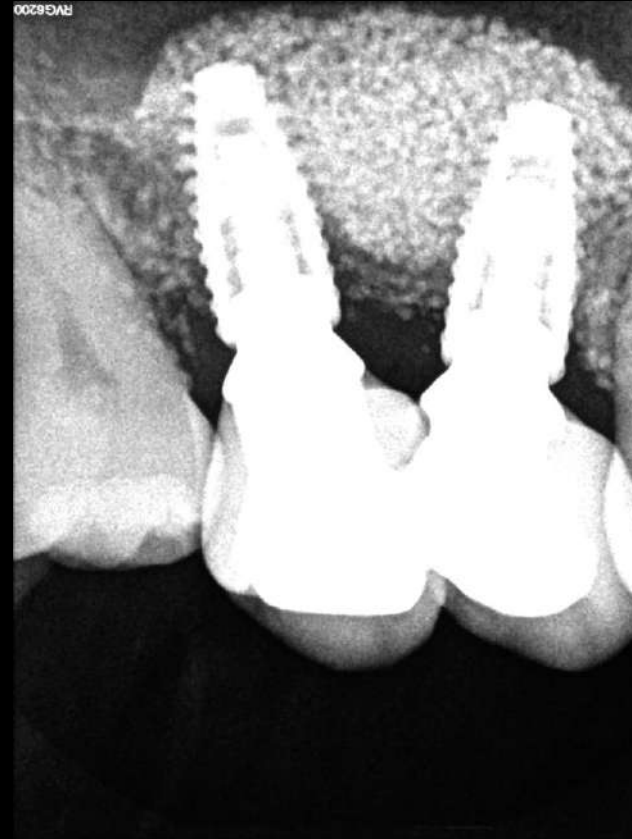20 Setembro 2018
Dr. João Gaspar

Dr. João Gaspar



www.medbone.eu

2 anos pós-op



Dr. João Gaspar



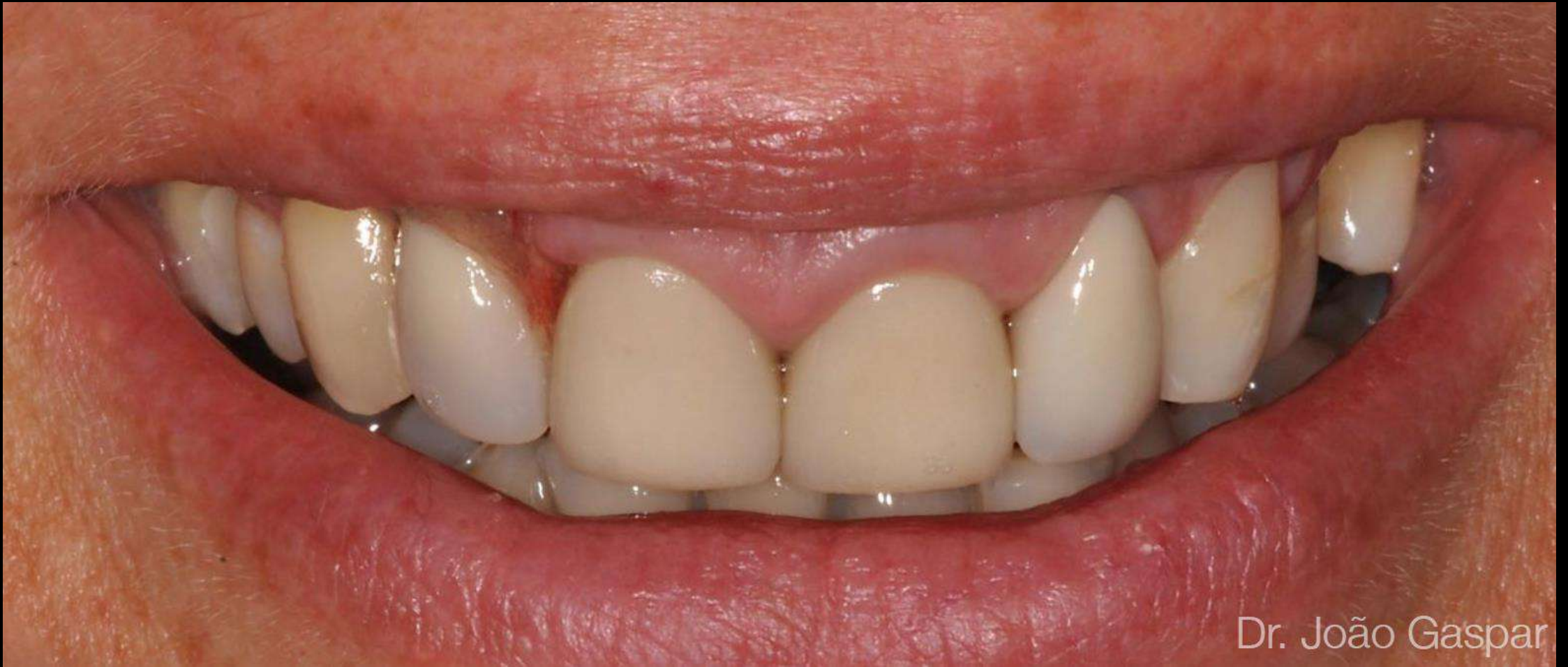www.medbone.eu



Medbone®
BIOMATERIALS

CASE 6

adbone® TCP

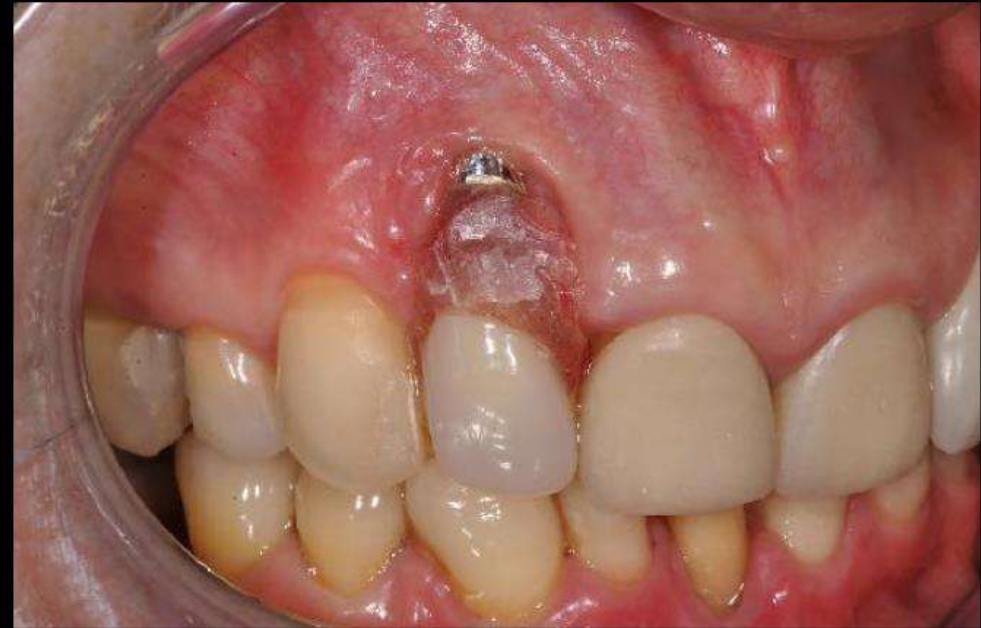
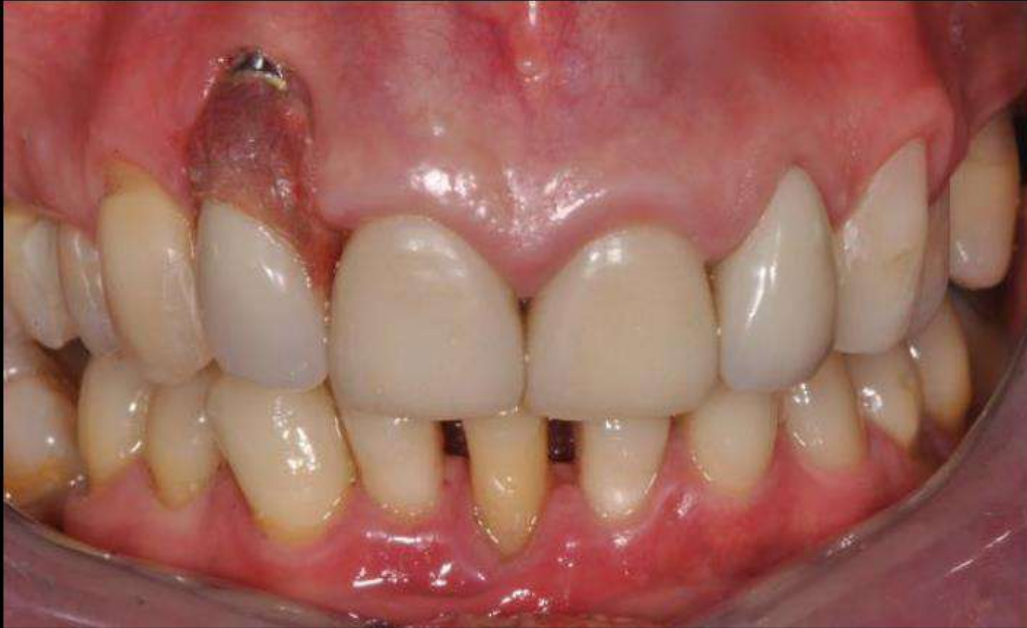
Dr. João Gaspar

Dr. João Gaspar



www.medbone.eu



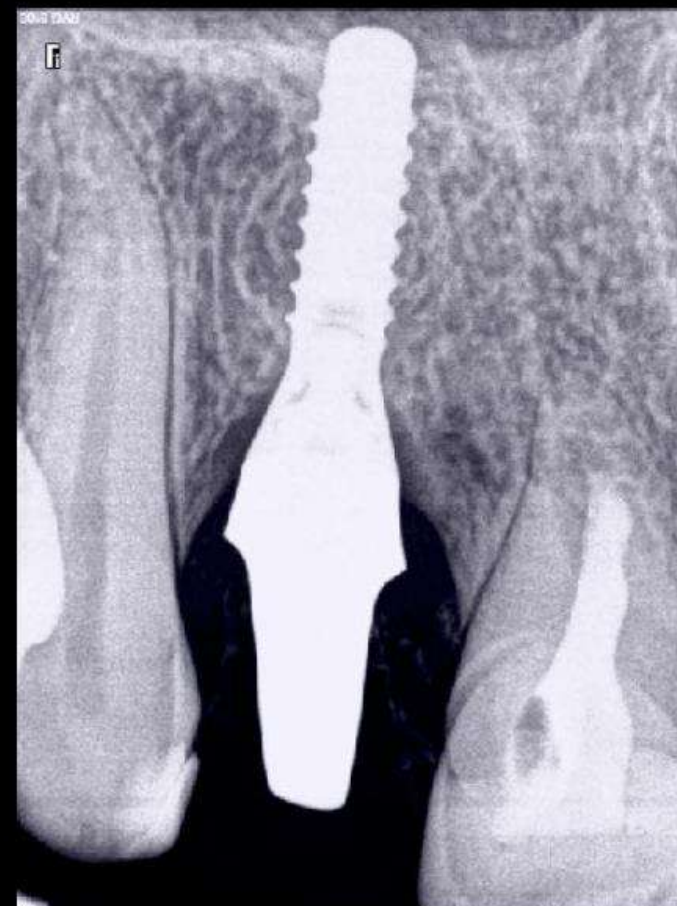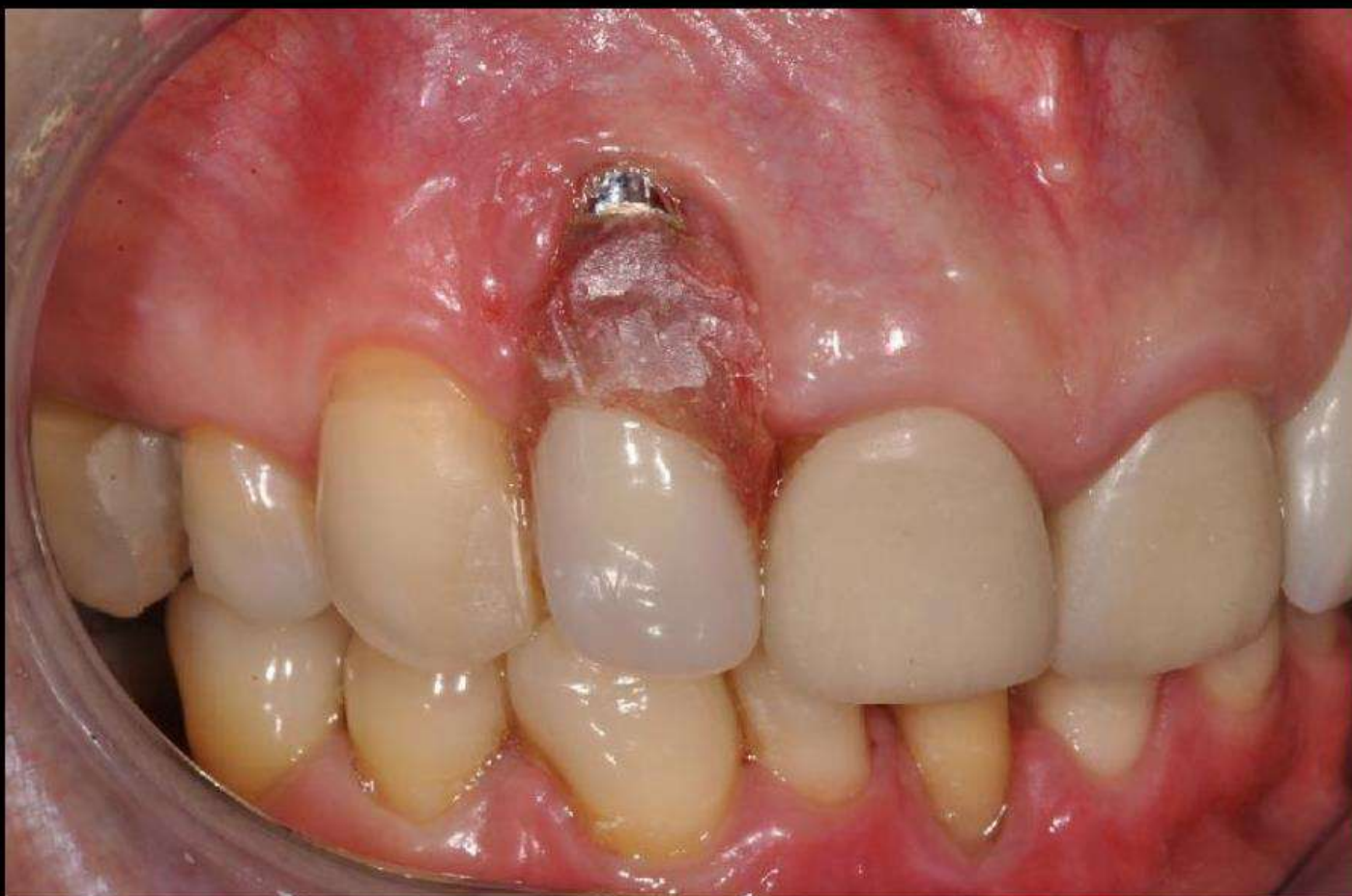2 years after immediate implant placement

Dr. João Gaspar

Dr. João Gaspar



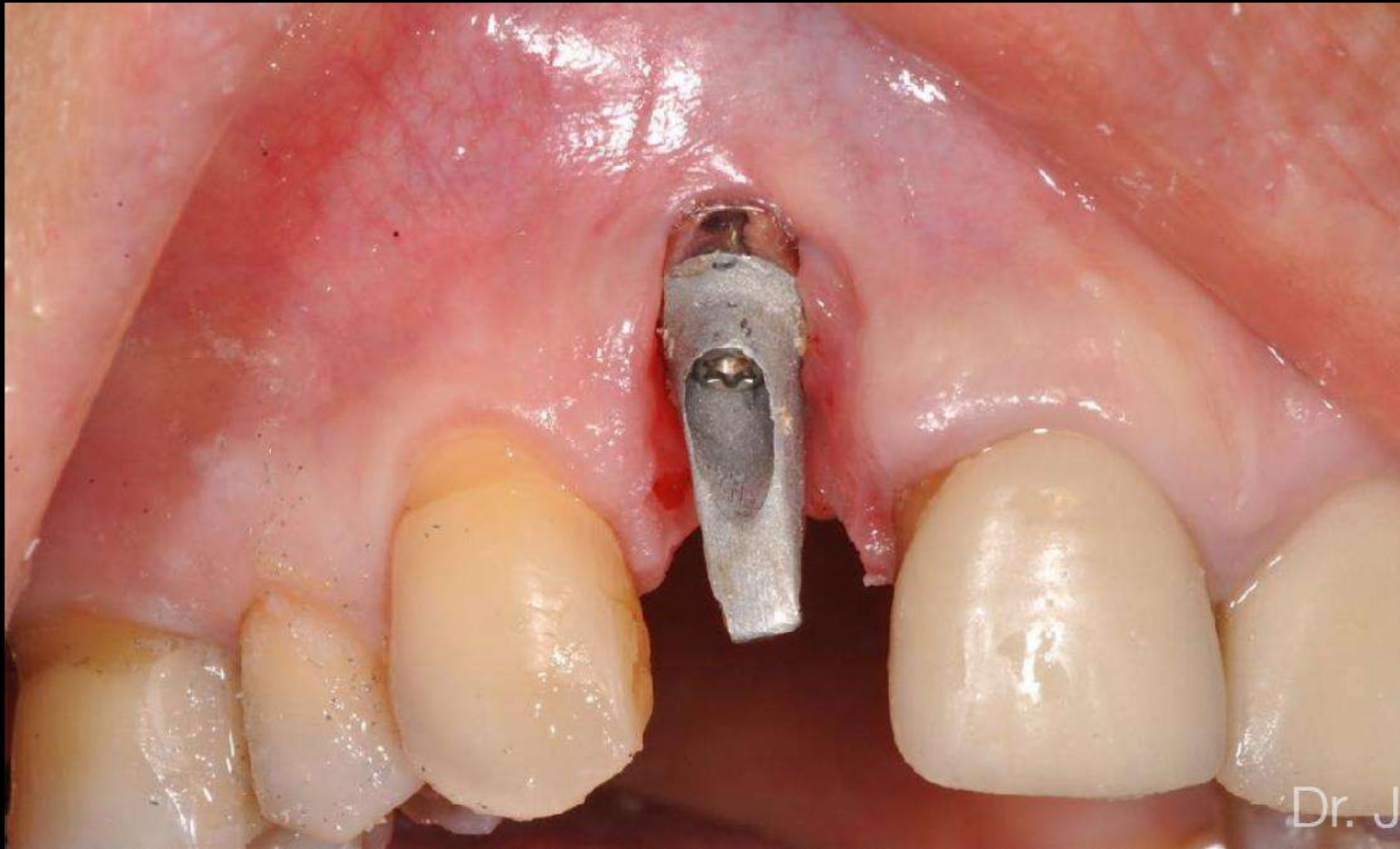
www.medbone.eu



Dr. João Gaspar

Dr. João Gaspar



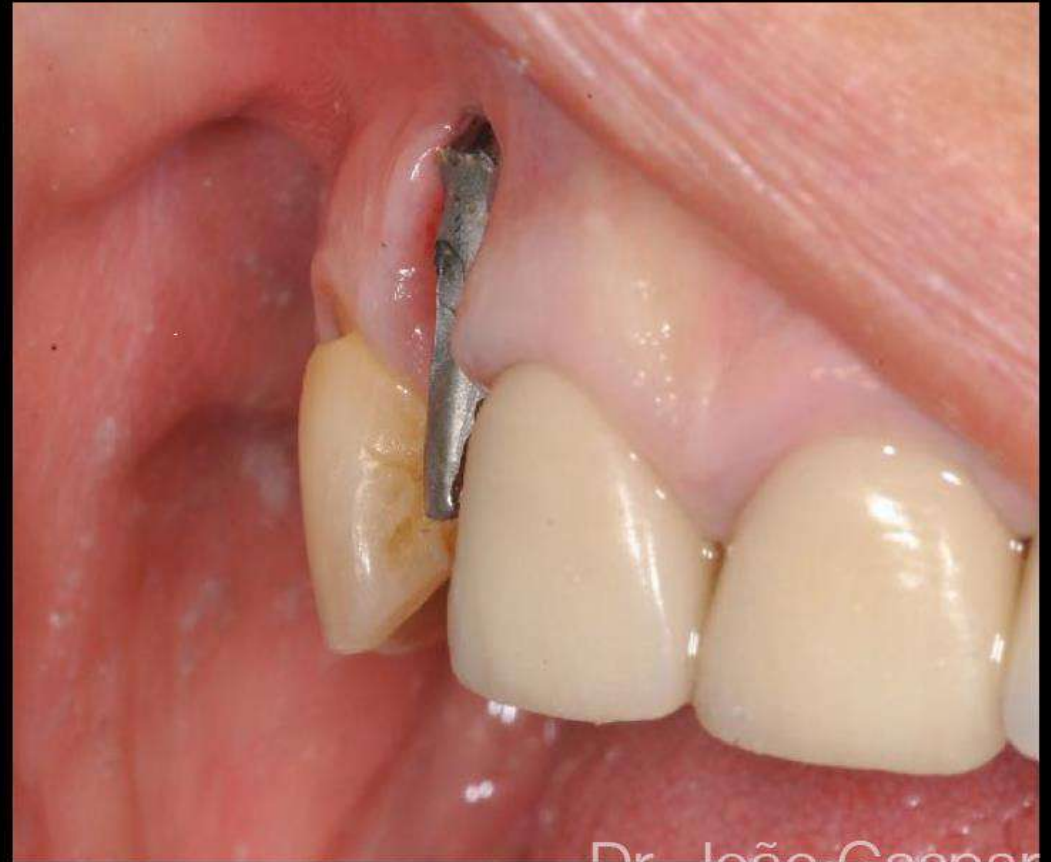
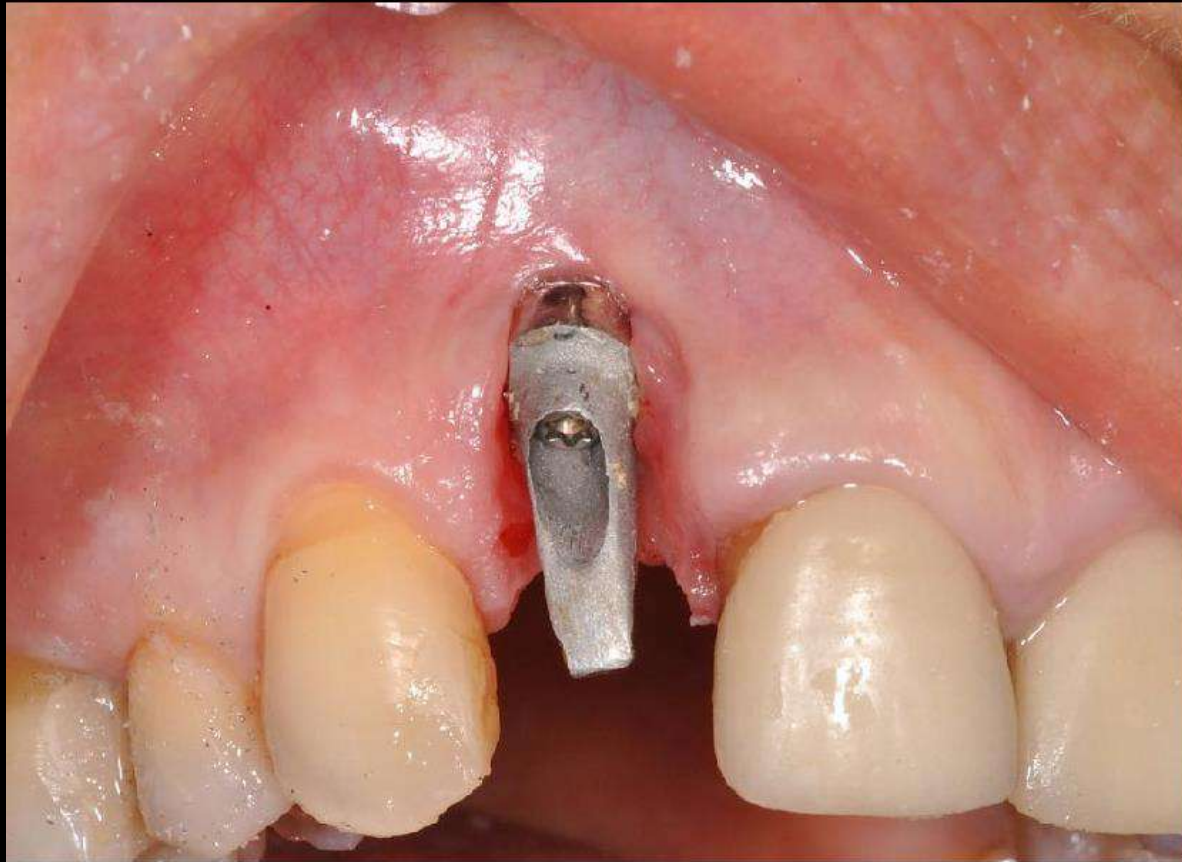
Dr. João Gaspar

Dr. João Gaspar



www.medbone.eu

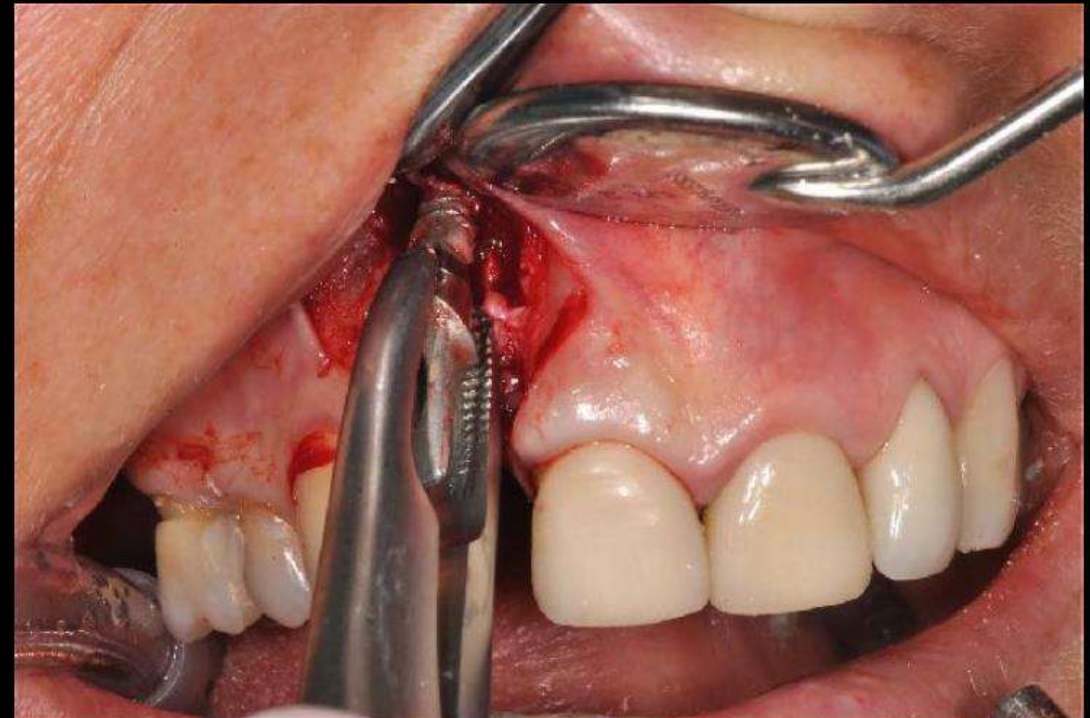
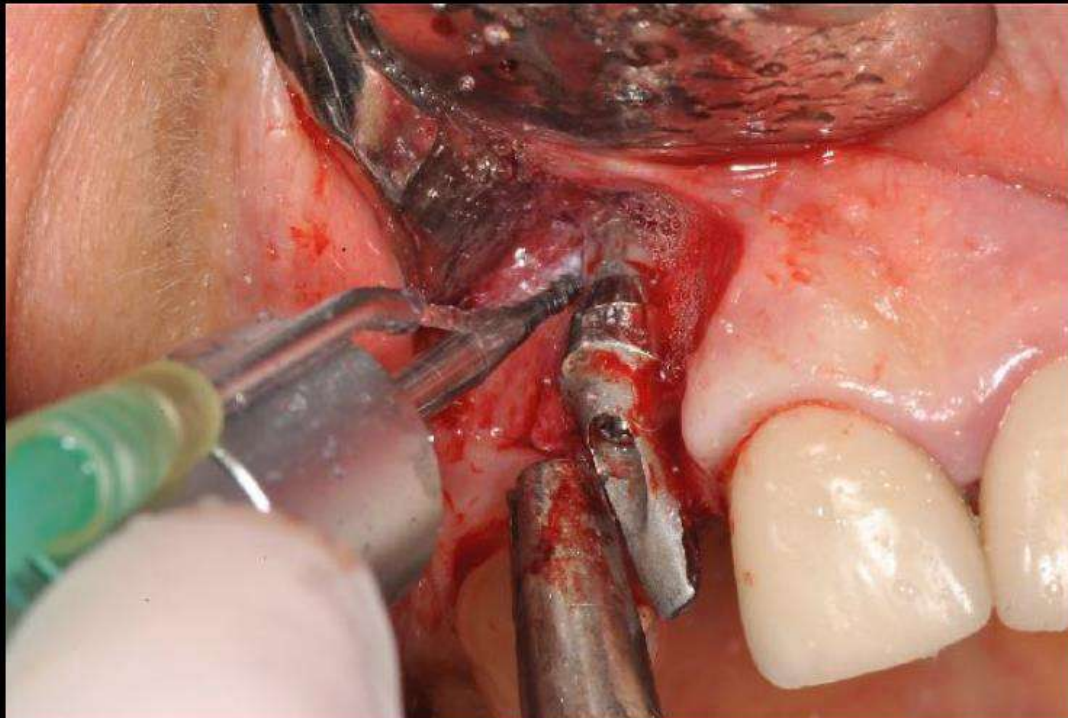


Dr. João Gaspar

Dr. João Gaspar



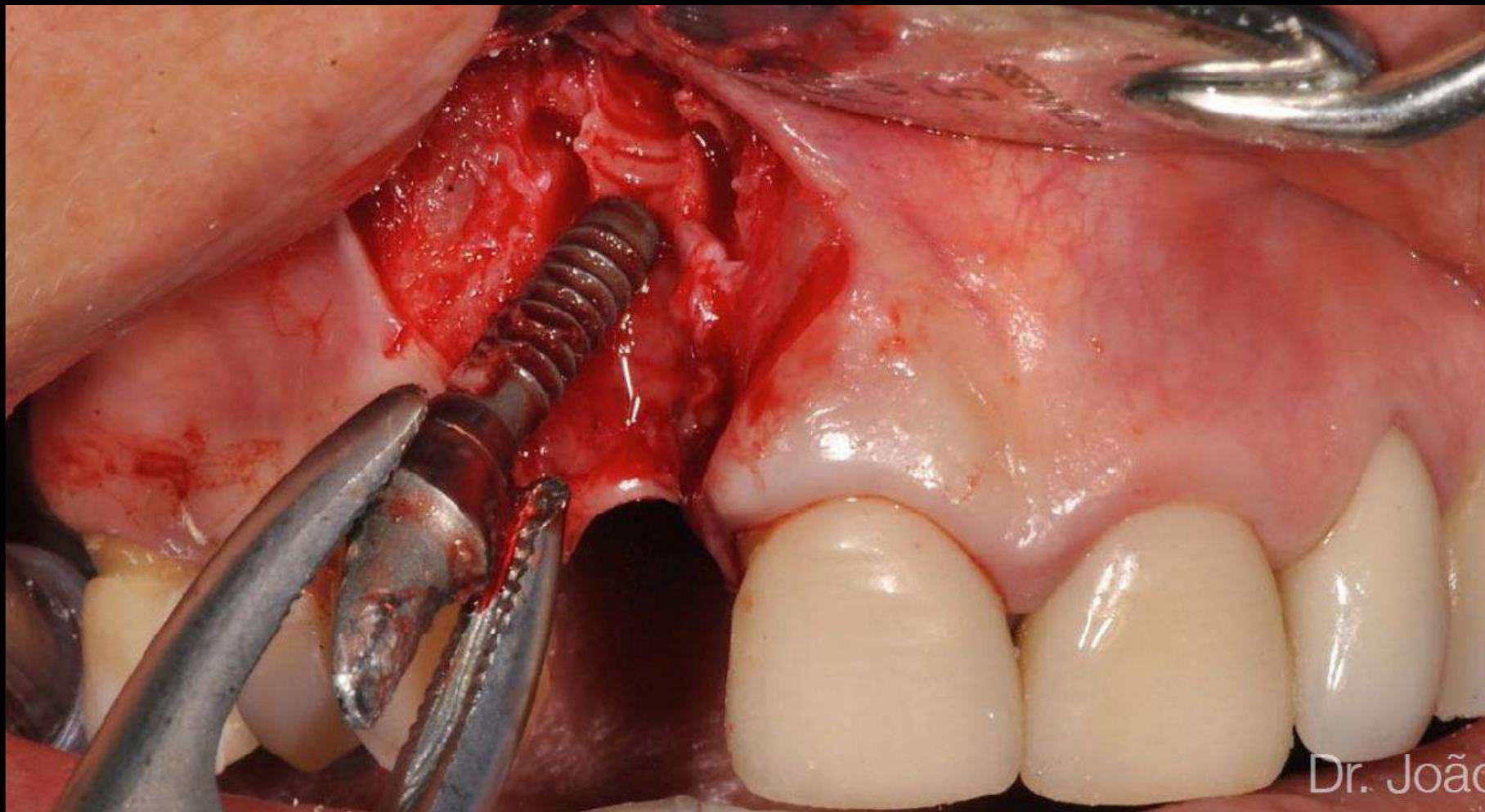
www.medbone.eu



Dr. João Gaspar

Dr. João Gaspar



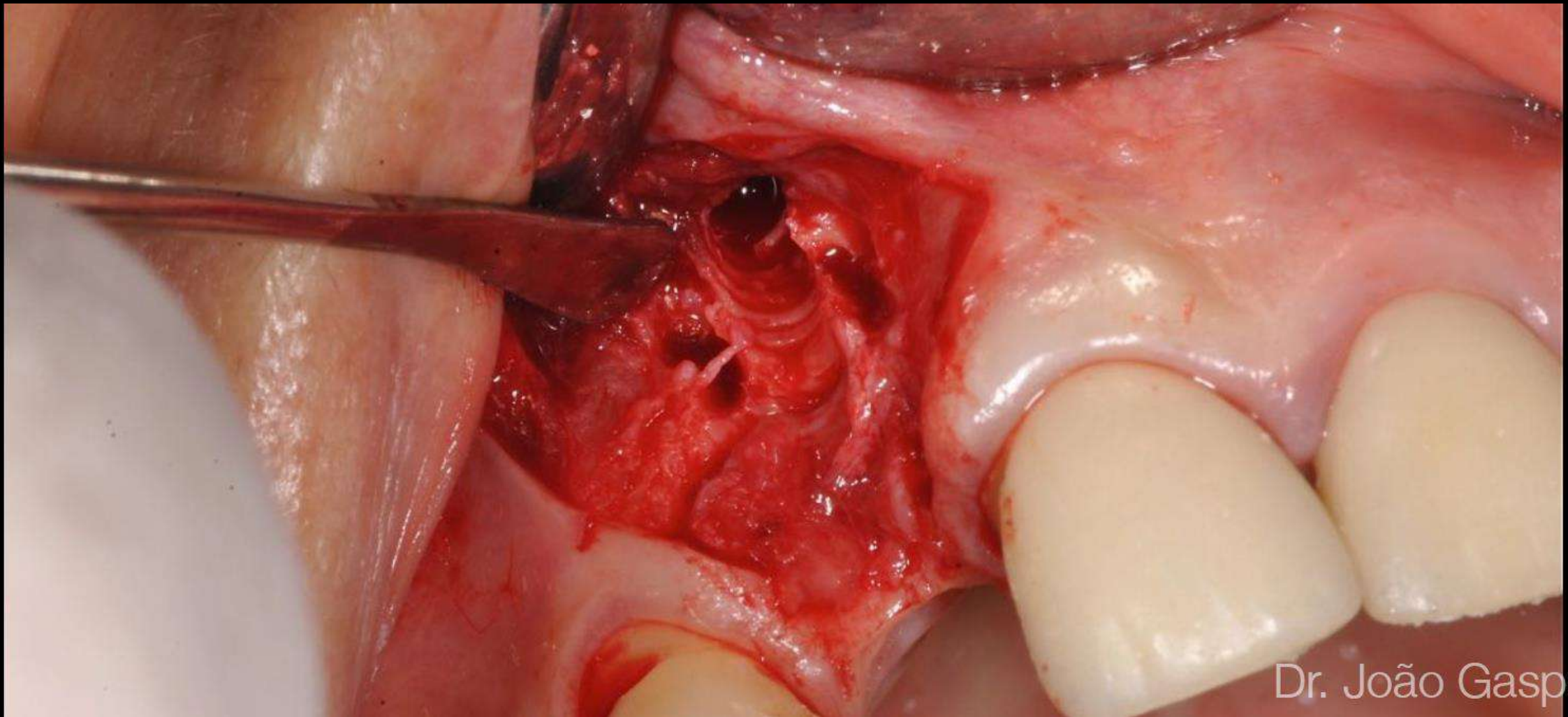


Dr. João Gaspar

Dr. João Gaspar



www.medbone.eu

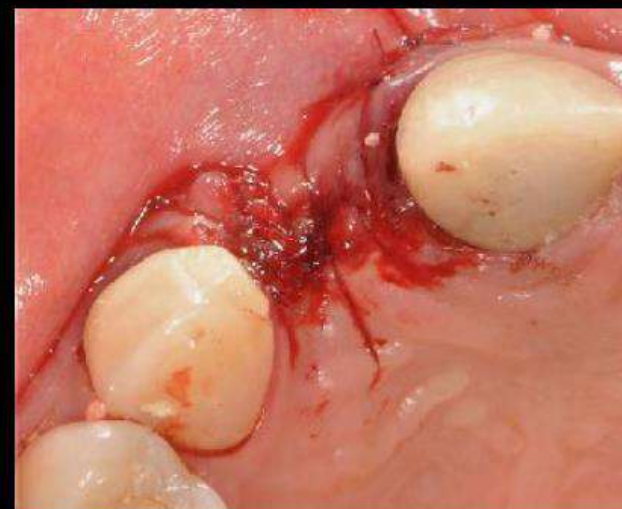
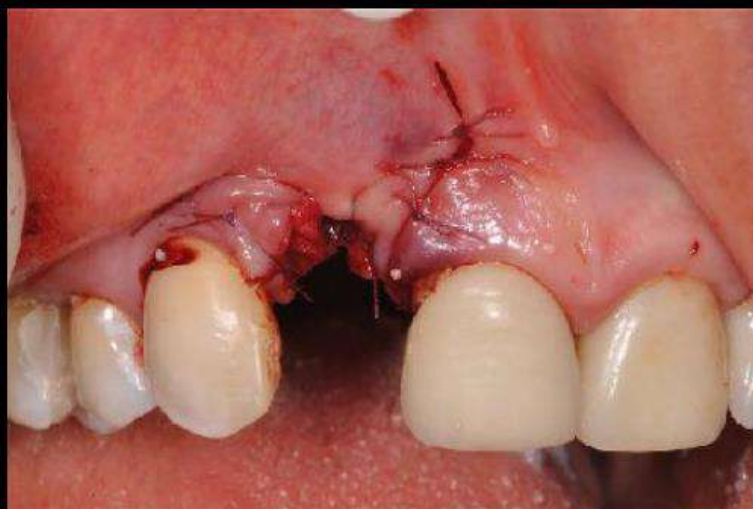
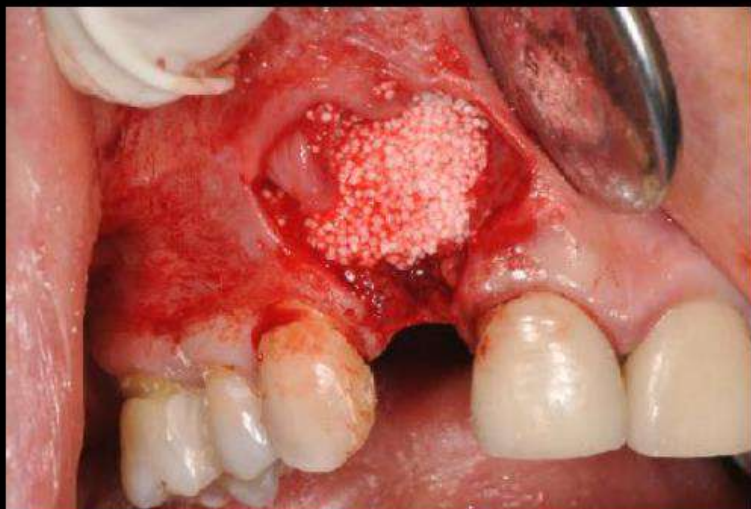
Dr. João Gaspar

Dr. João Gaspar



www.medbone.eu

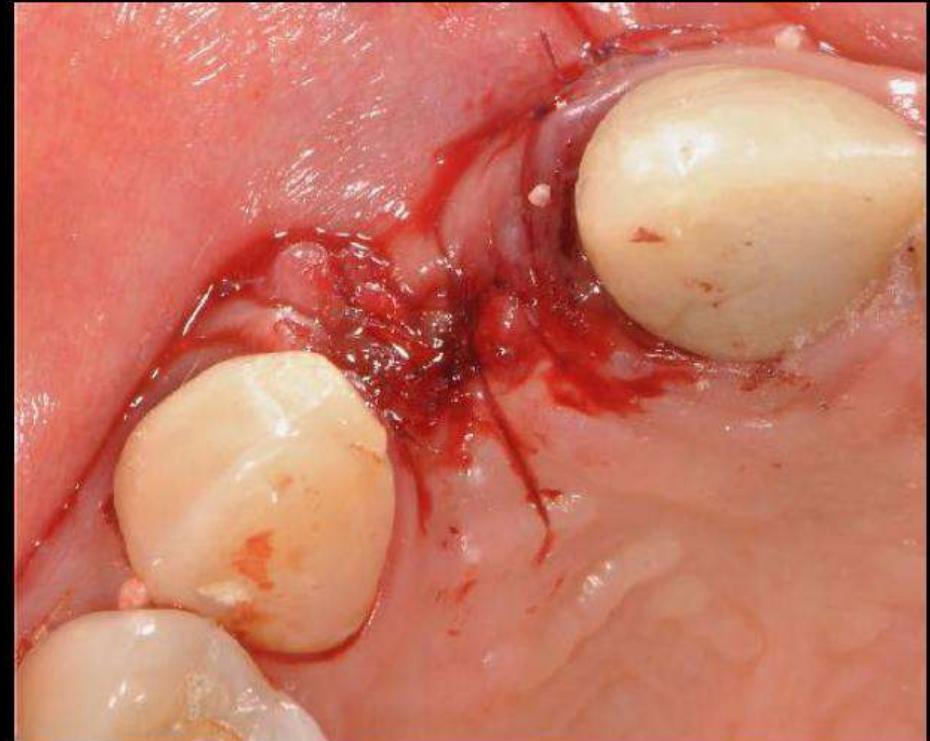
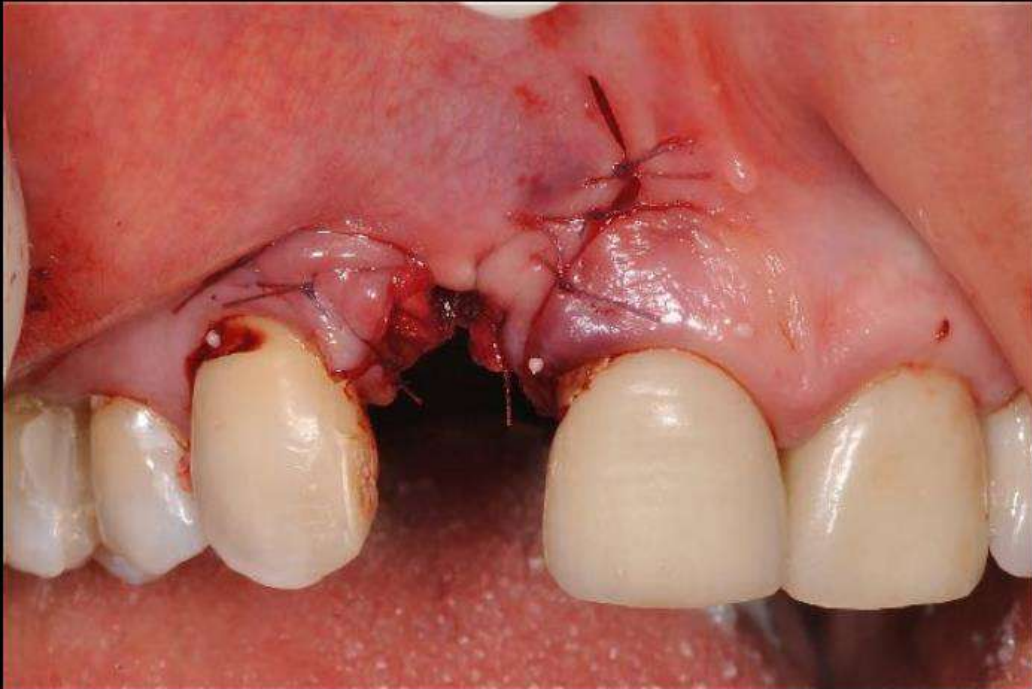

Dr. João Gaspar

Dr. João Gaspar



www.medbone.eu

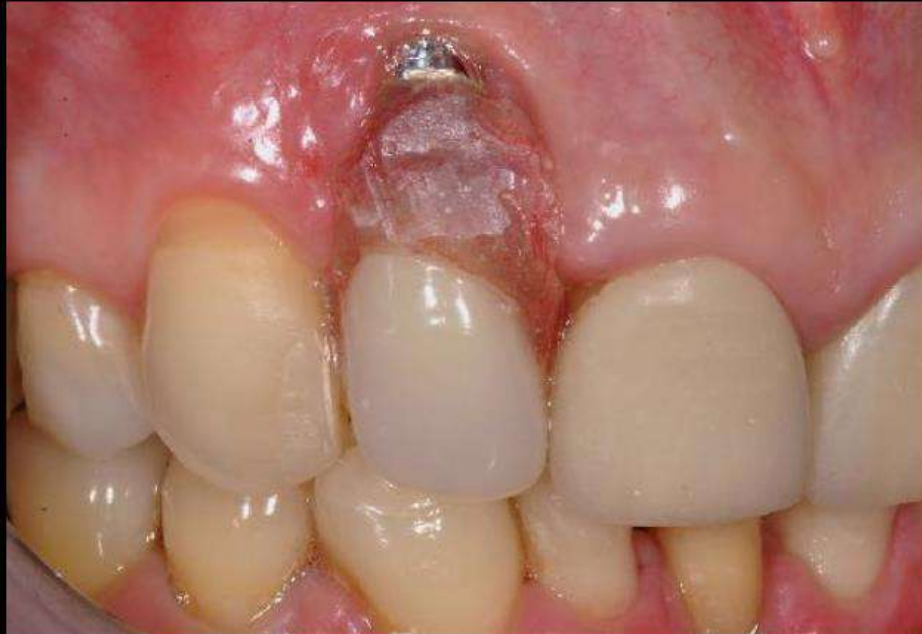

Dr. João Gaspar

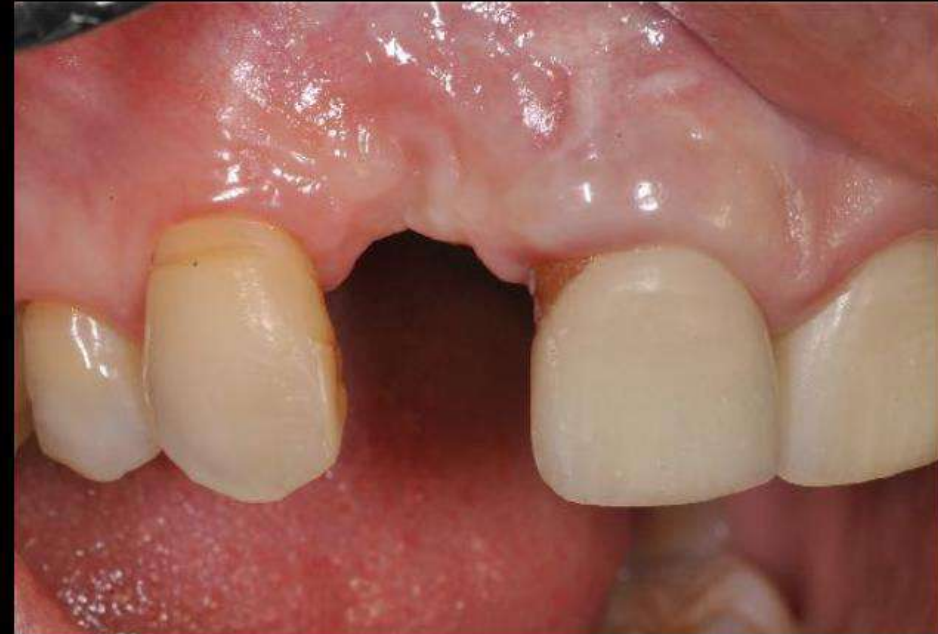Dr. João Gaspar



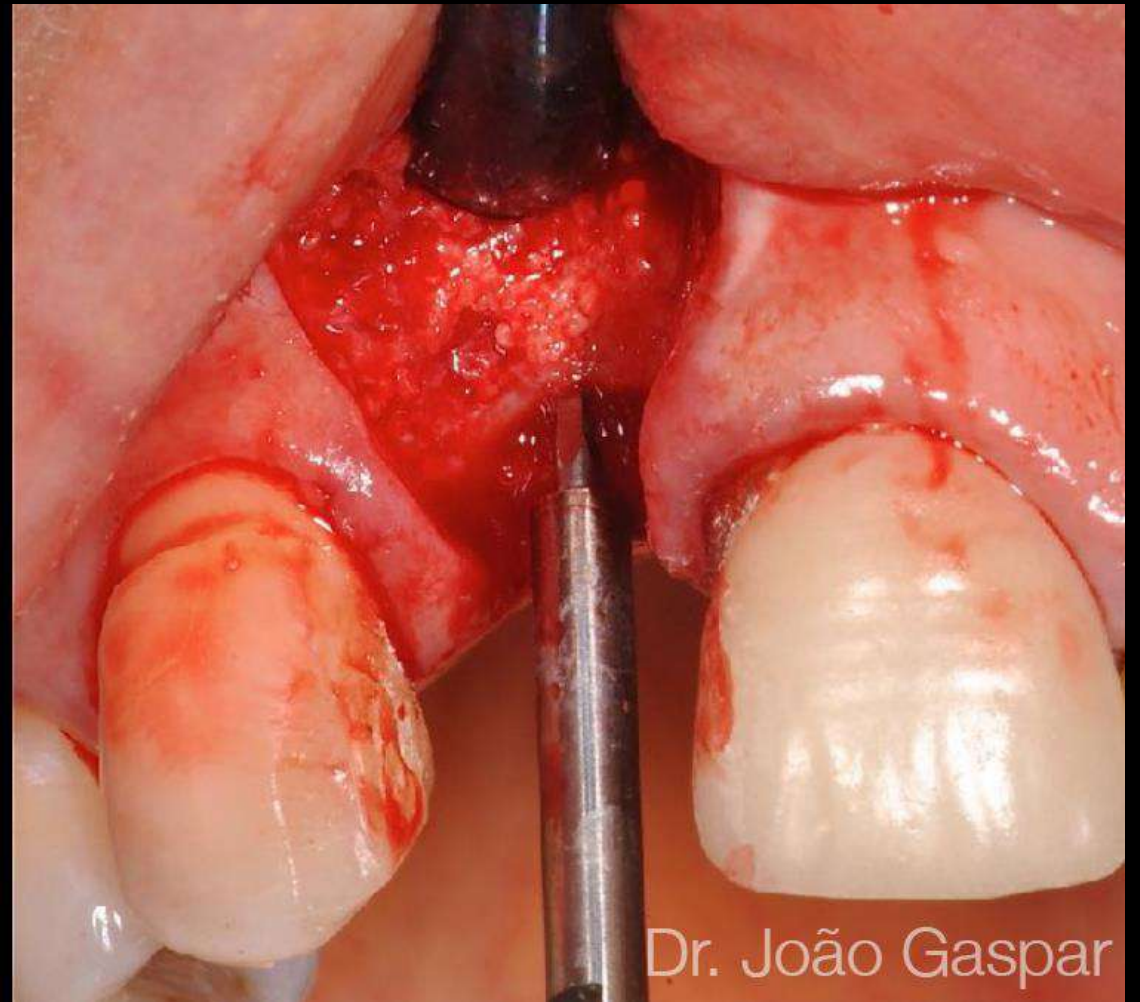
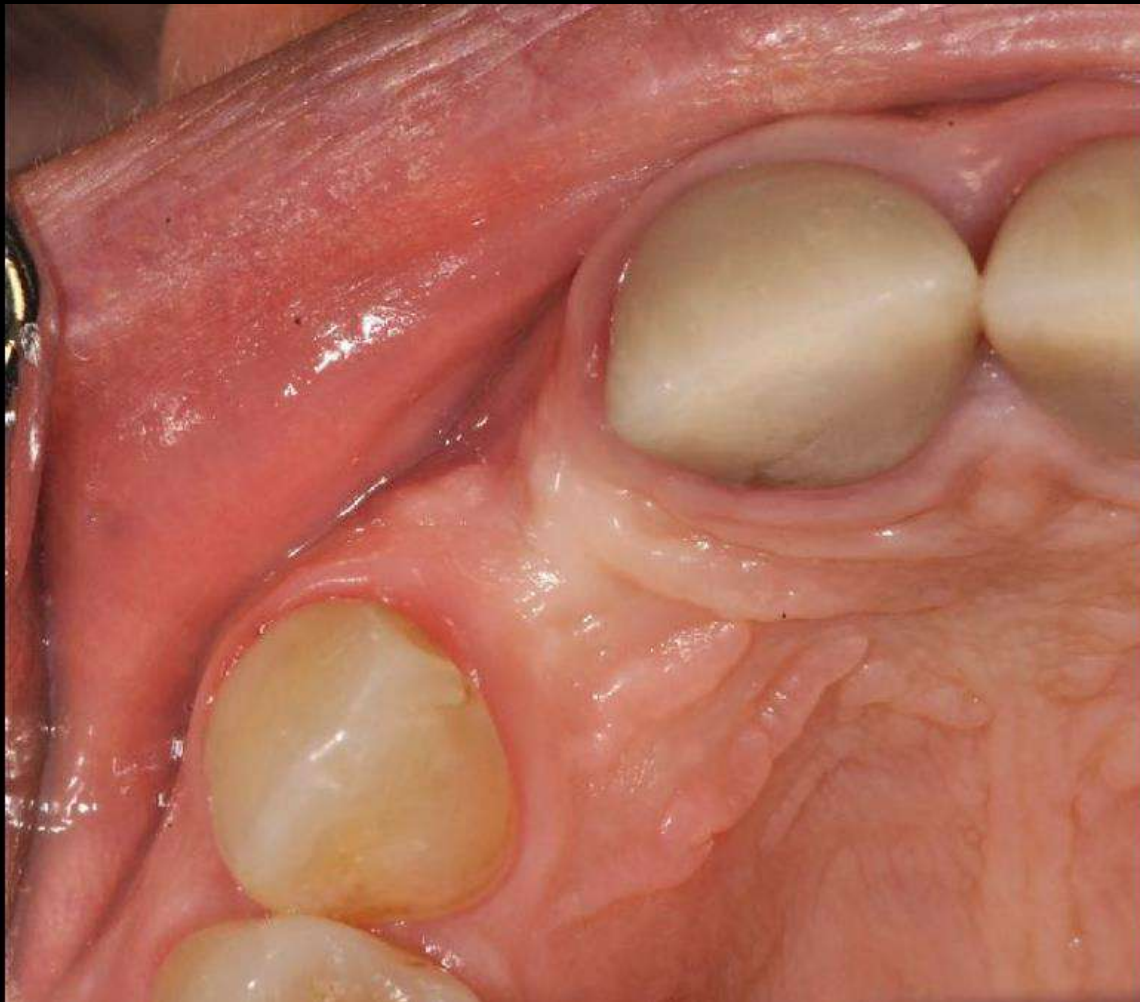
www.medbone.eu



baseline



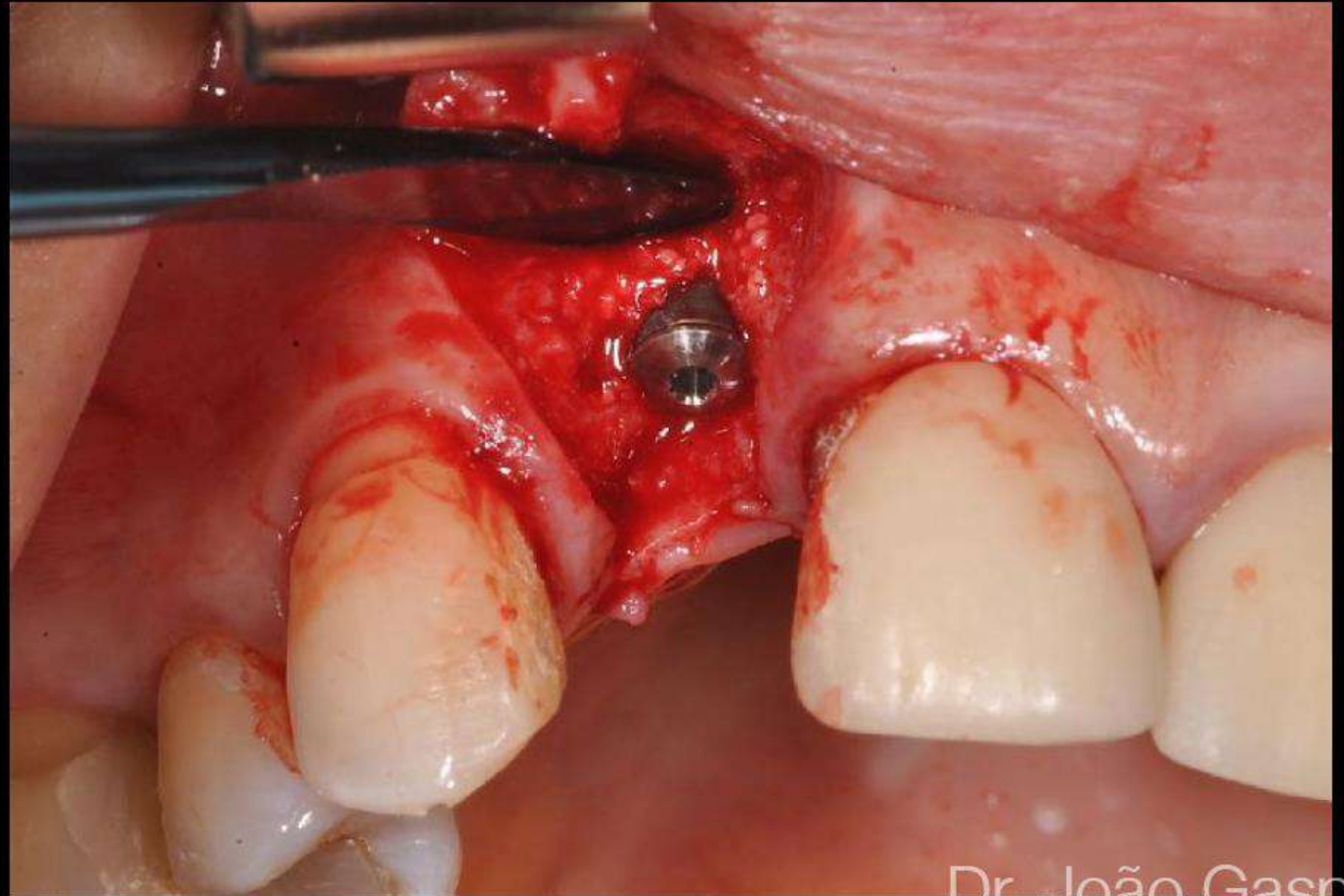
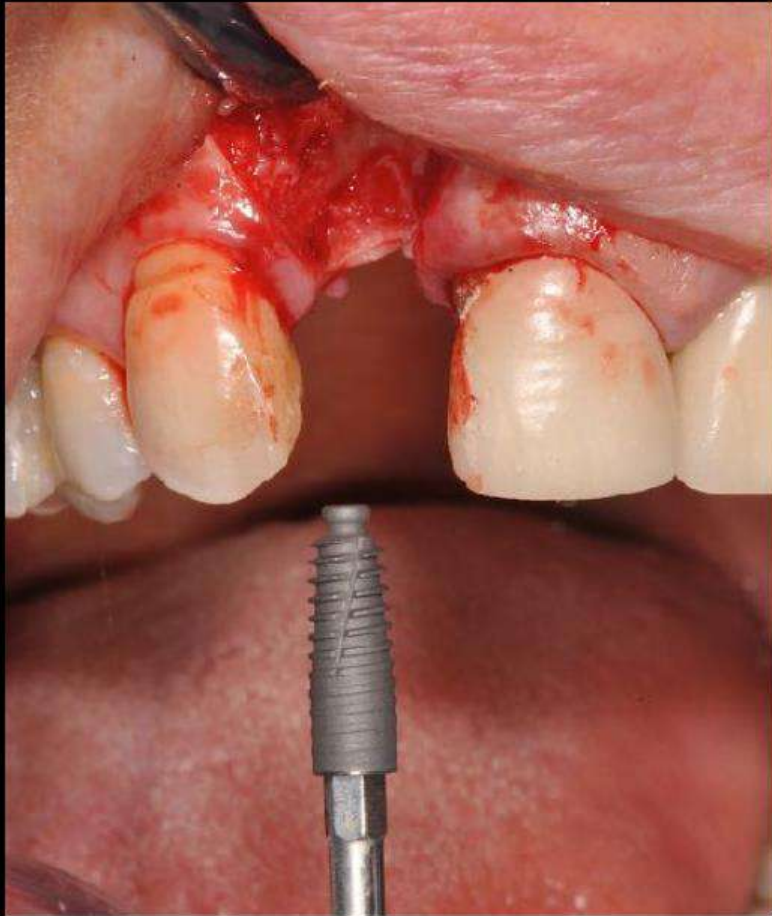after 4 months



Dr. João Gaspar



www.medbone.eu

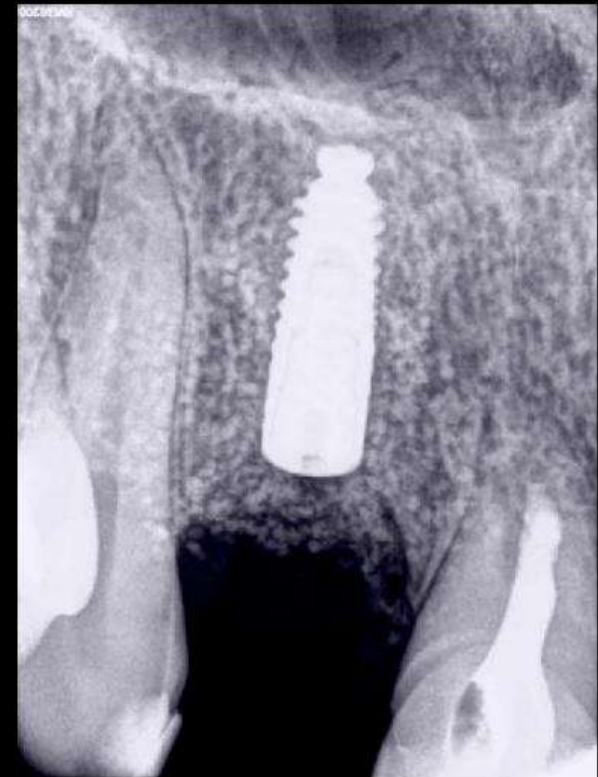
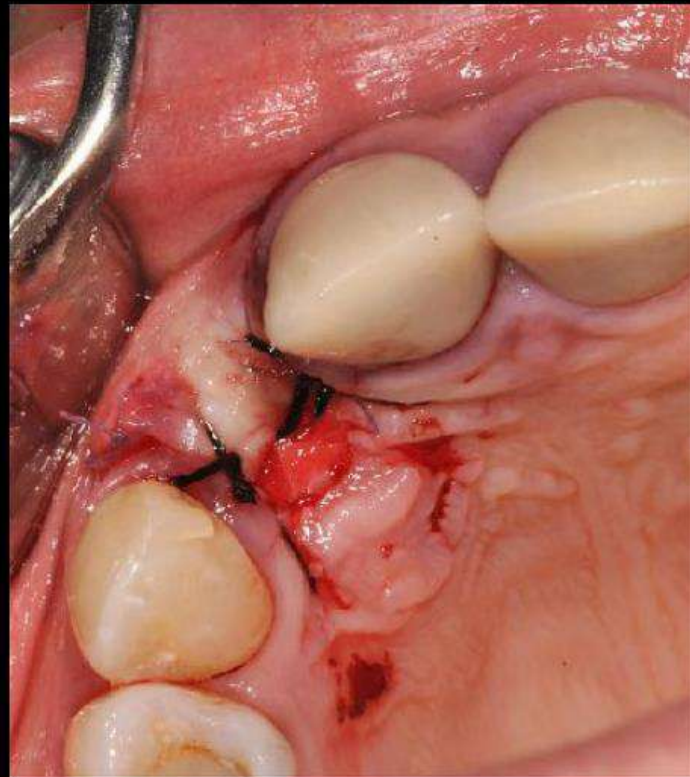
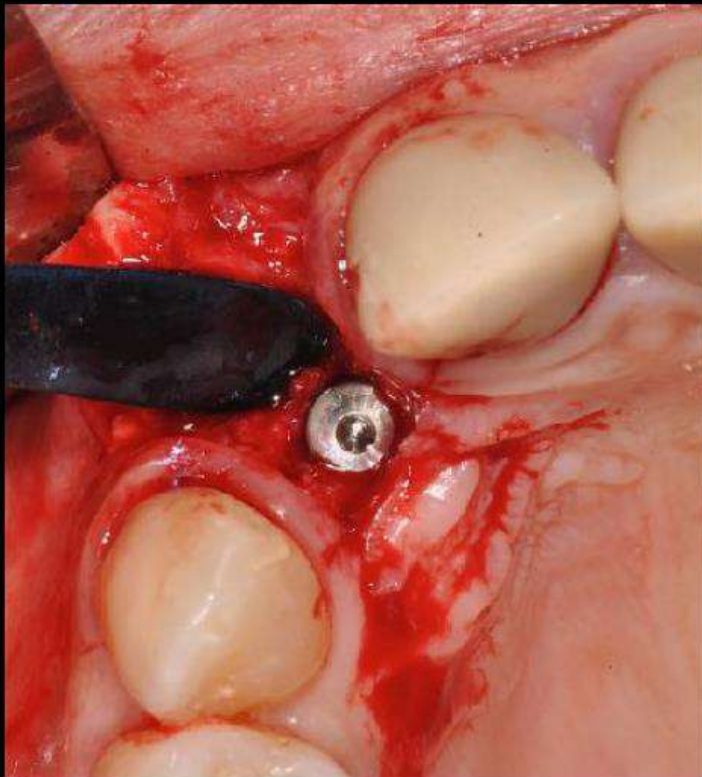


Dr. João Gaspar

Dr. João Gaspar



www.medbone.eu

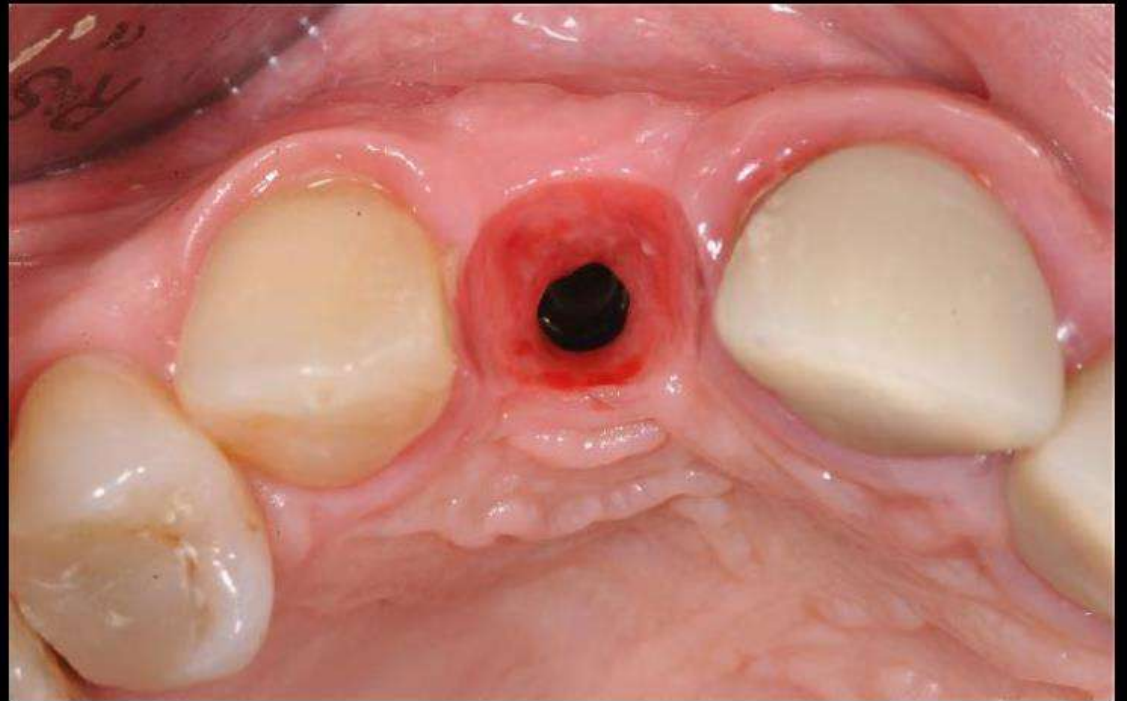
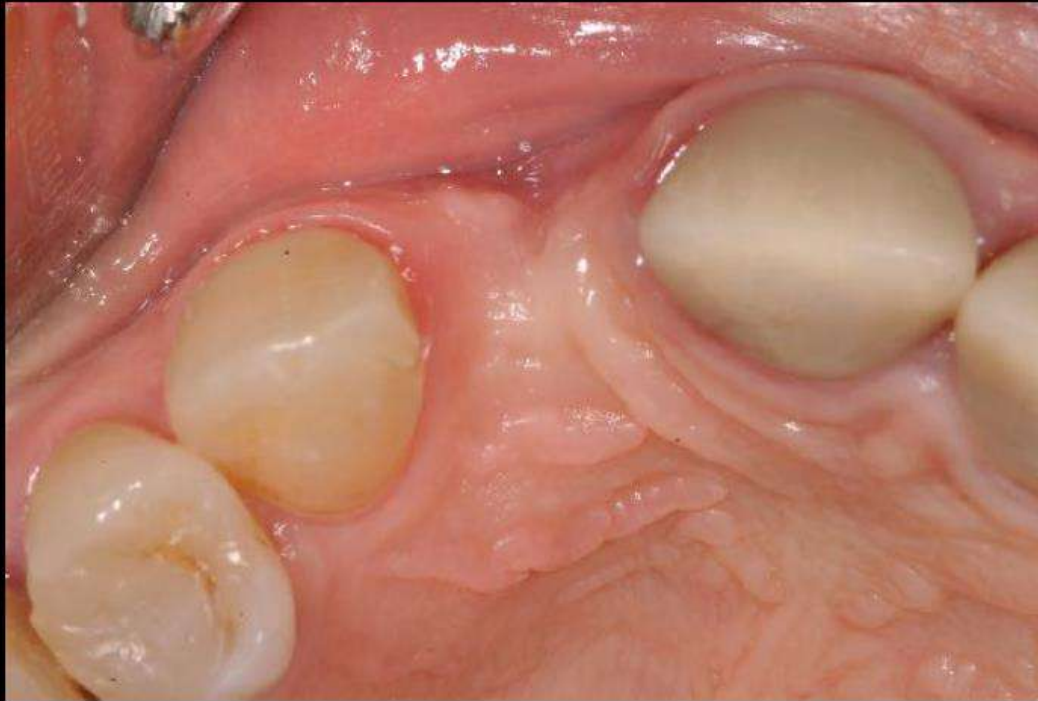


Dr. João Gaspar

Dr. João Gaspar



www.medbone.eu



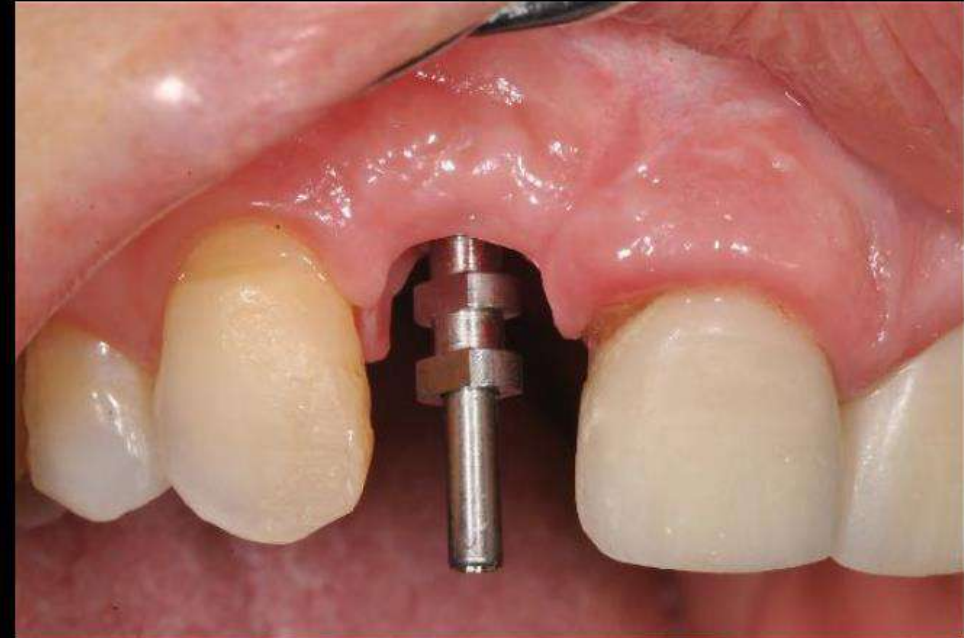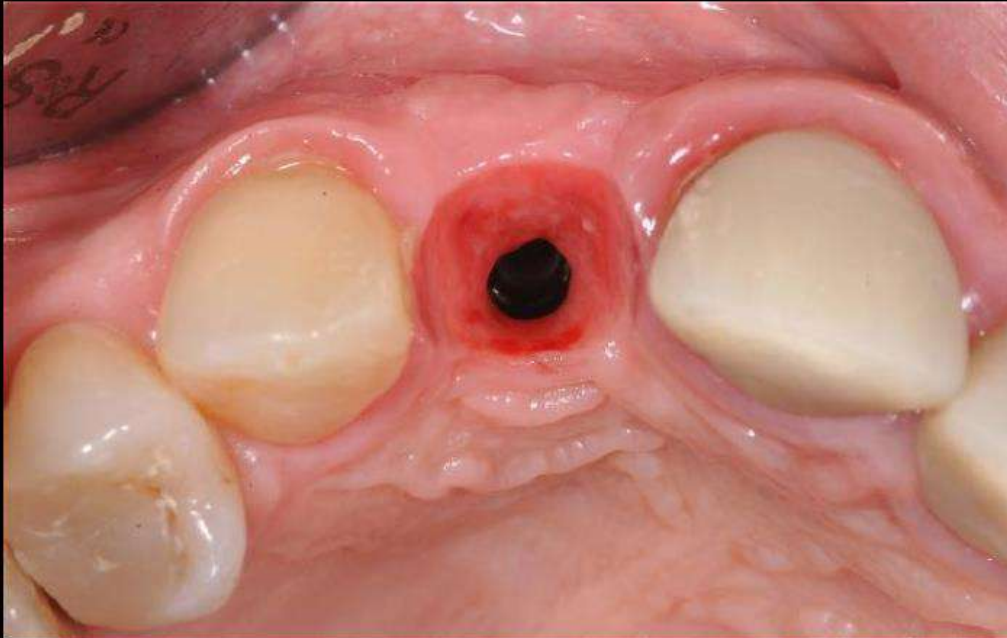
After 4 months with provisional crown

Dr. João Gaspar

Dr. João Gaspar



www.medbone.eu

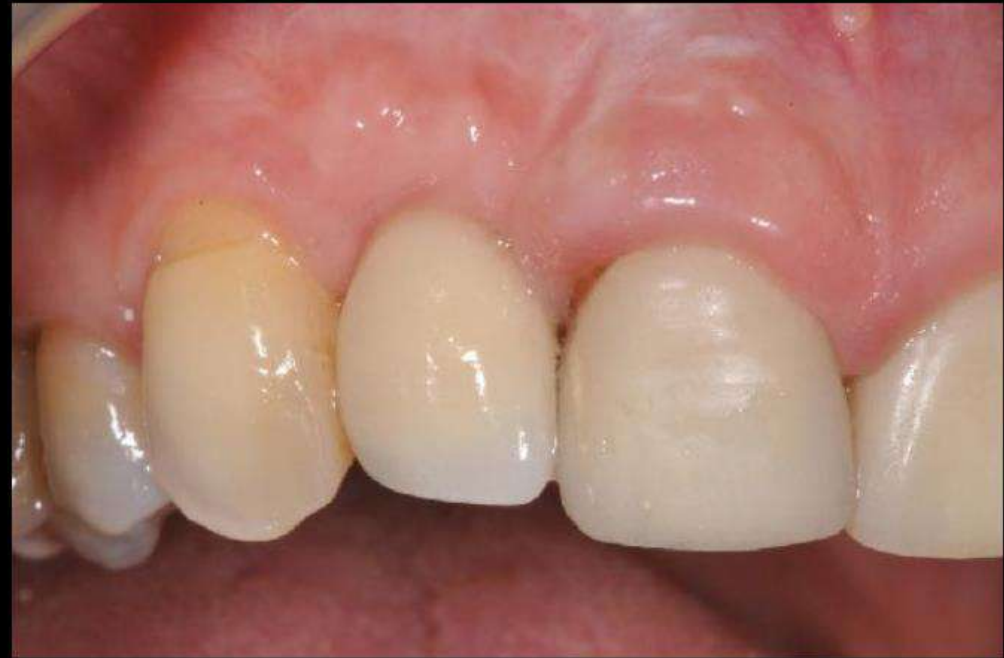
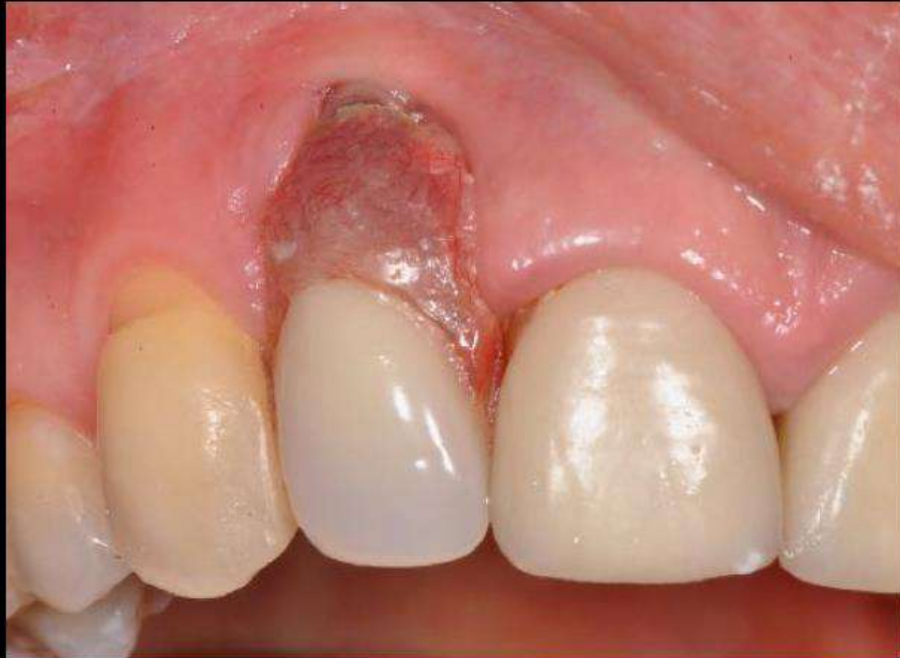
Dr. João Gaspar

Dr. João Gaspar



www.medbone.eu

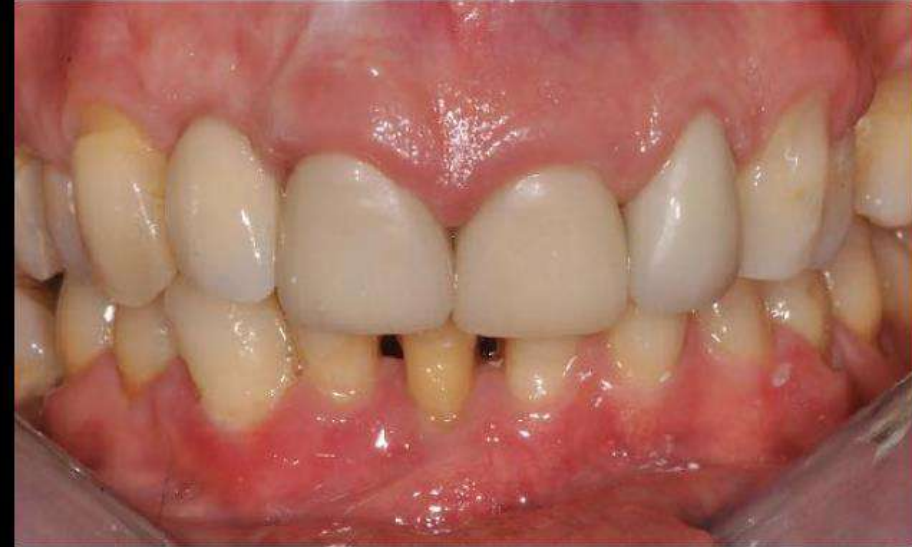
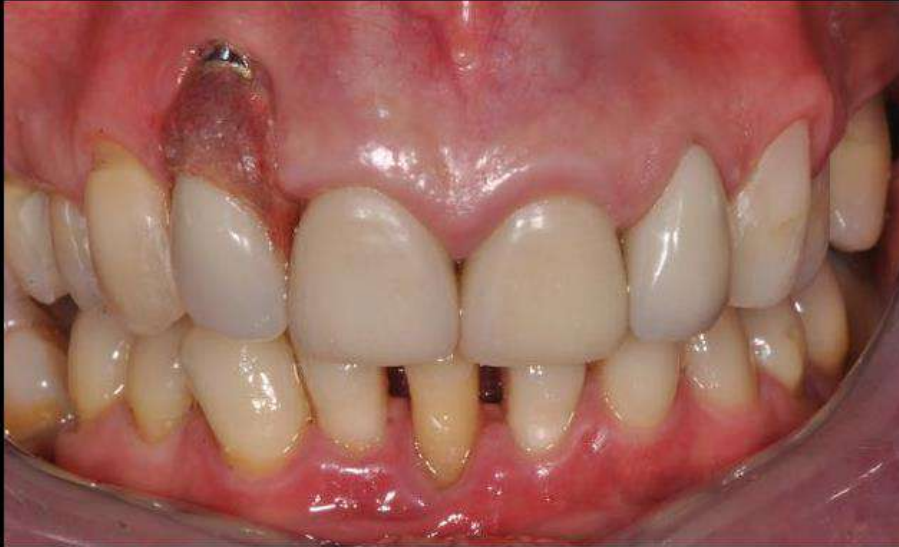
Dr. João Gaspar

Dr. João Gaspar



www.medbone.eu



2 anos follow-up

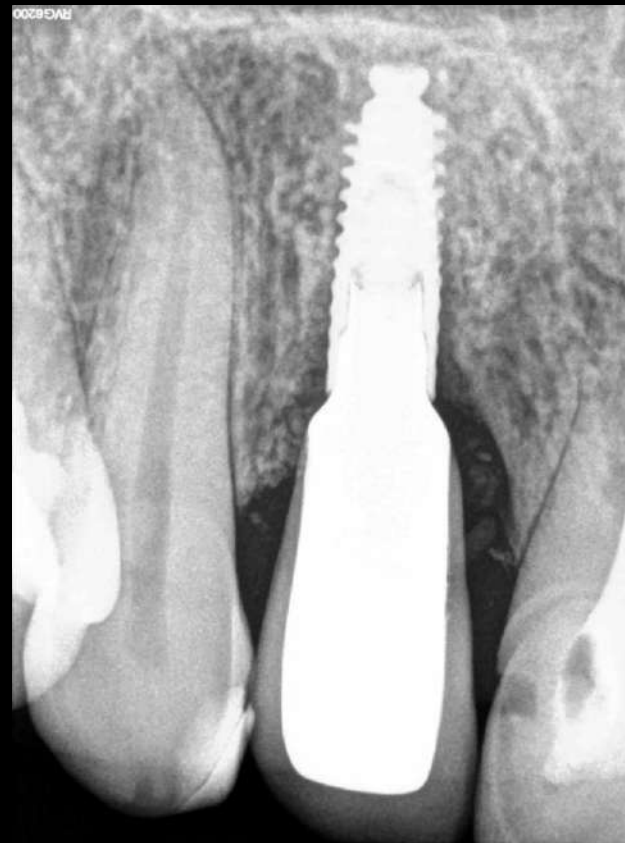Dr. João Gaspar

Dr. João Gaspar



www.medbone.eu

2 anos pós-op



Dr. João Gaspar



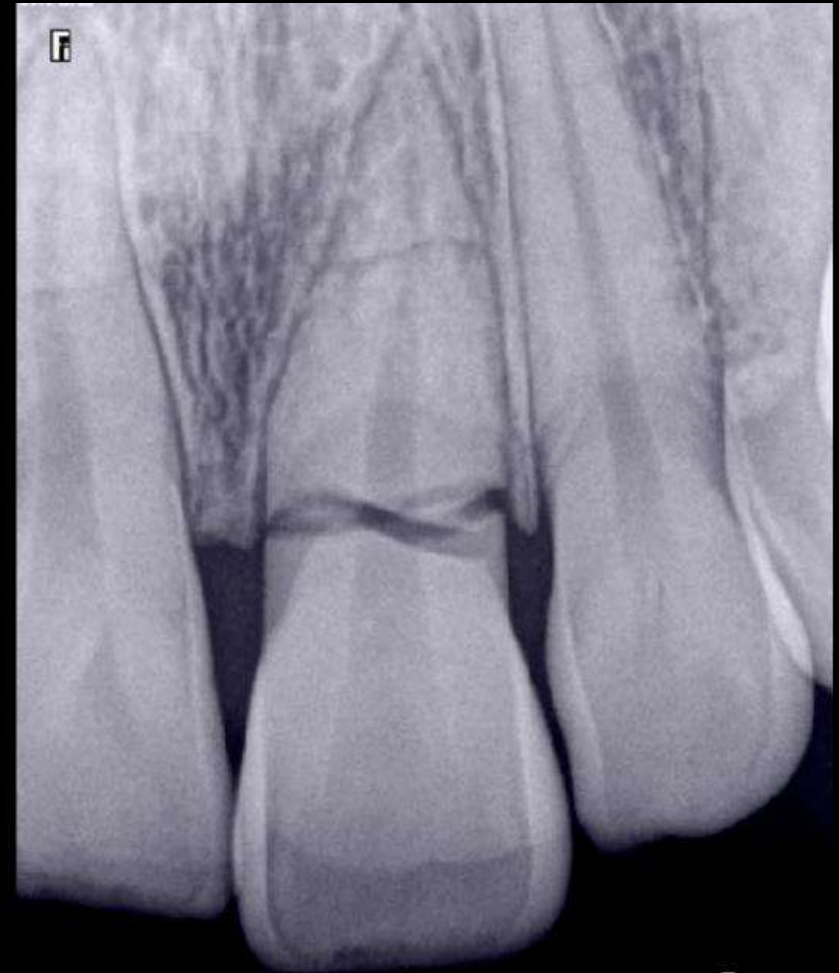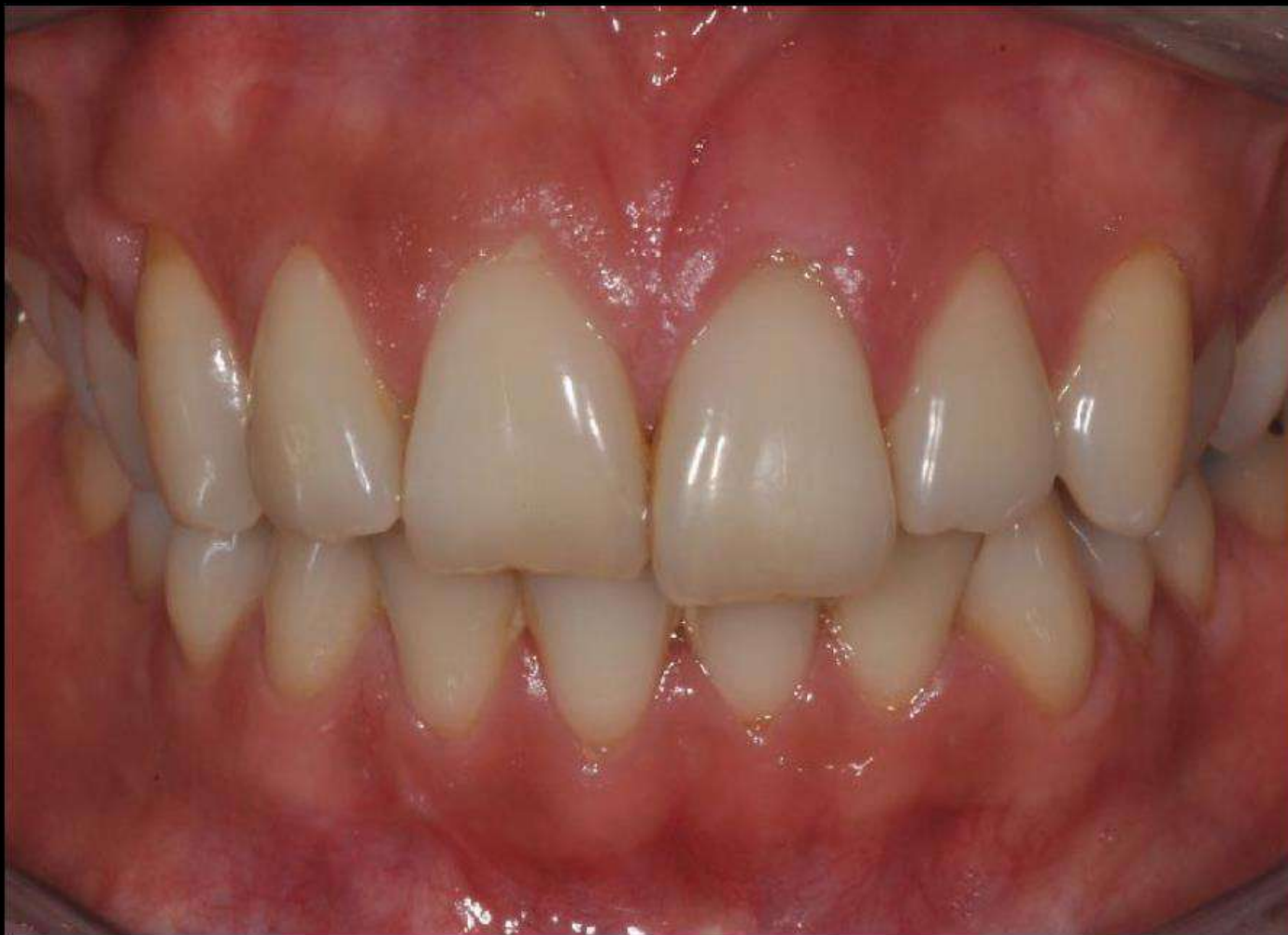www.medbone.eu



Medbone®
BIOMATERIALS

CASE 7

adbone® TCP

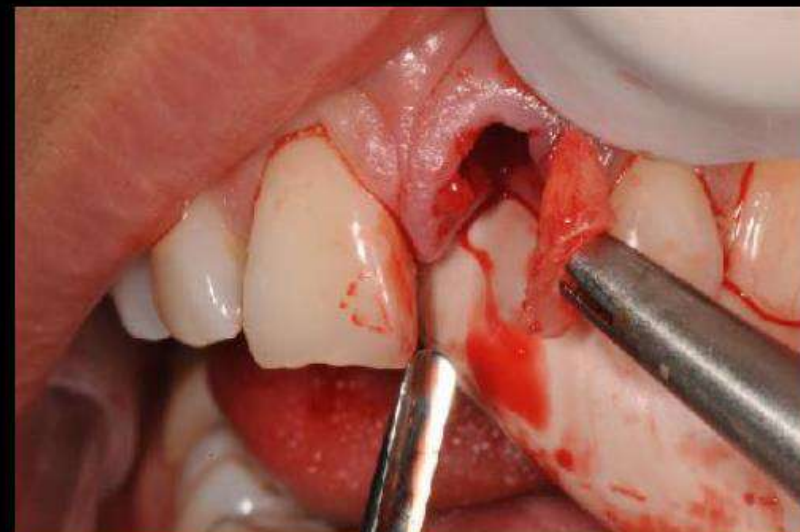
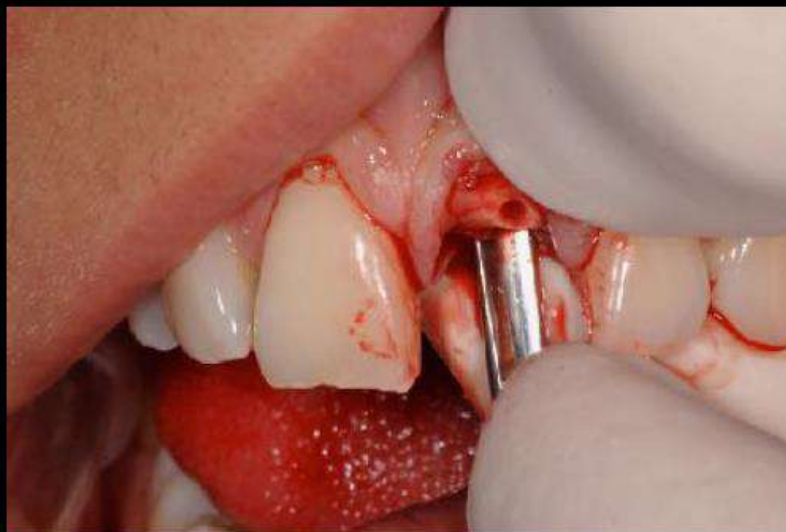
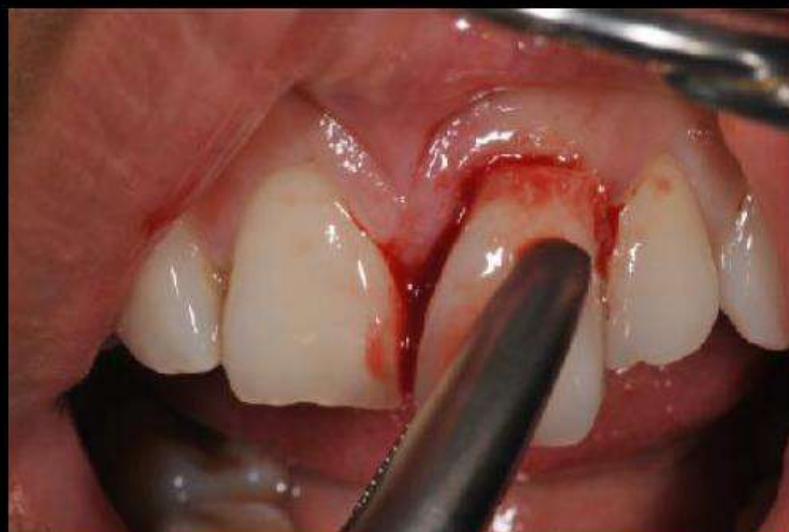Dr. João Gaspar

Dr. João Gaspar



www.medbone.eu

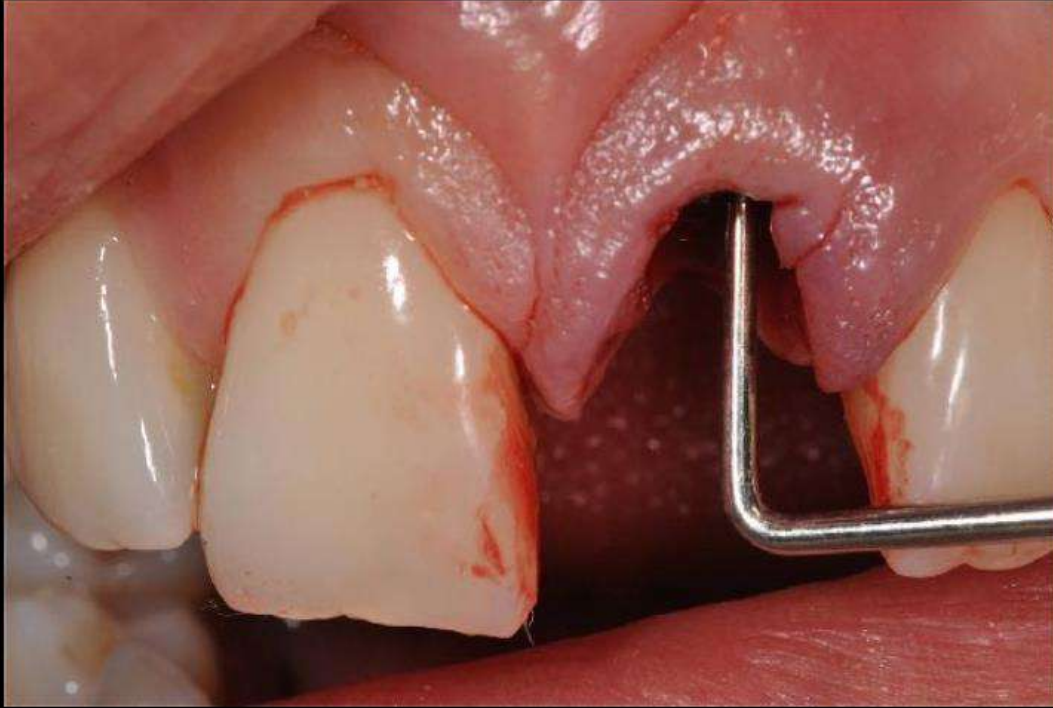


Dr. João Gaspar

Dr. João Gaspar



www.medbone.eu

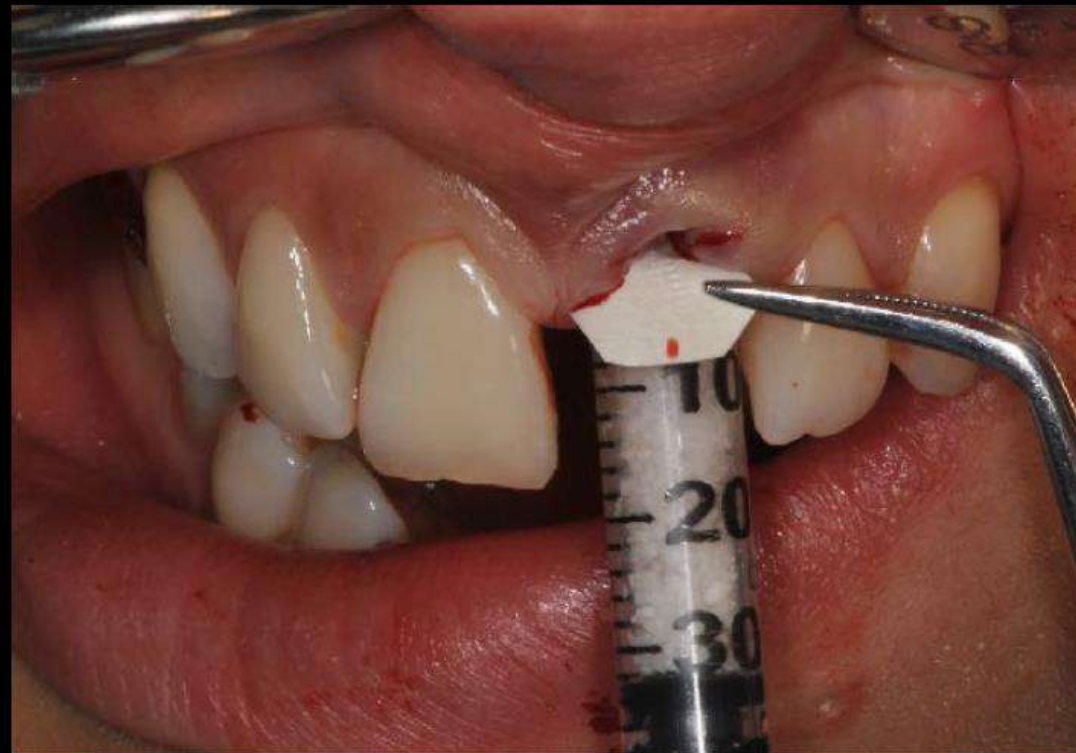
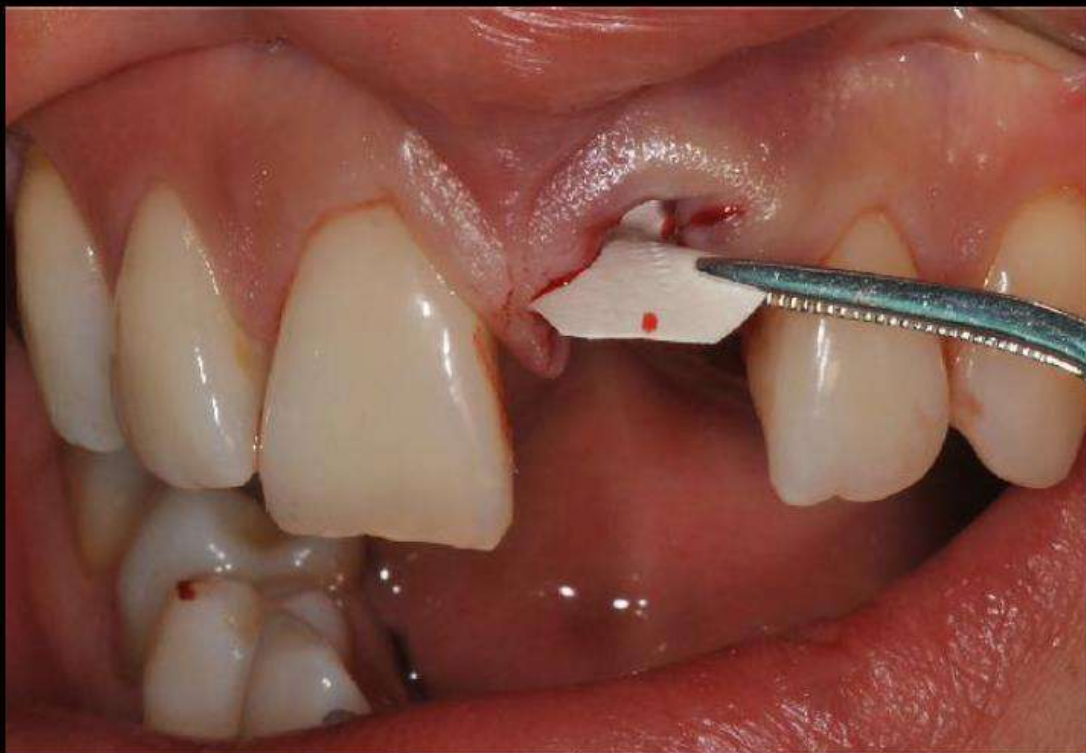
A SIMPLIFIED SOCKET CLASSIFICATION
AND REPAIR TECHNIQUE
Dr. João Gaspar
Neel, PhD, DSE + Endo, Crown Clin, FRCR, RCSEd + Silver Frost, FRCR
Richard B. Smith, DDDP + Dennis F. Tarlow, DDDP

Dr. João Gaspar



www.medbone.eu

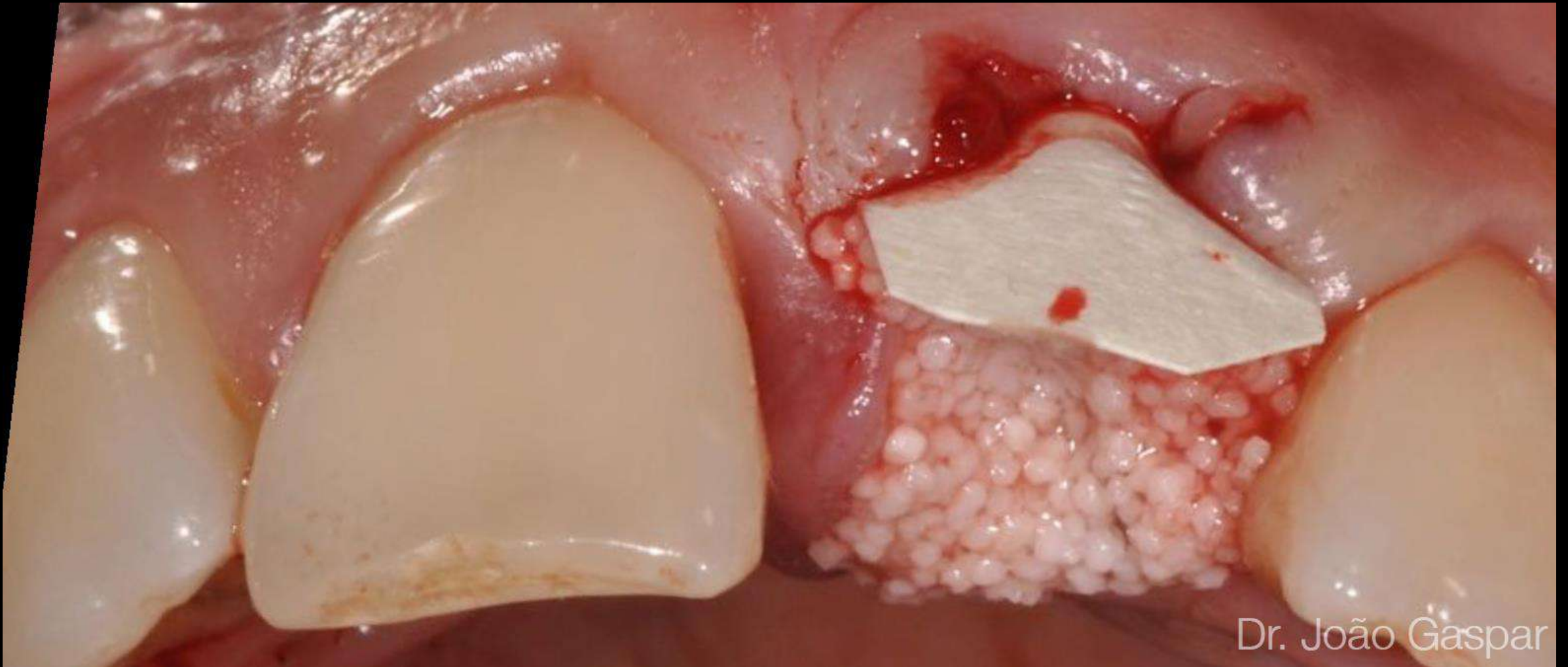


Dr. João Gaspar

Dr. João Gaspar



www.medbone.eu

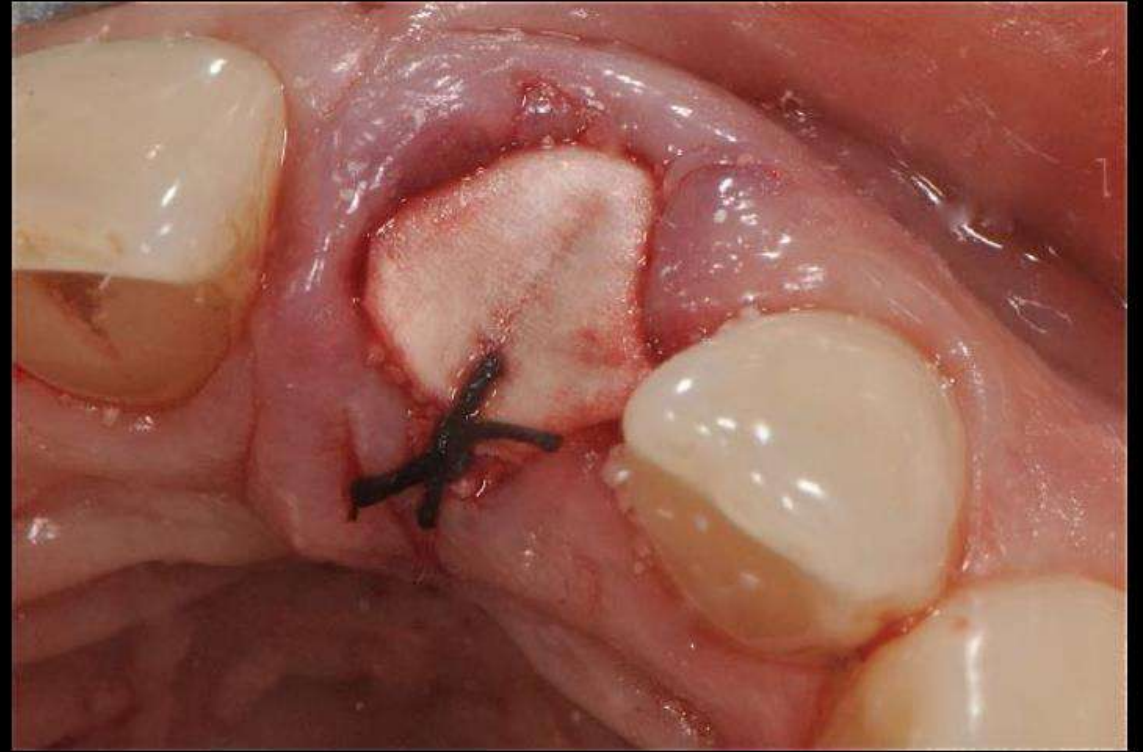
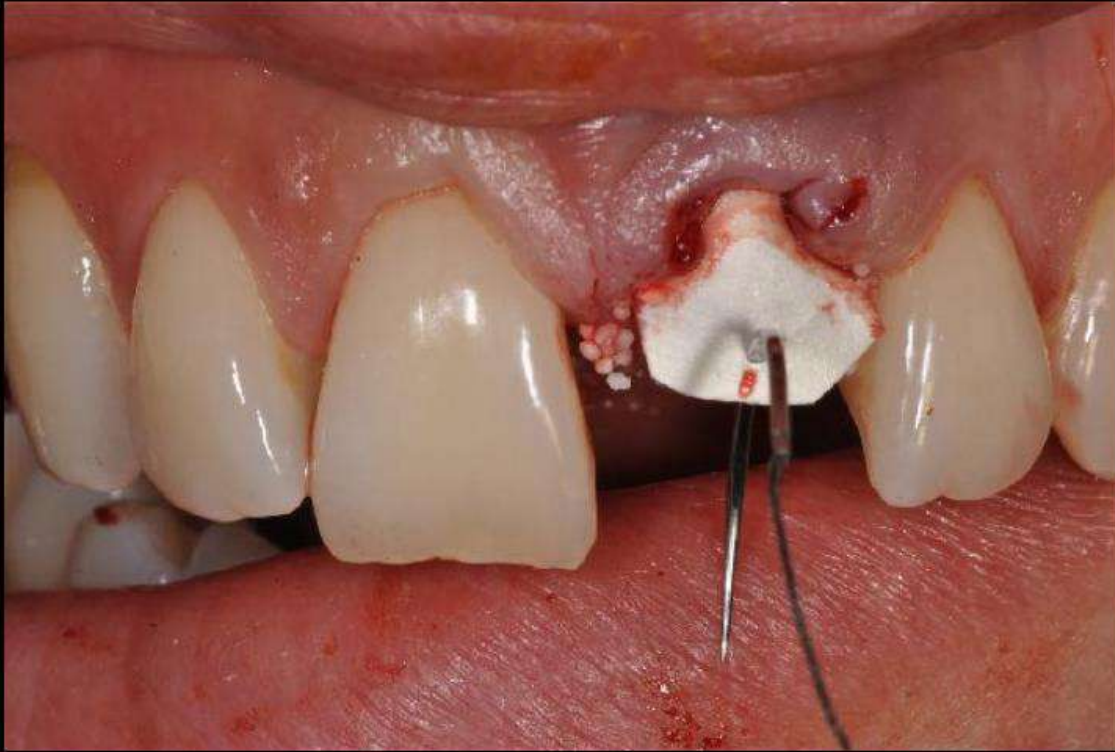


Dr. João Gaspar

Dr. João Gaspar



www.medbone.eu

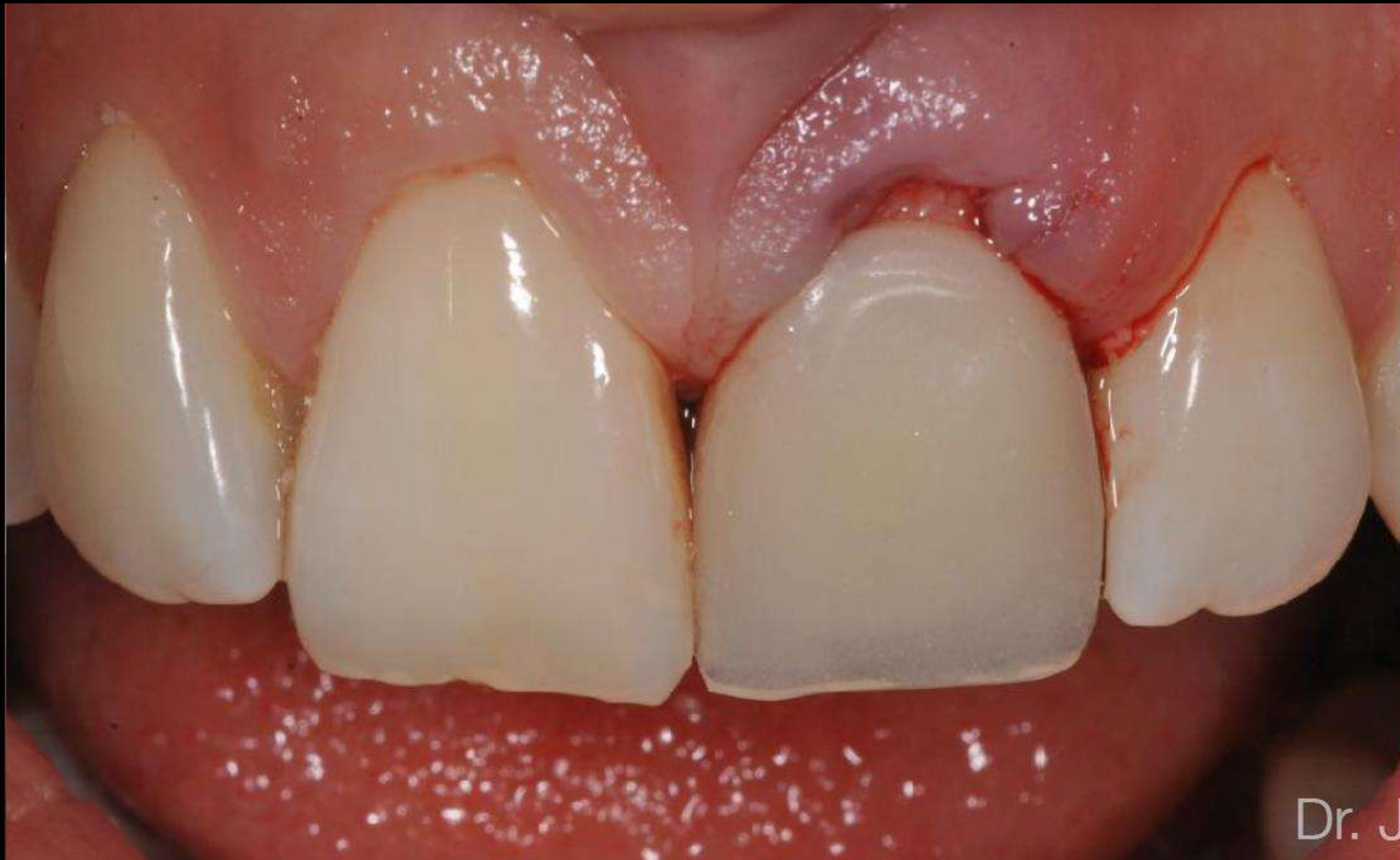

Dr. João Gaspar

Dr. João Gaspar



www.medbone.eu

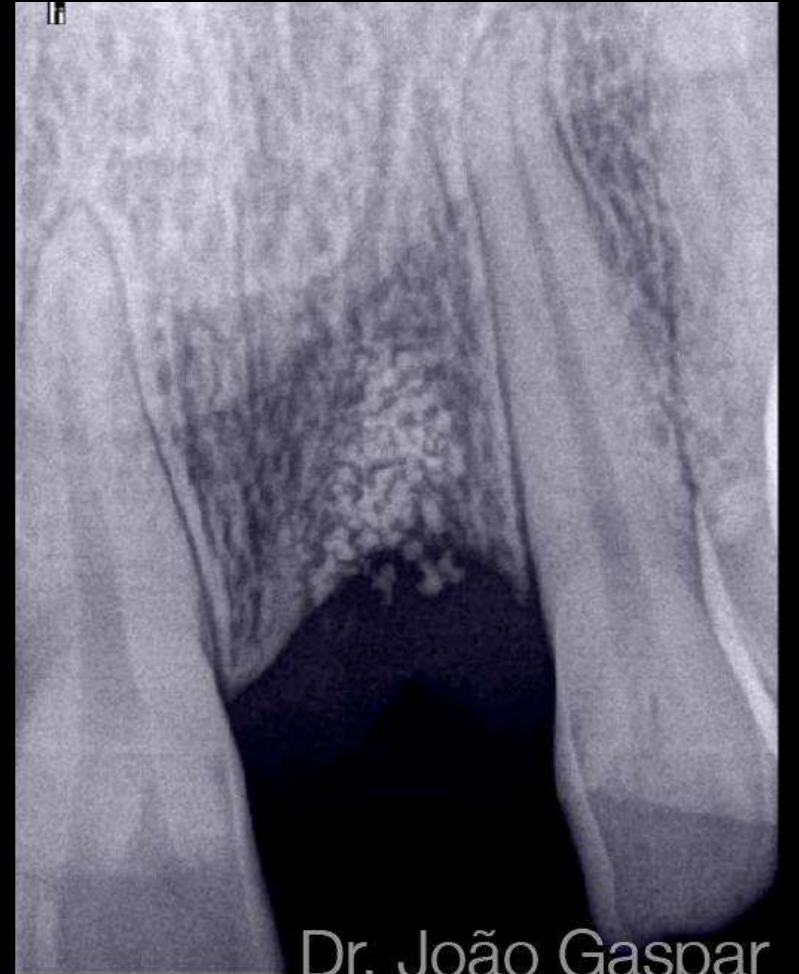
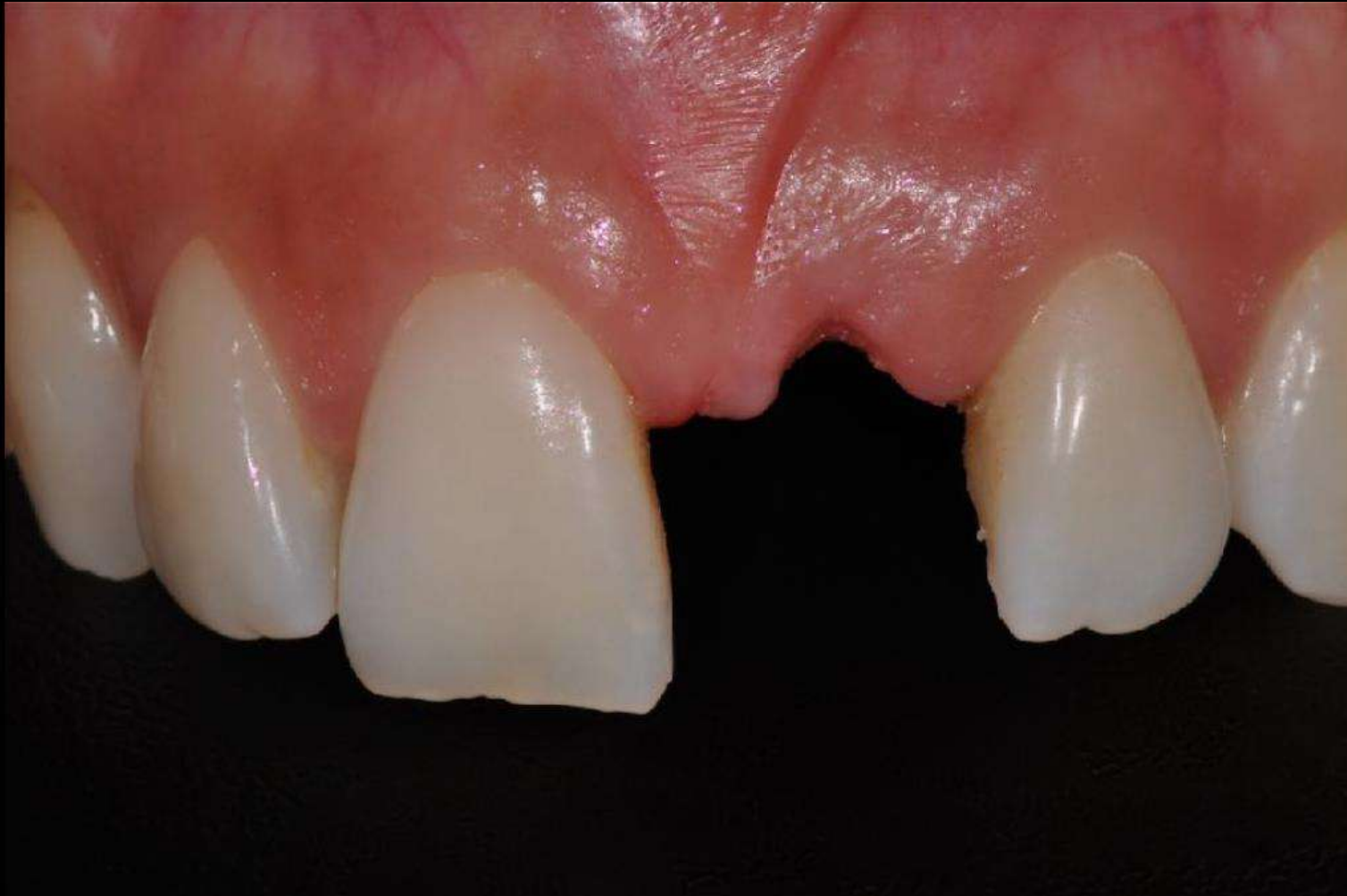
Dr. João Gaspar

Dr. João Gaspar



www.medbone.eu

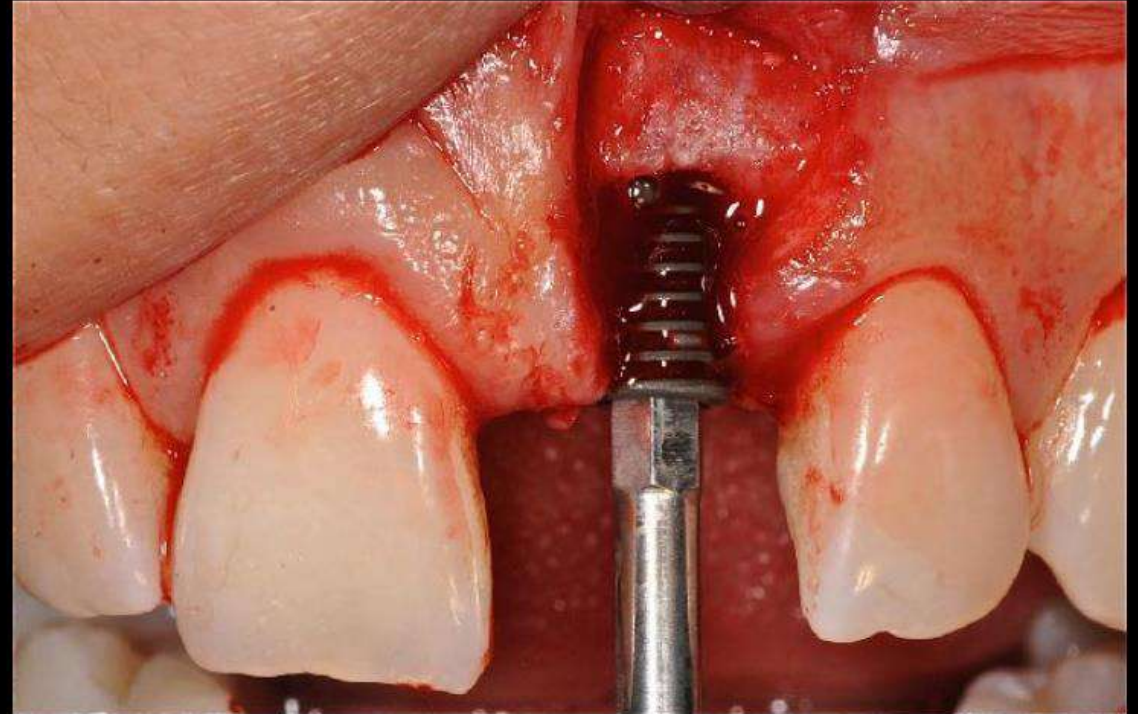
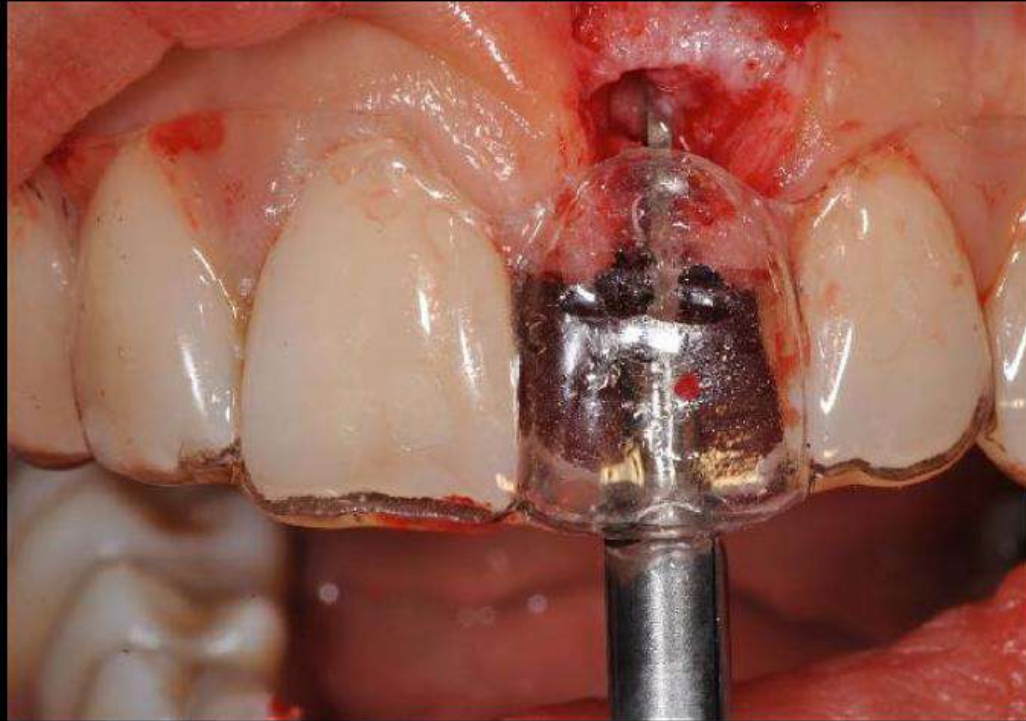


Dr. João Gaspar

Dr. João Gaspar



www.medbone.eu

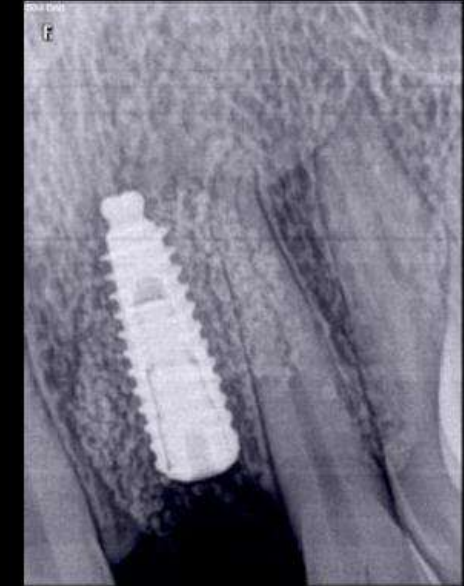
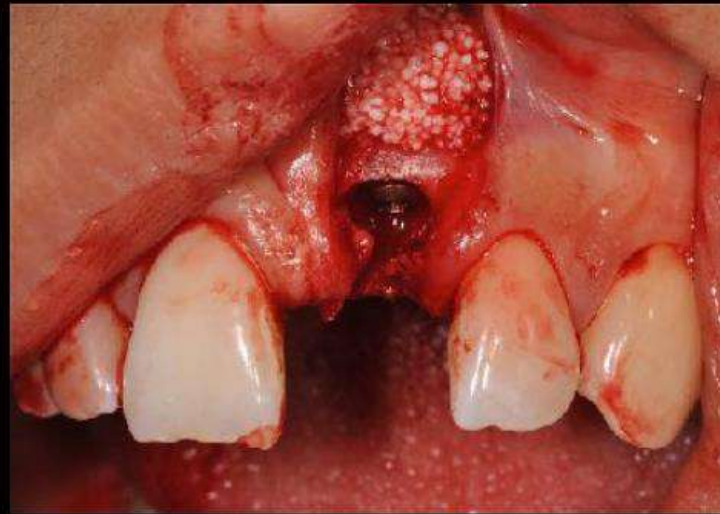
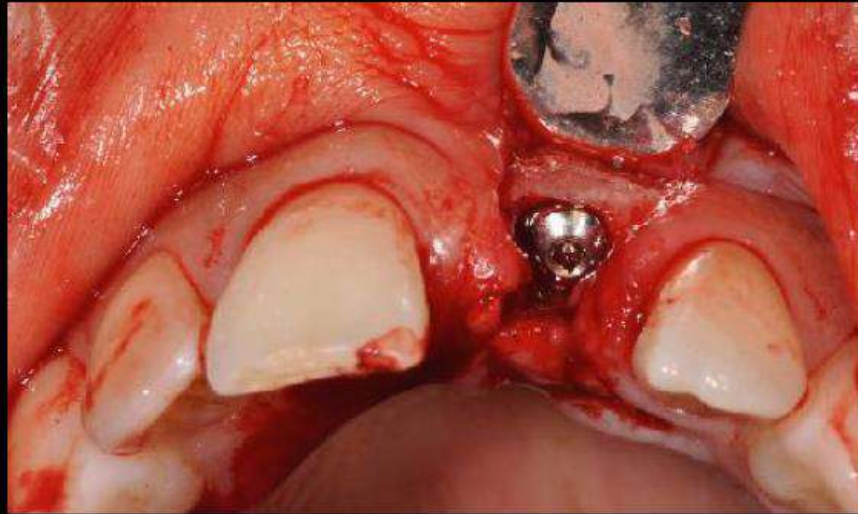


Dr. João Gaspar

Dr. João Gaspar



www.medbone.eu

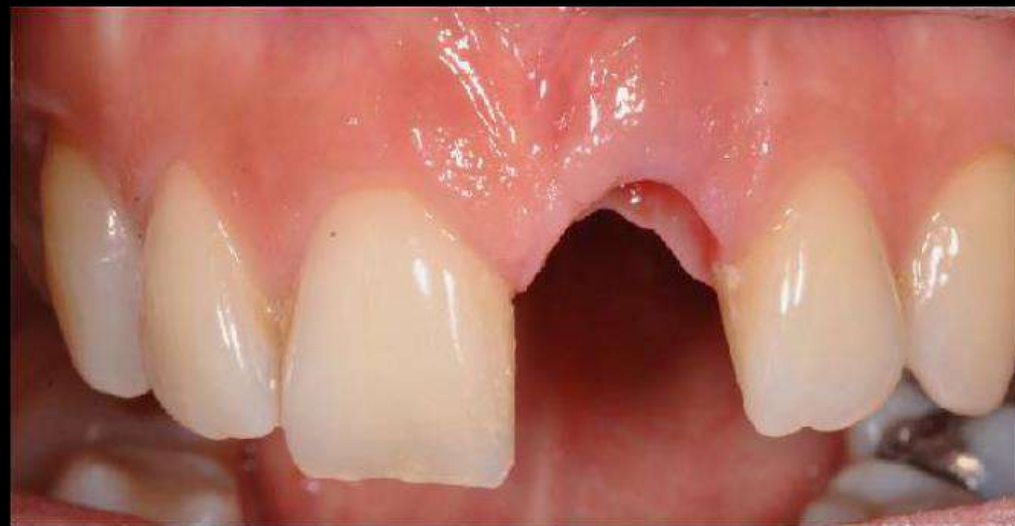
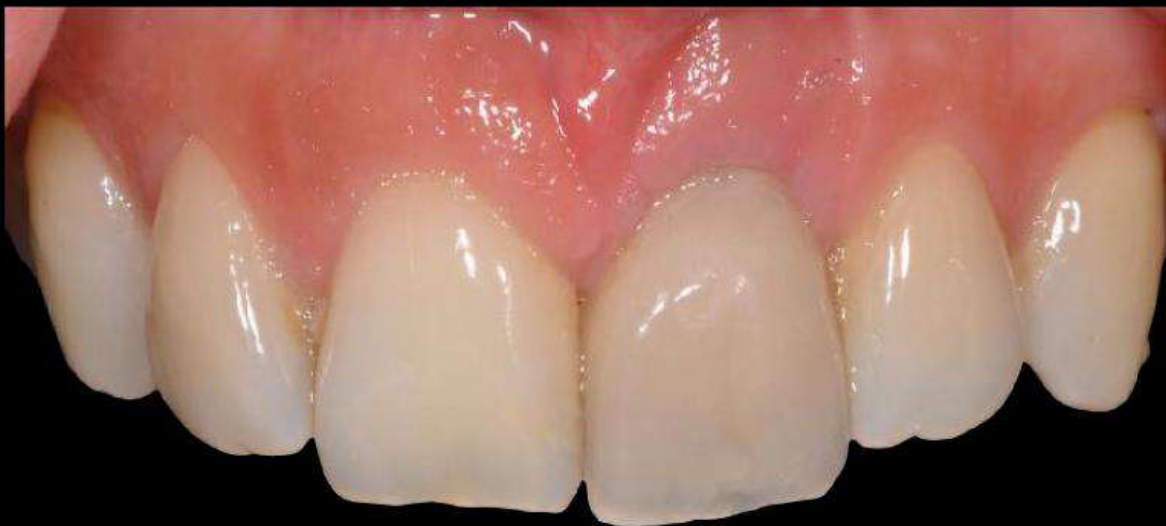
Dr. João Gaspar

Dr. João Gaspar



www.medbone.eu



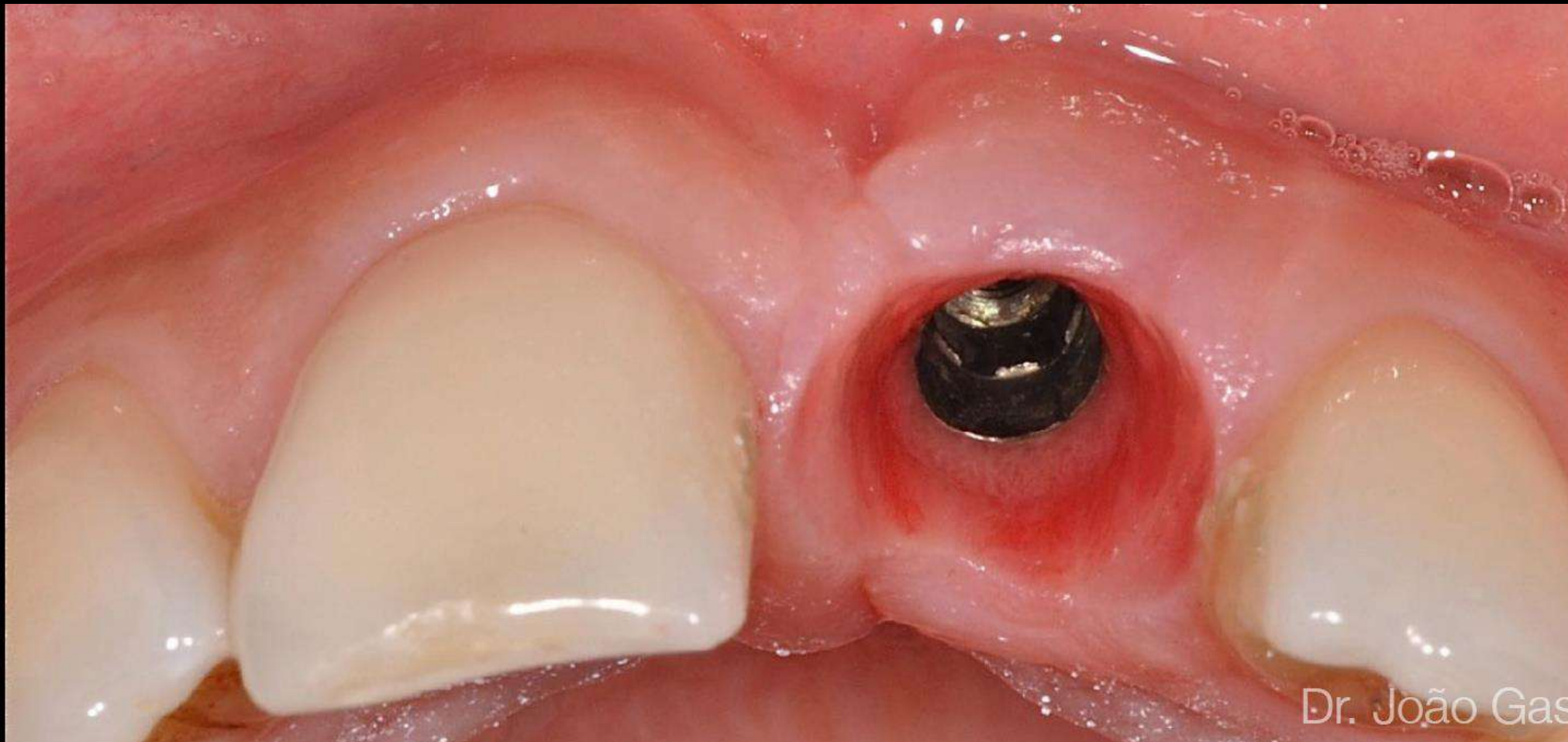
3 months

Dr. João Gaspar

Dr. João Gaspar



www.medbone.eu

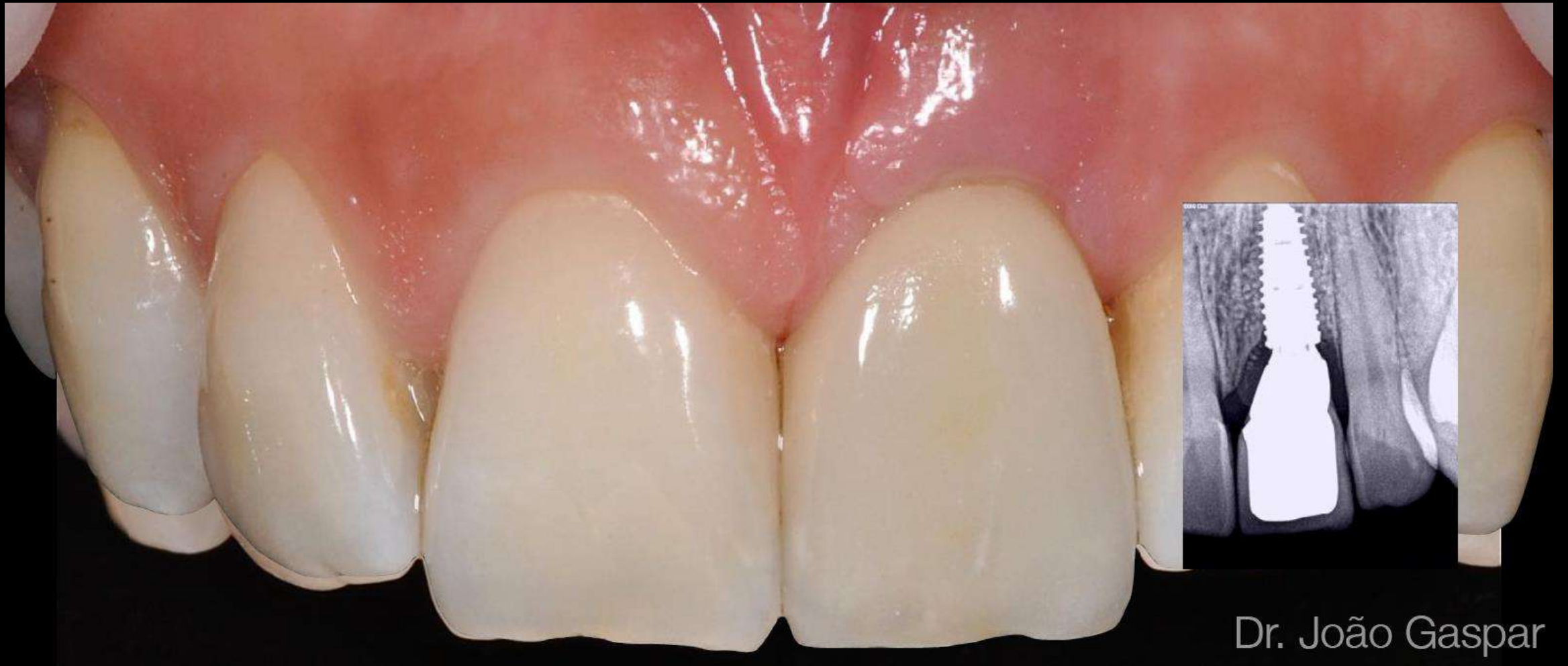

Dr. João Gaspar

Dr. João Gaspar



www.medbone.eu

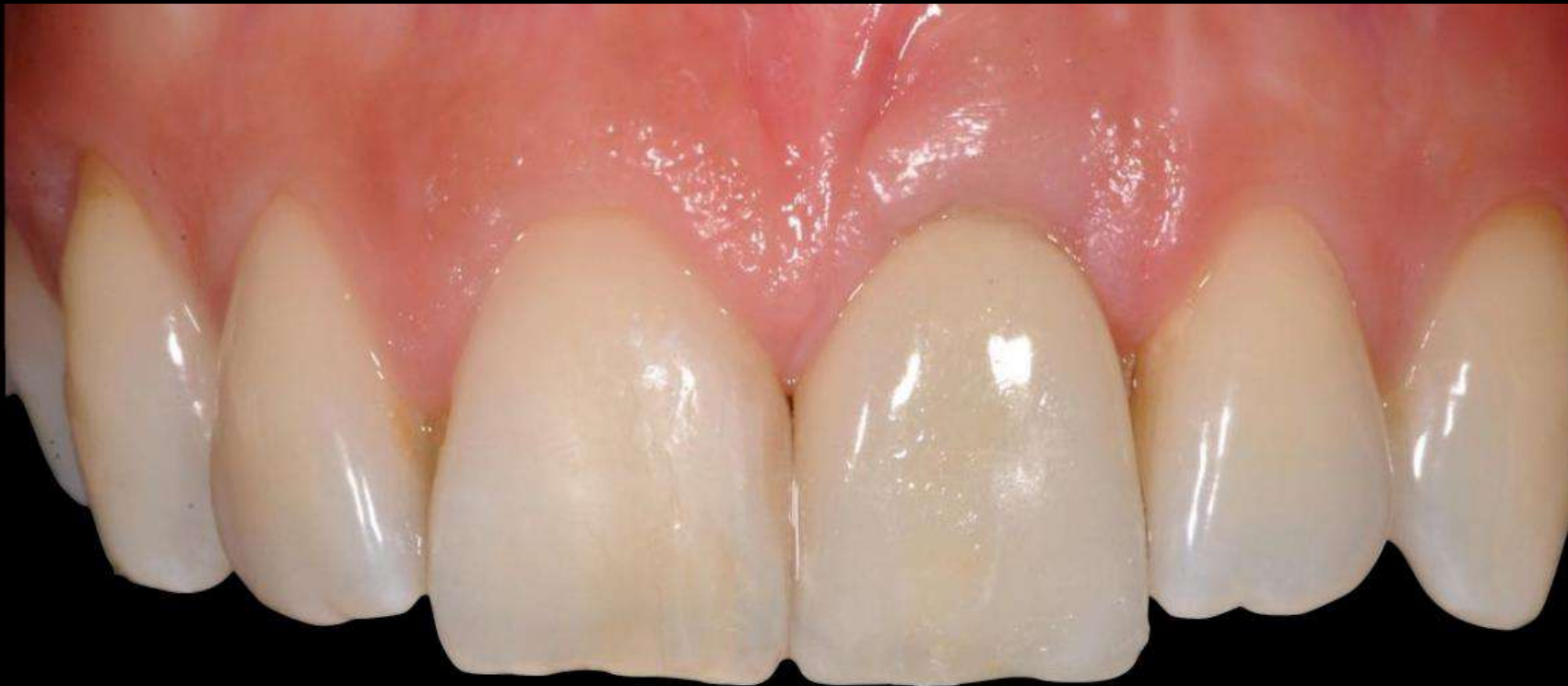

Dr. João Gaspar

Dr. João Gaspar



www.medbone.eu



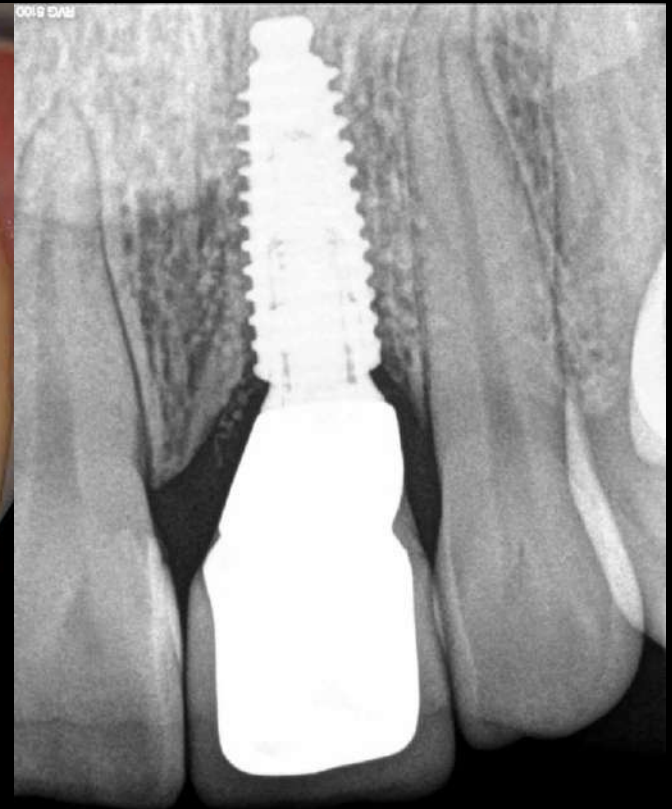
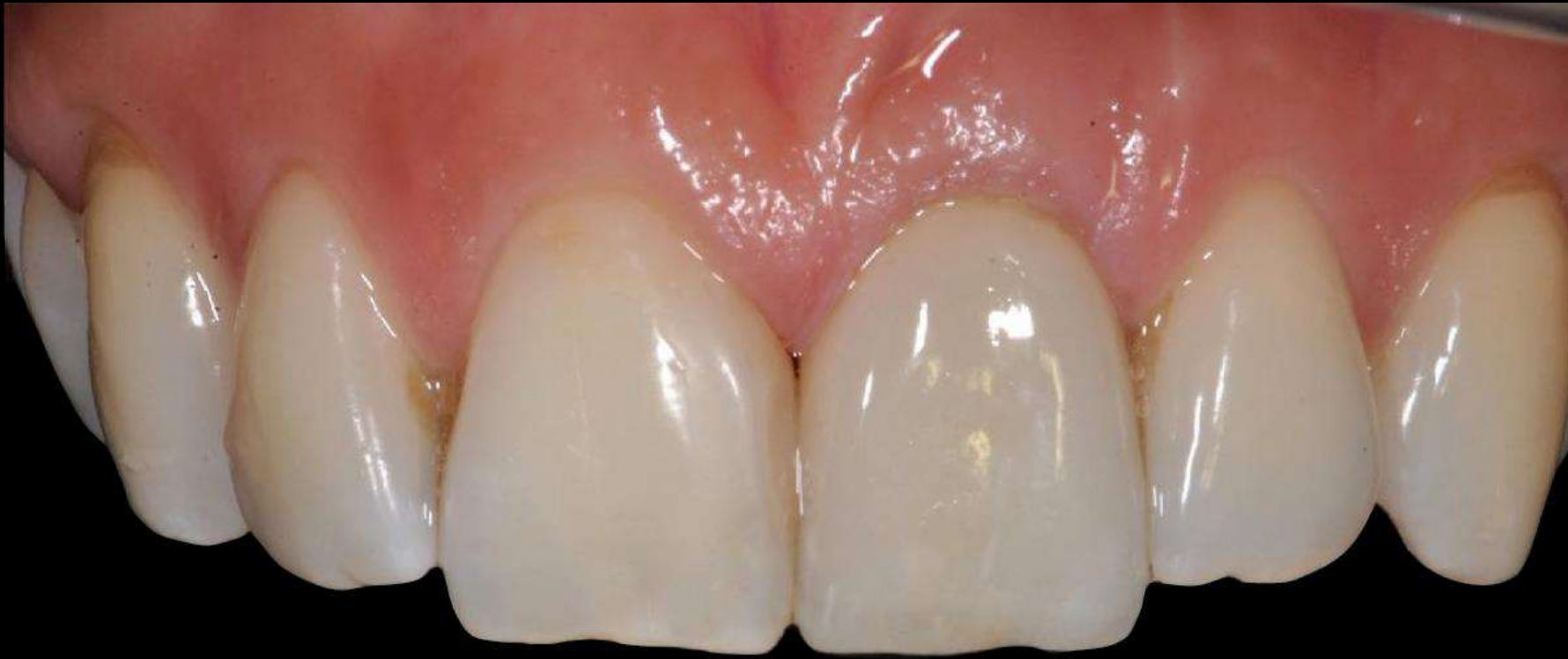2 months

Dr. João Gaspar

Dr. João Gaspar



www.medbone.eu



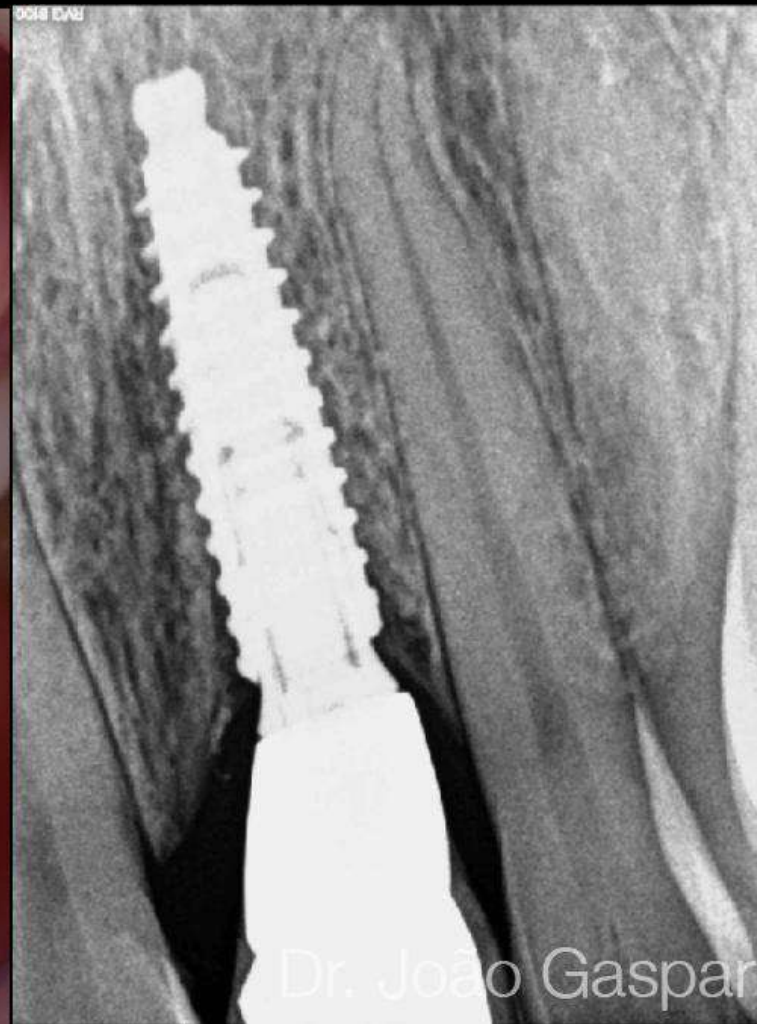
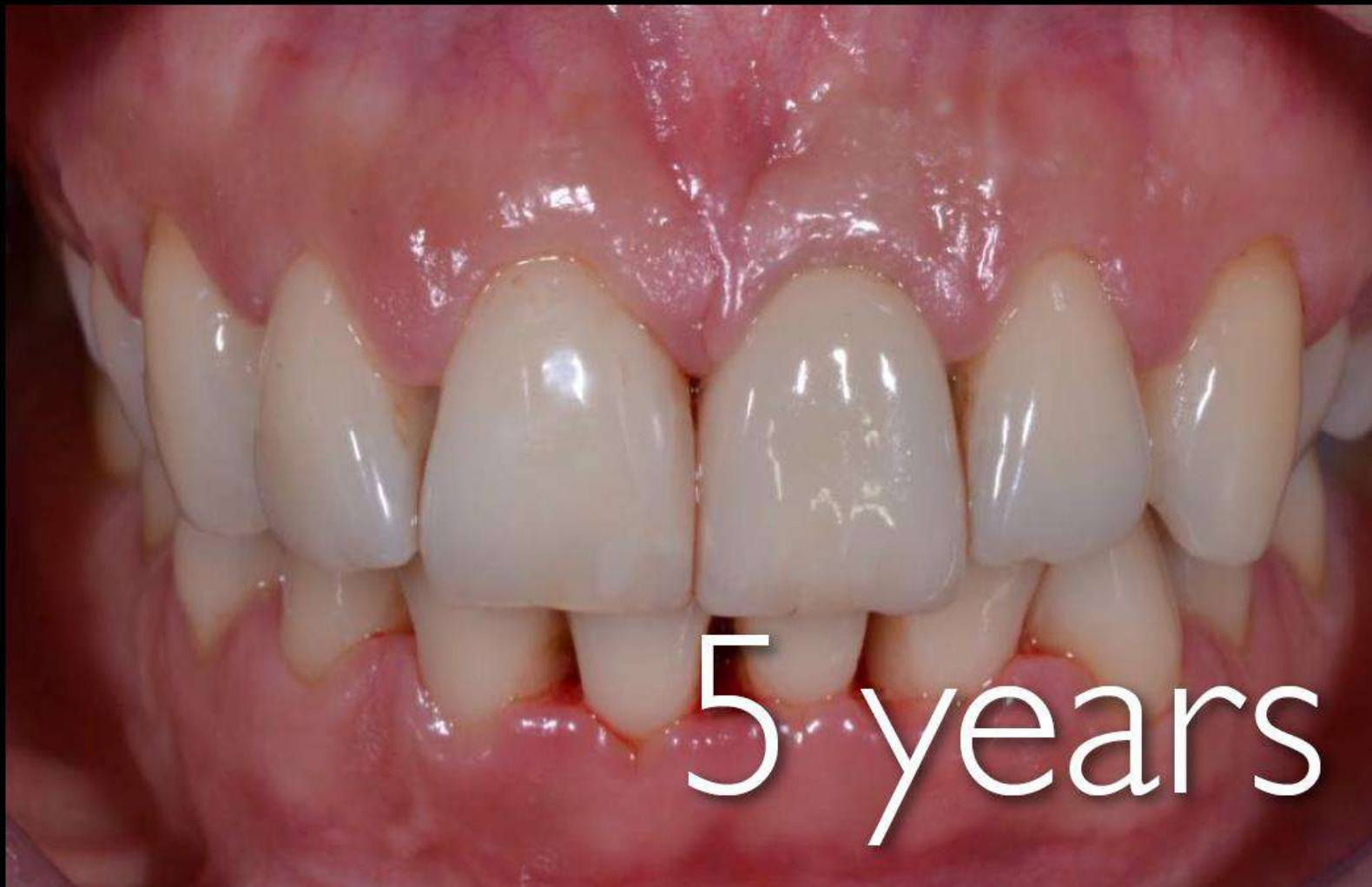2 years

Dr. João Gaspar

Dr. João Gaspar



www.medbone.eu



Dr. João Gaspar



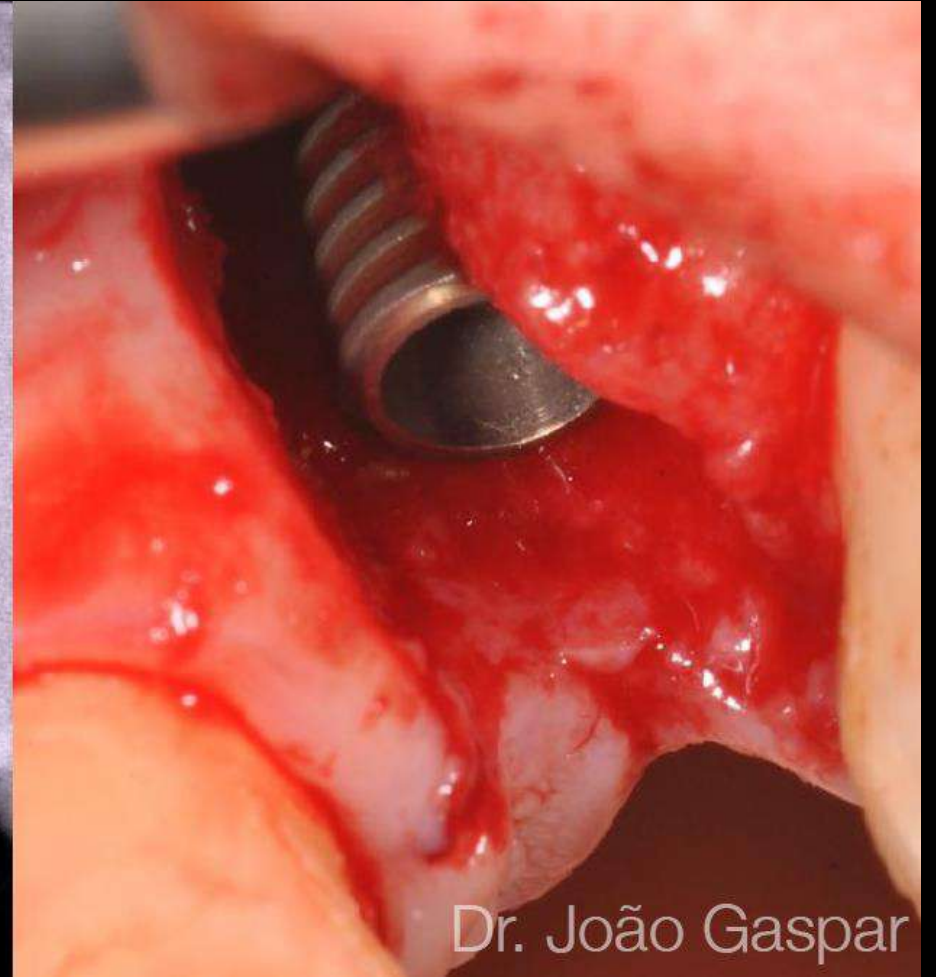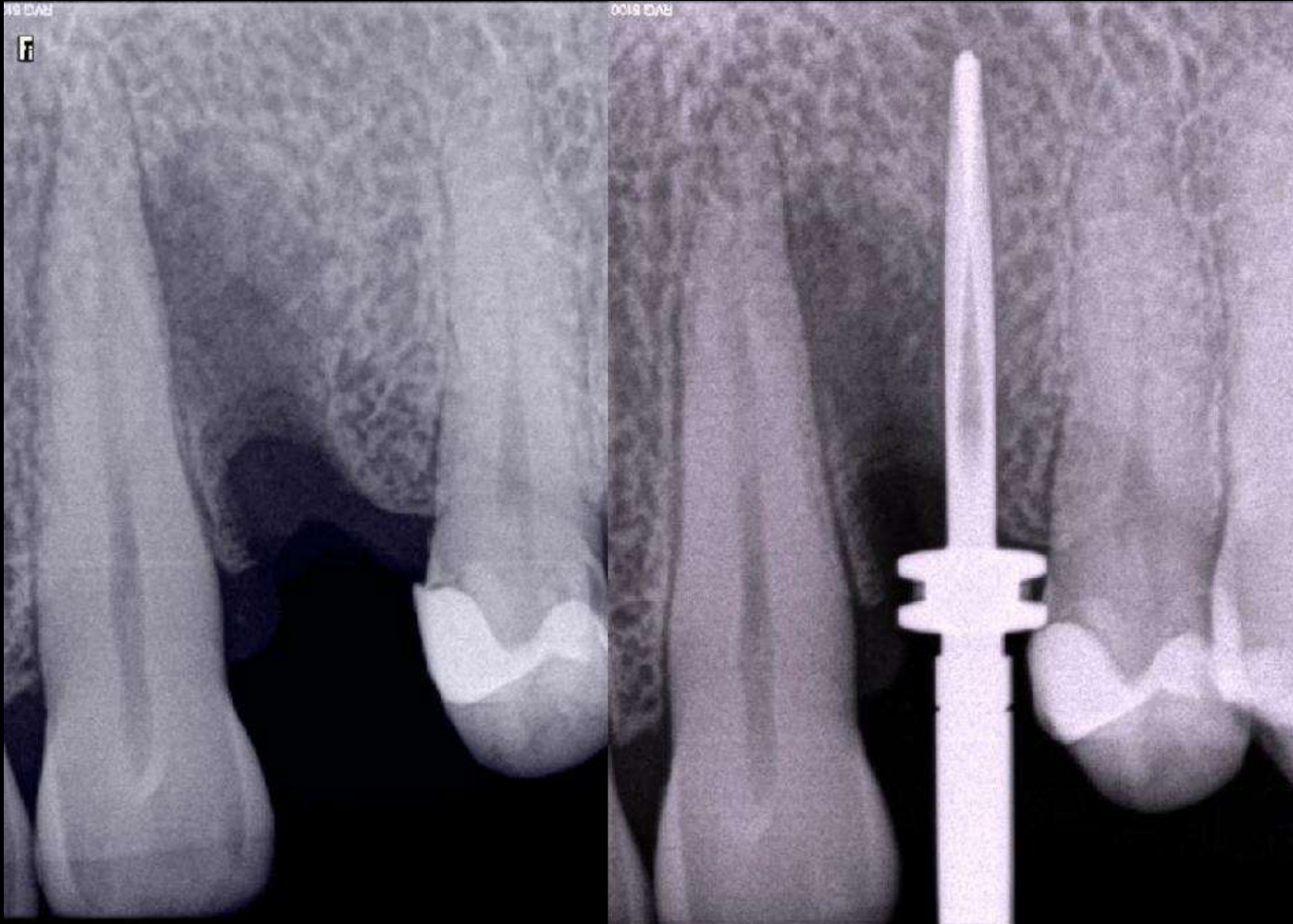
www.medbone.eu



Medbone®
BIOMATERIALS

CASE 8

adbone® TCP

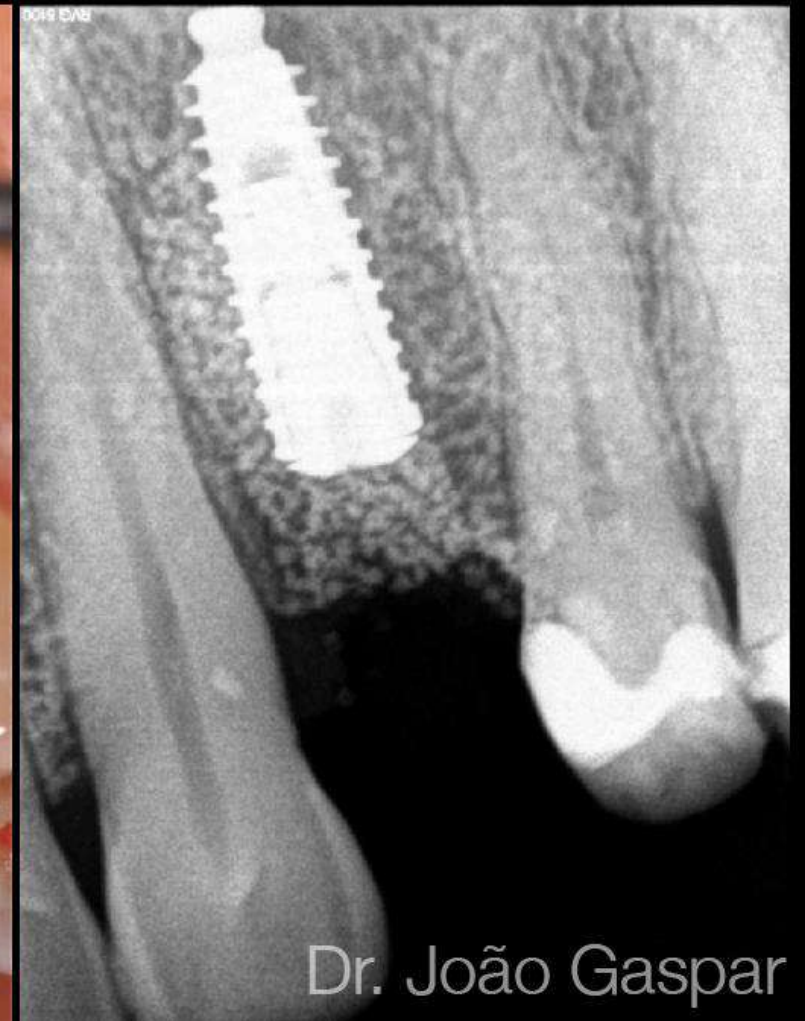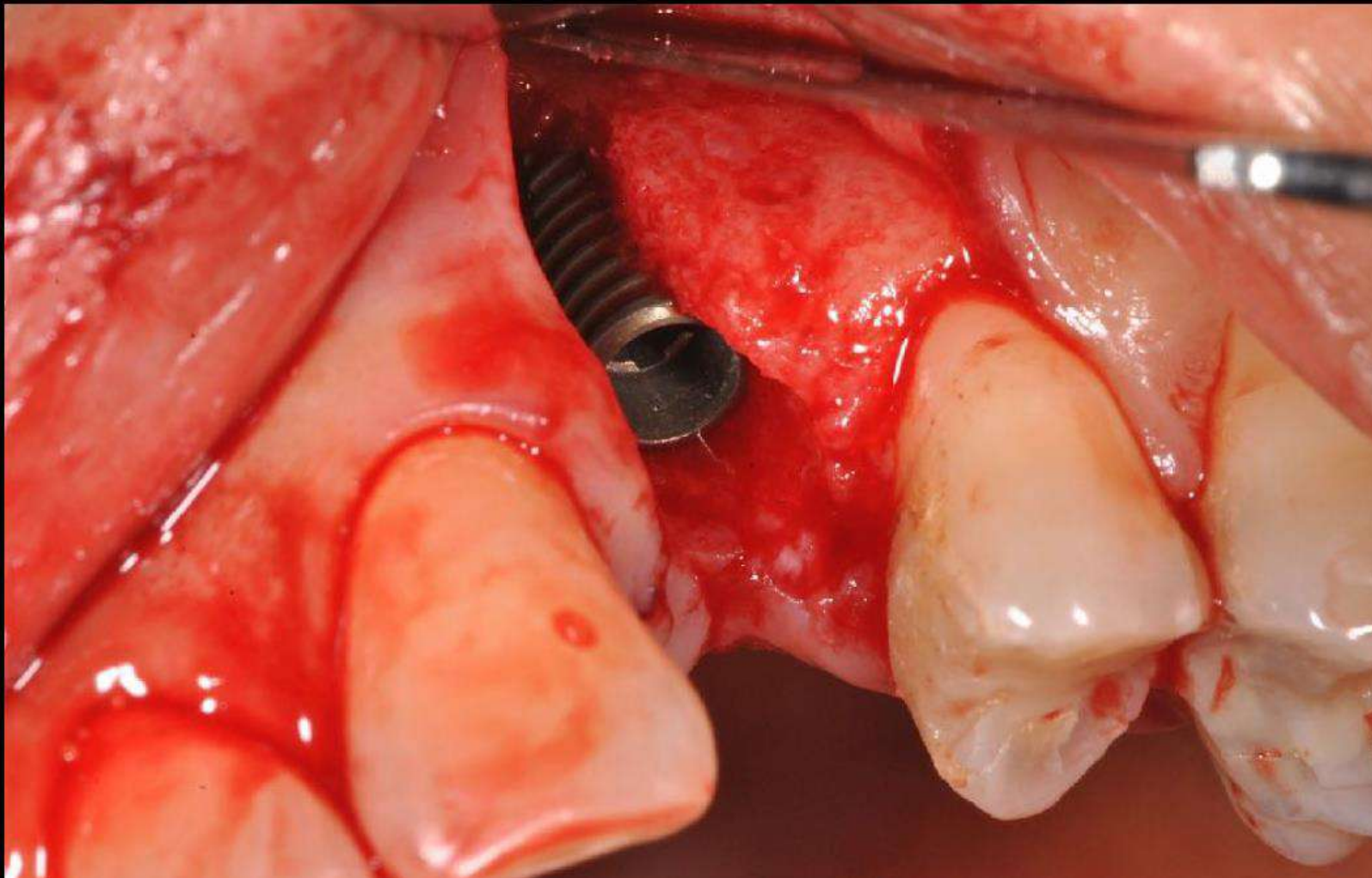


Dr. João Gaspar

Dr. João Gaspar



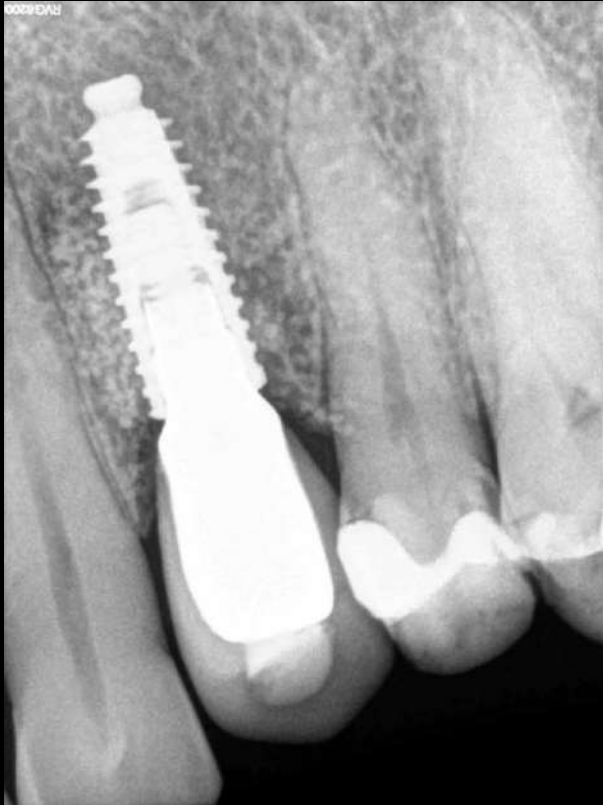www.medbone.eu



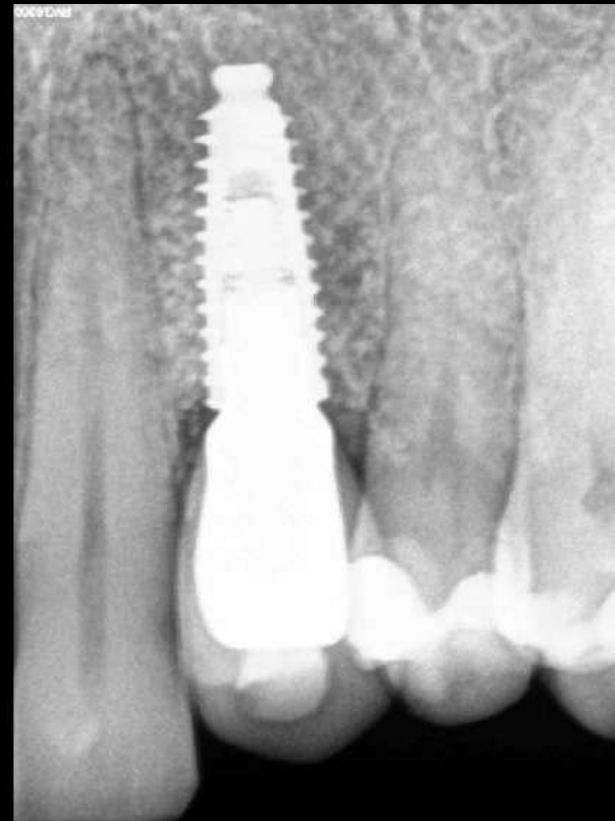
Dr. João Gaspar



www.medbone.eu



2 anos depois



5 anos depois

Dr. João Gaspar



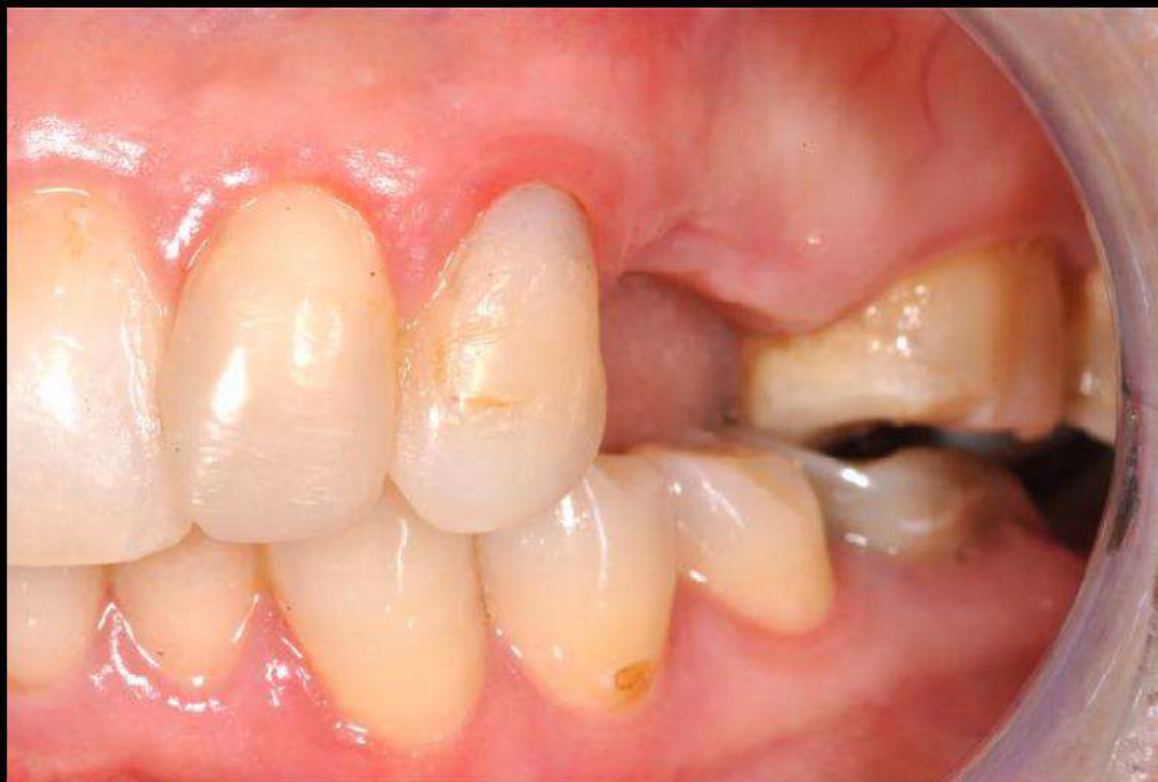www.medbone.eu



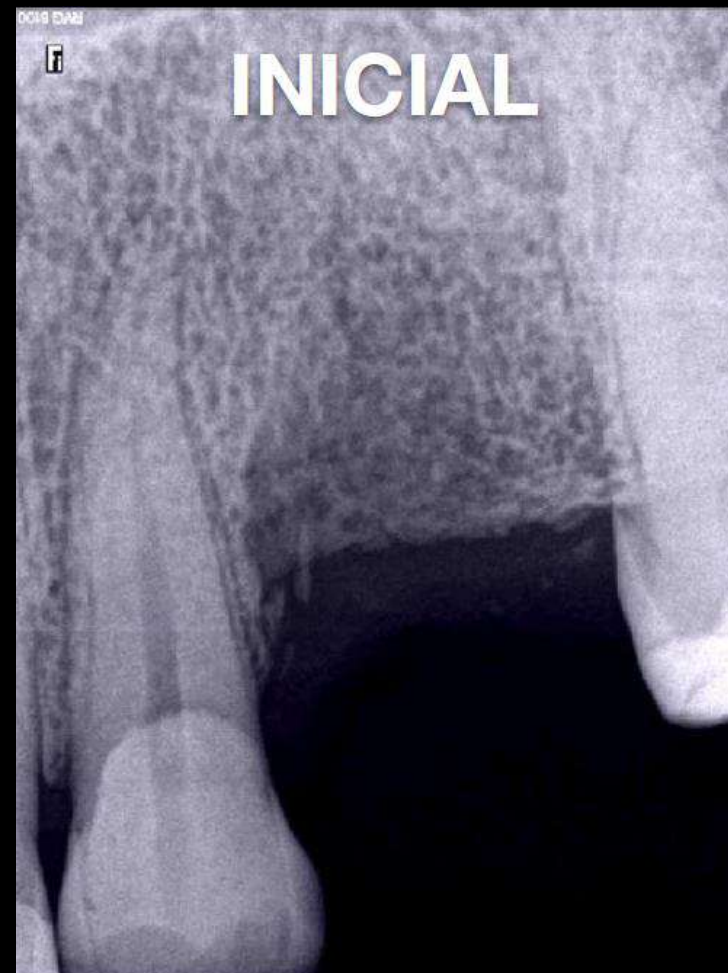Medbone®
BIOMATERIALS

CASE 9

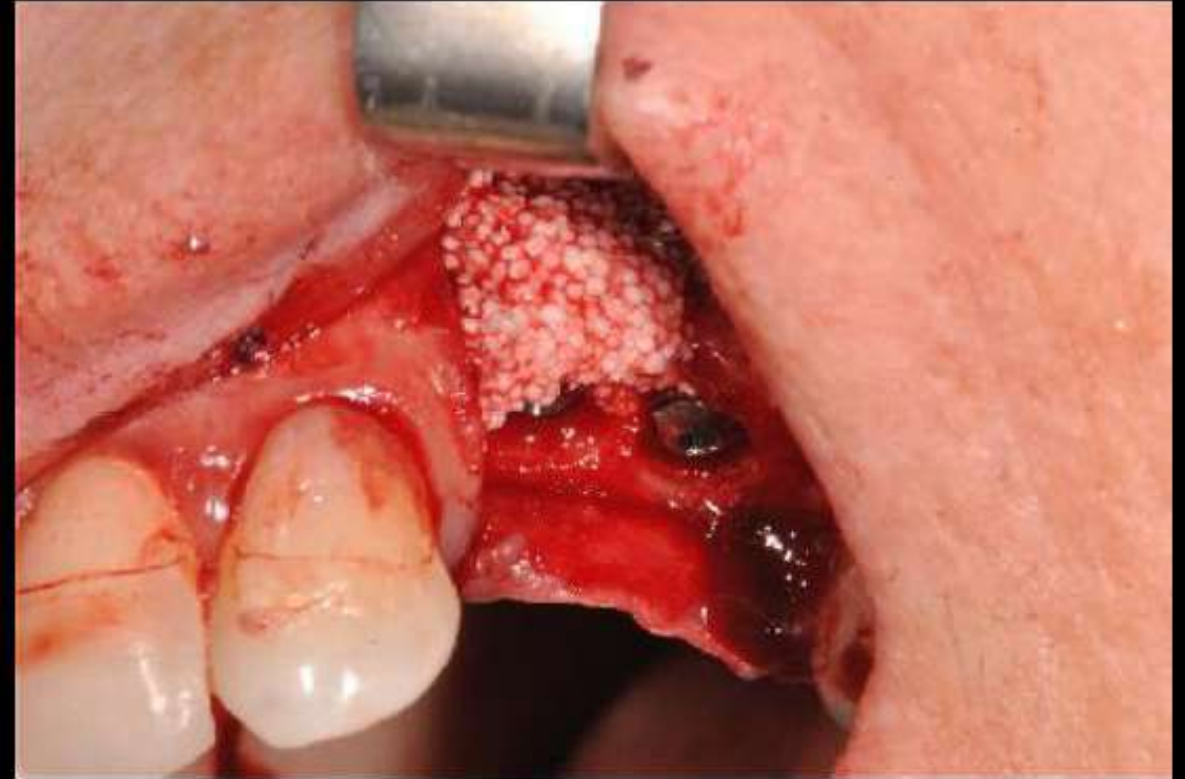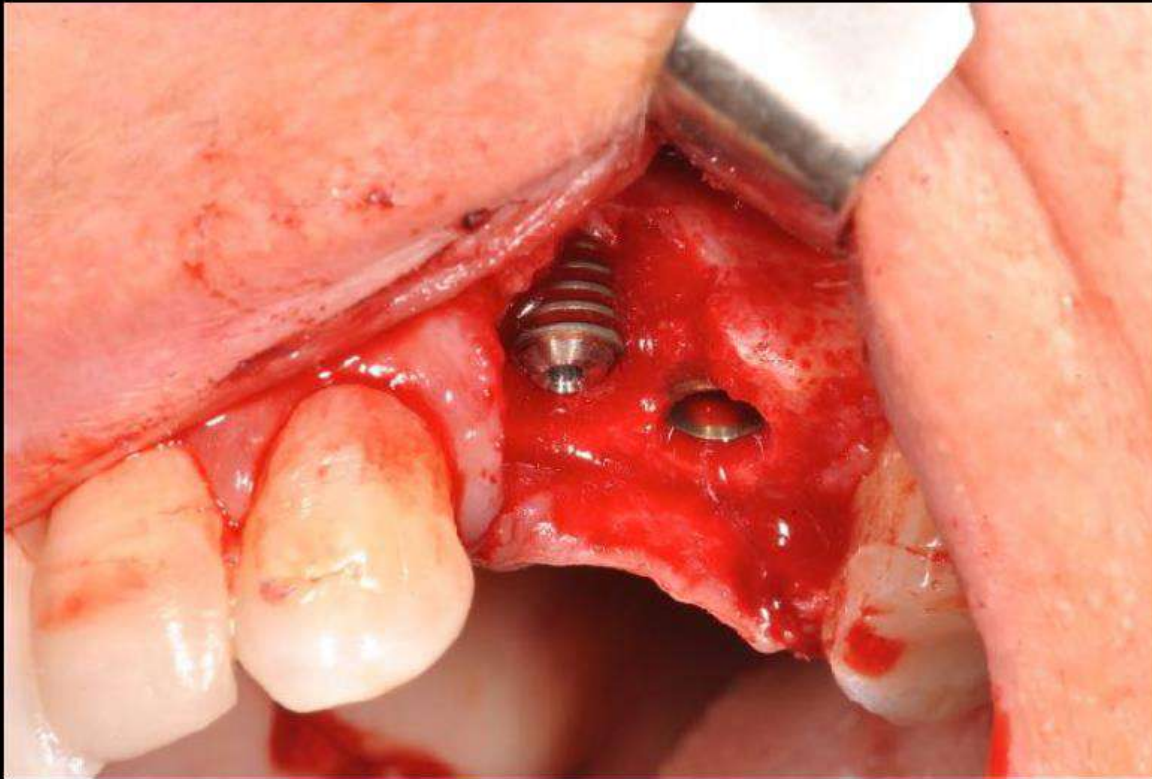
adbone® TCP



Dr. João Gaspar



Dr. João Gaspar

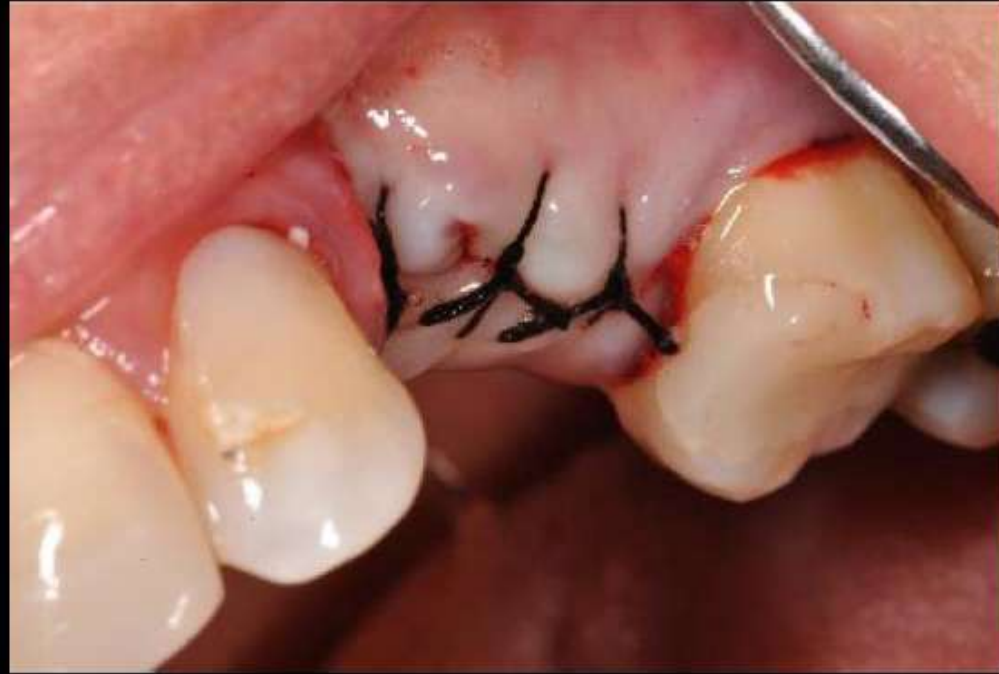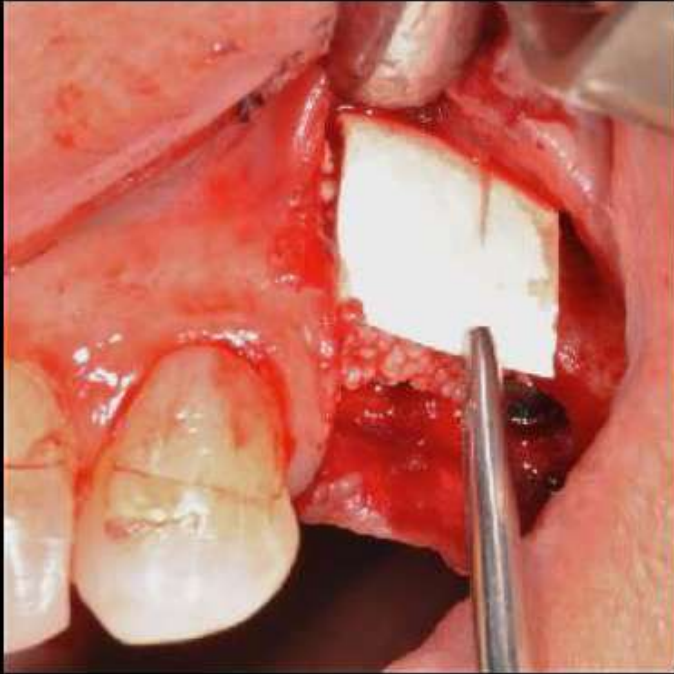


Dr. João Gaspar

Dr. João Gaspar



www.medbone.eu

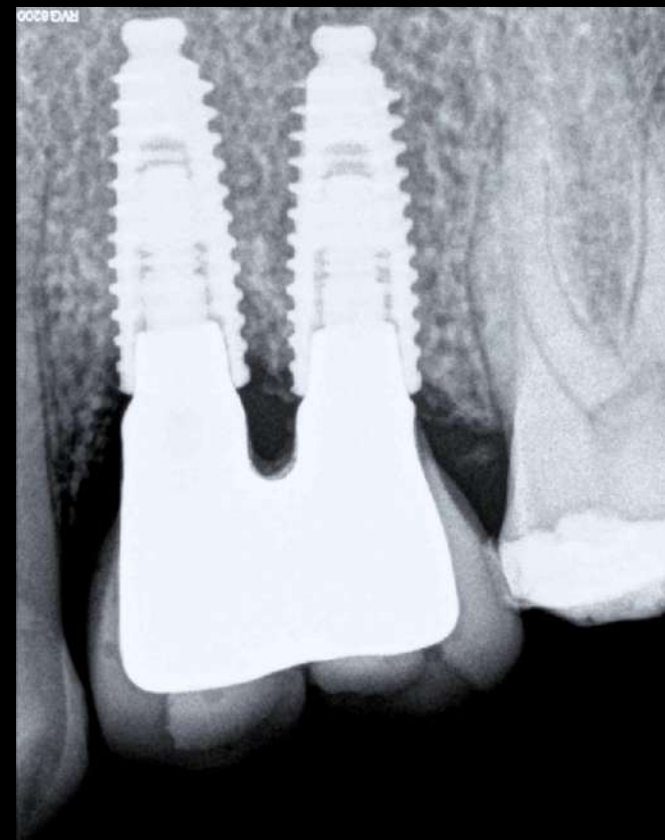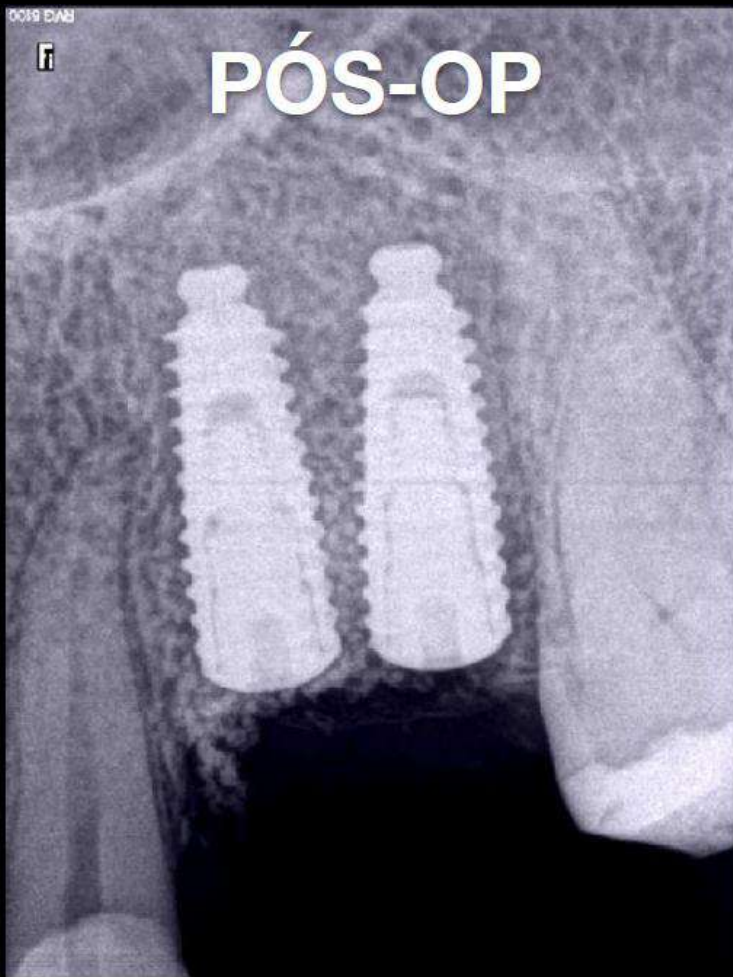


Dr. João Gaspar

Dr. João Gaspar



www.medbone.eu

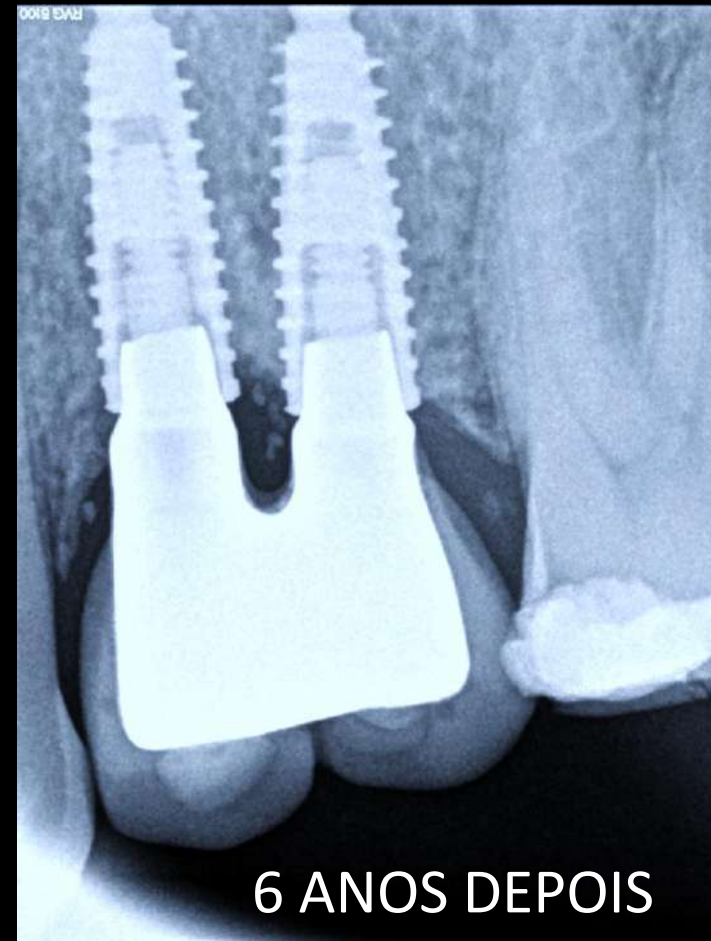
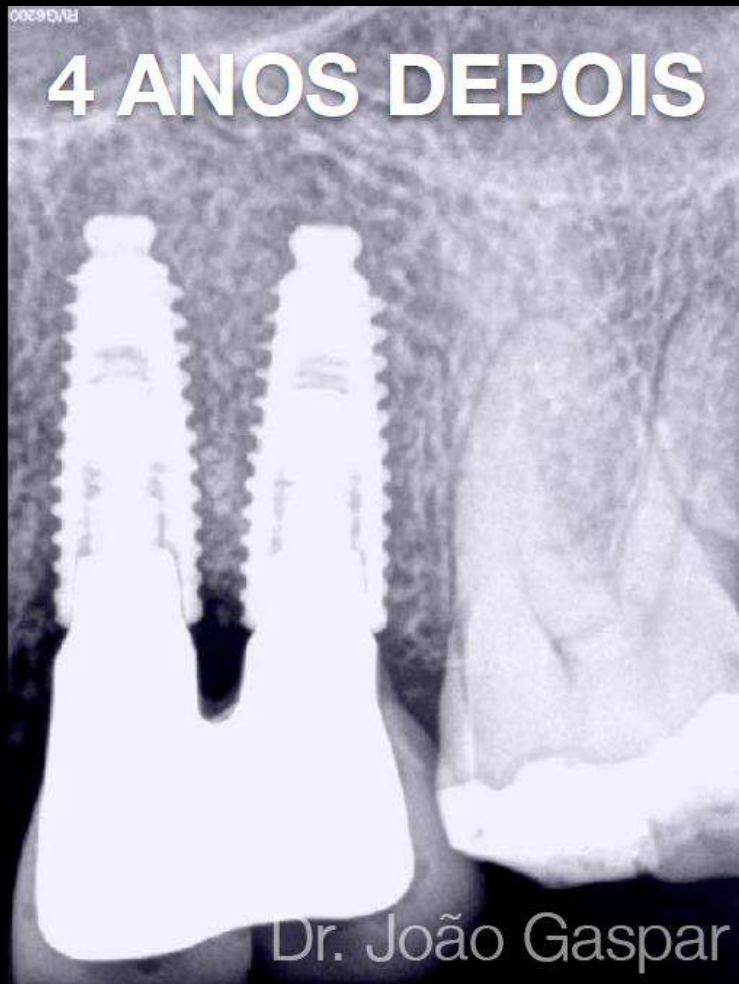


1,5 ANOS DEPOIS

Dr. João Gaspar



www.medbone.eu



Dr. João Gaspar



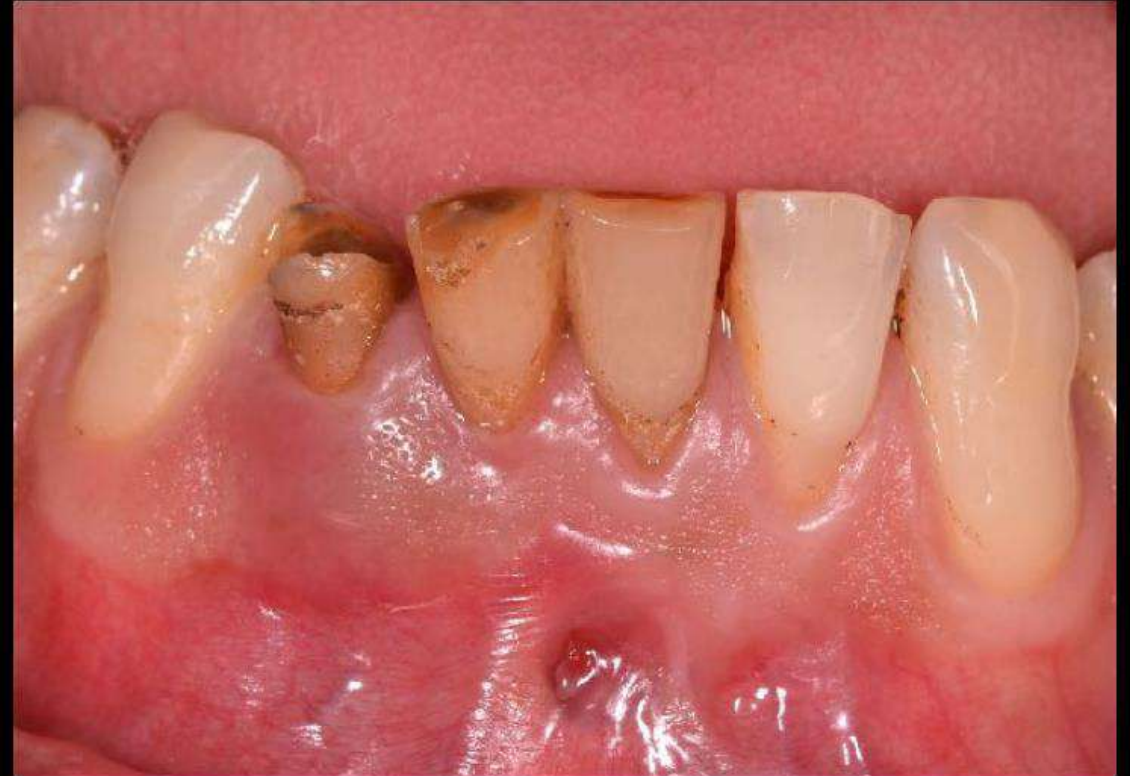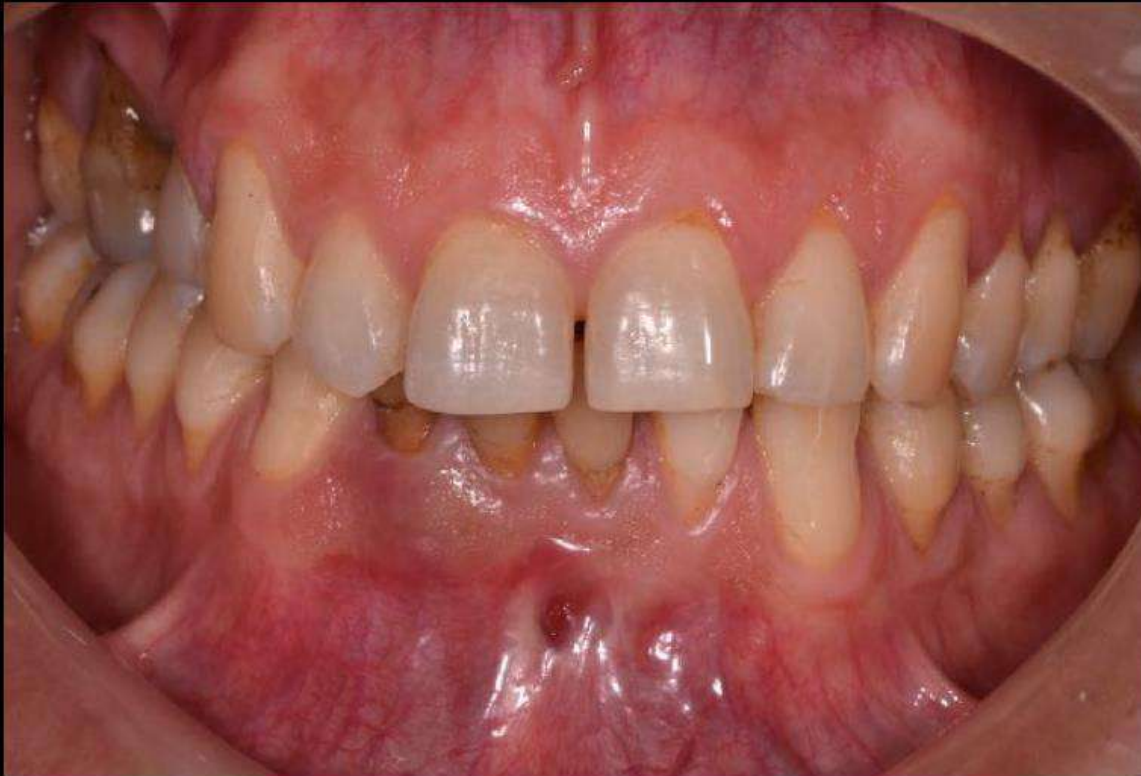www.medbone.eu



Medbone®
BIOMATERIALS

CASE 10

adbone®TCP



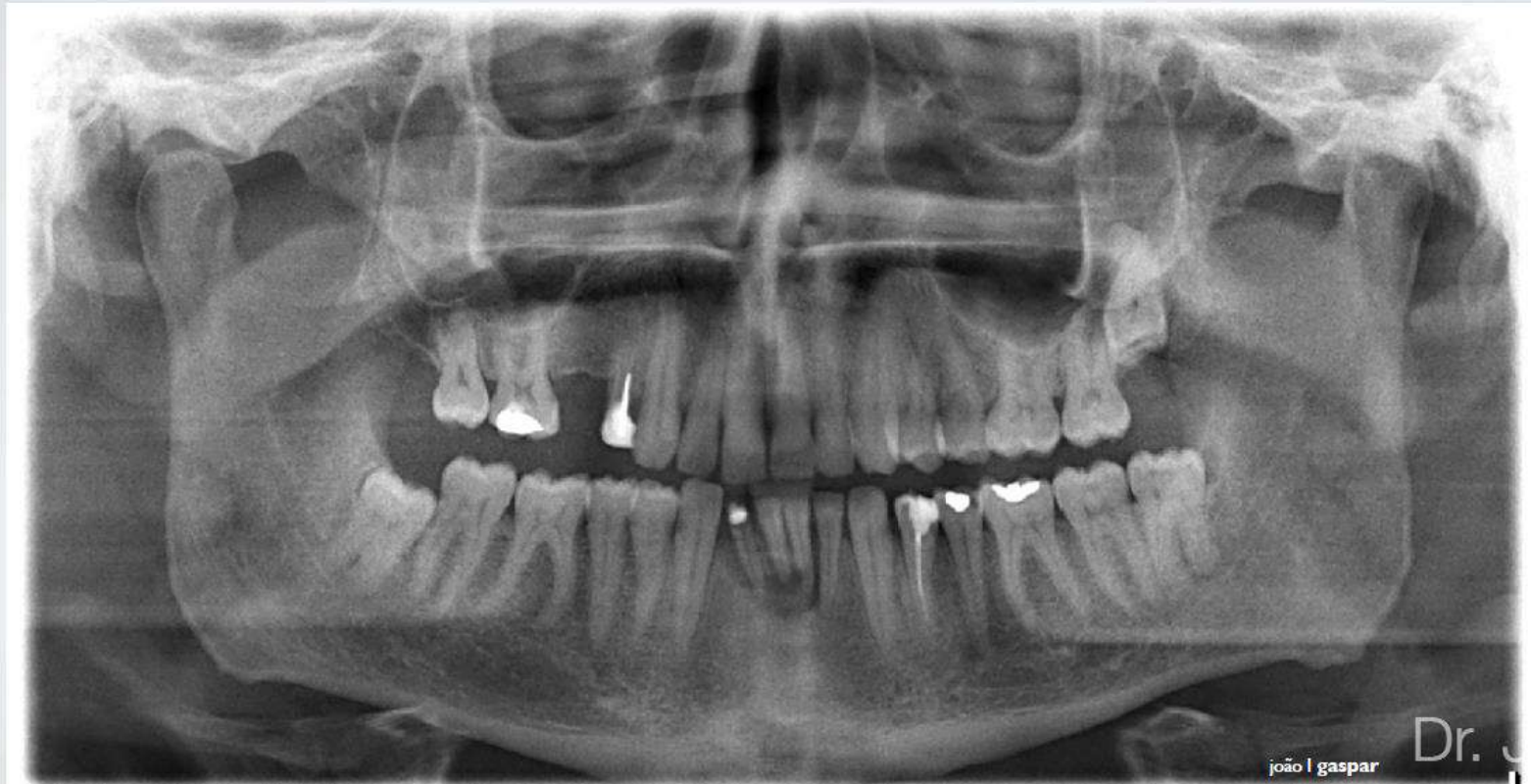Dr. João Gaspar

Dr. João Gaspar



www.medbone.eu

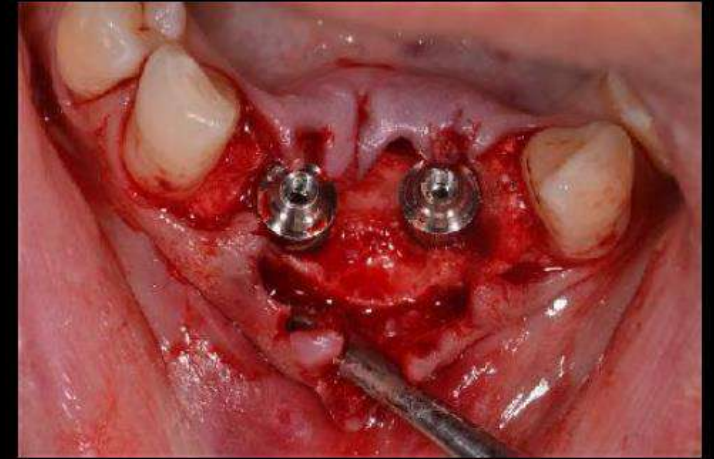
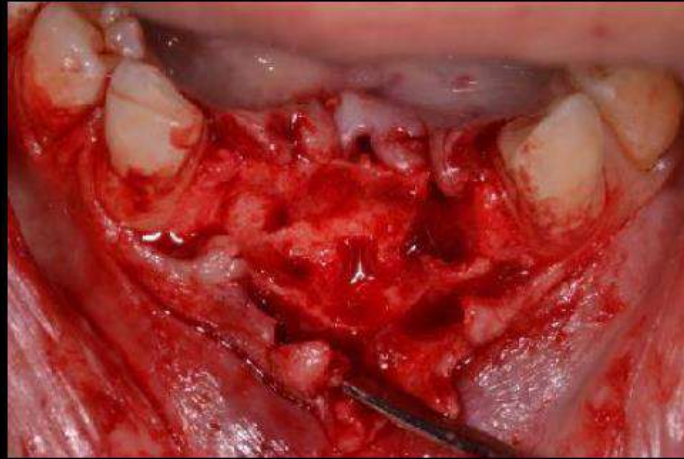
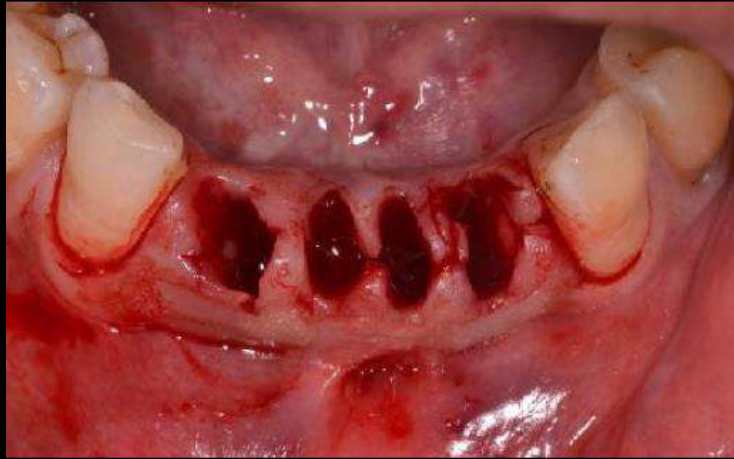
ORTOPANTOMOGRRAFIA



Dr. João Gaspar



www.medbone.eu

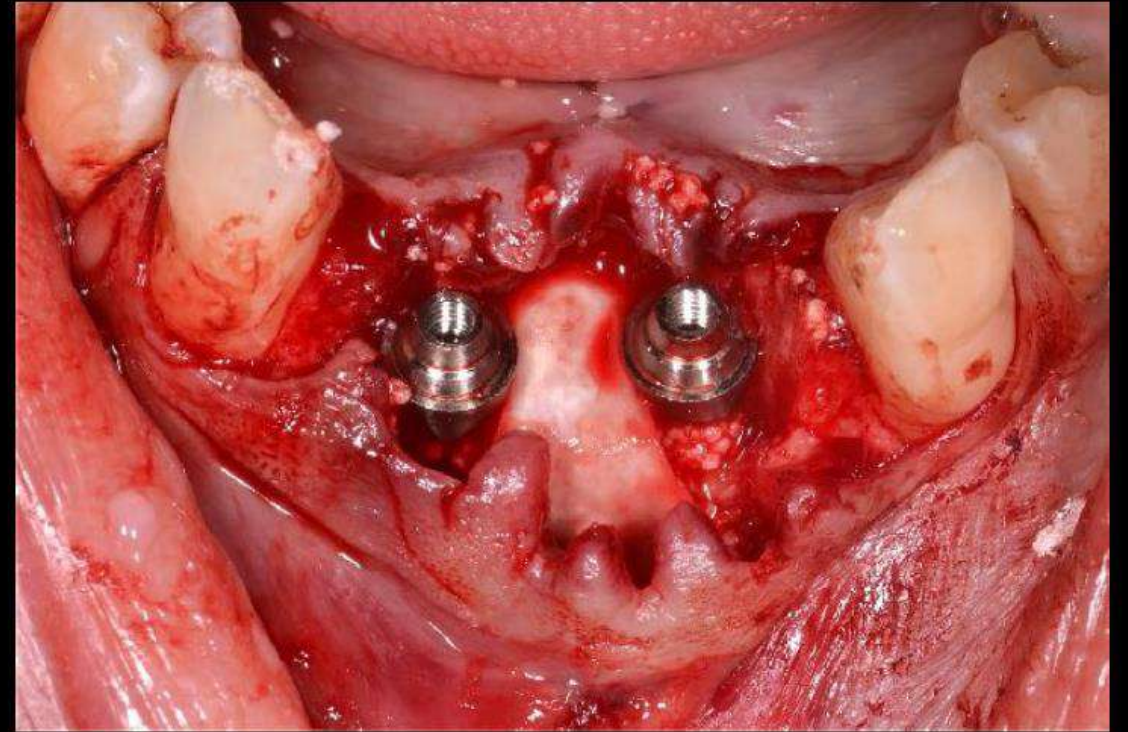
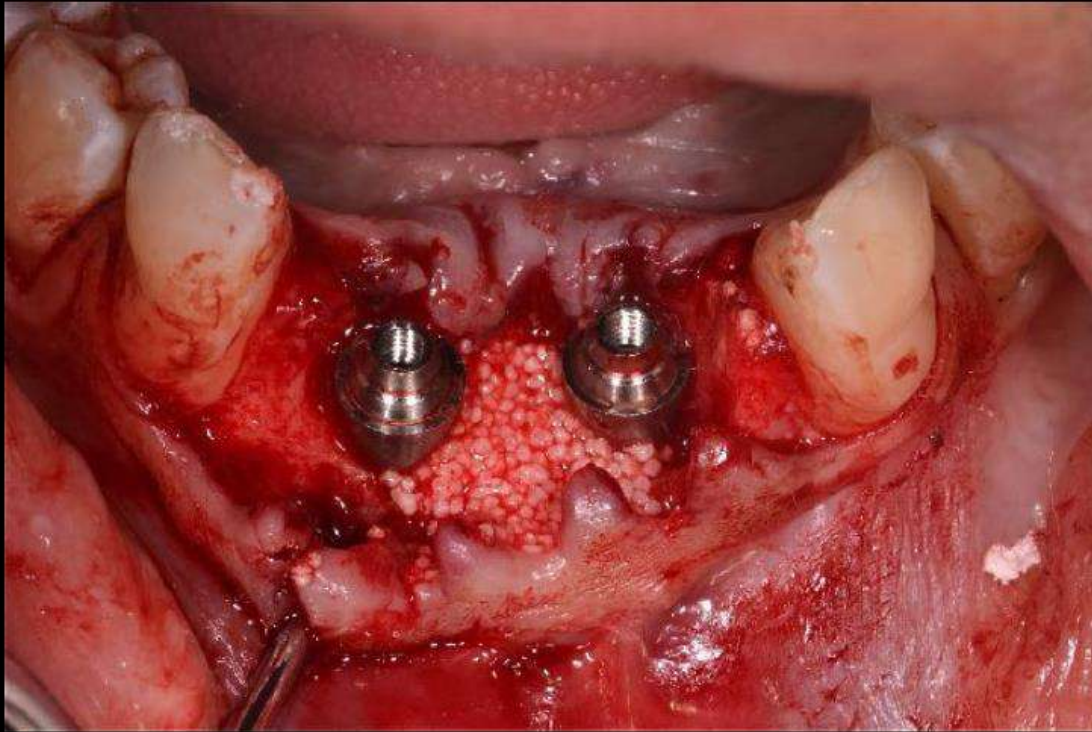


Dr. João Gaspar

Dr. João Gaspar



www.medbone.eu



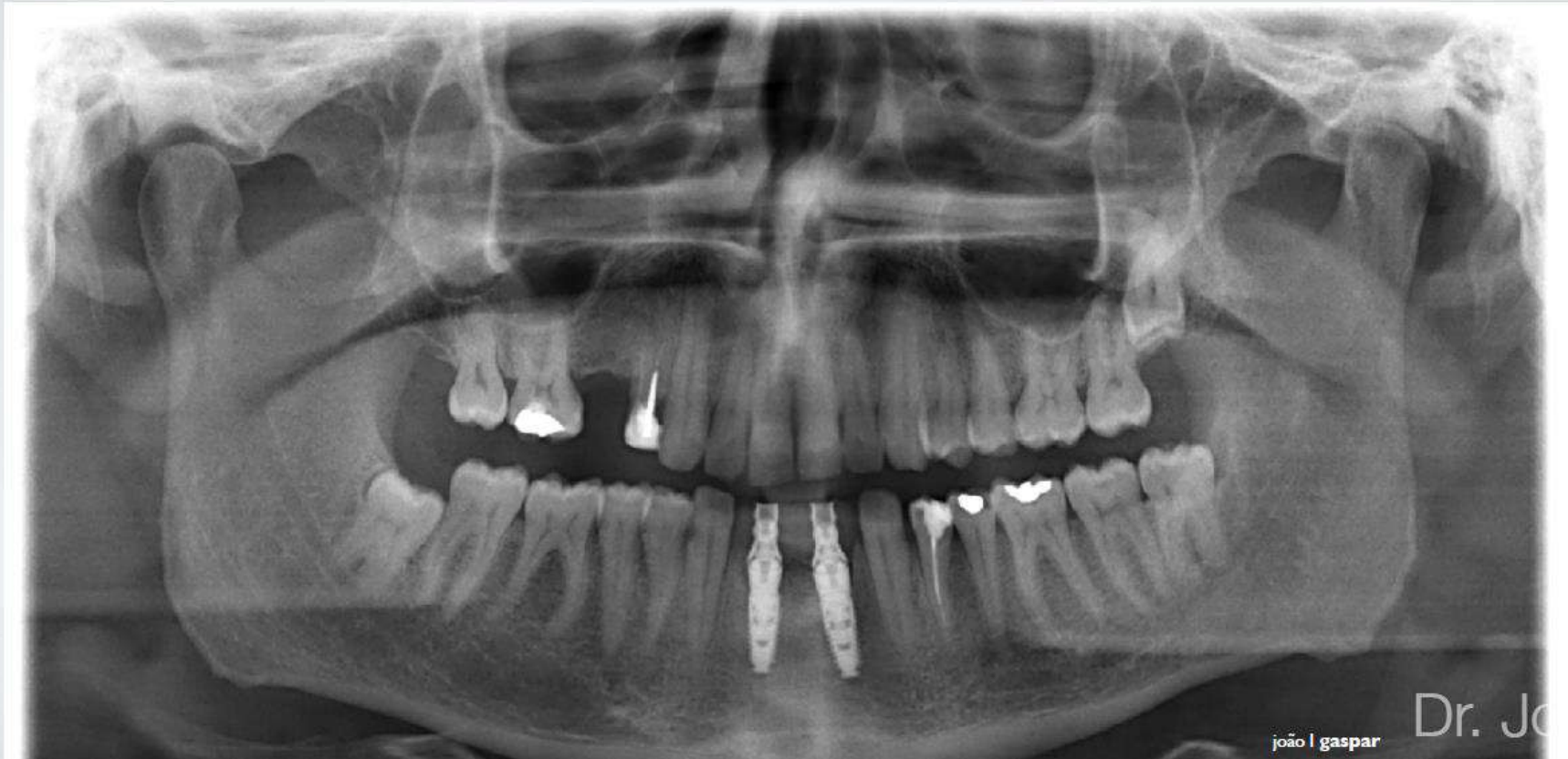Dr. João Gaspar

Dr. João Gaspar



www.medbone.eu

ORTOPANTOMOGRRAFIA PÓS-OP

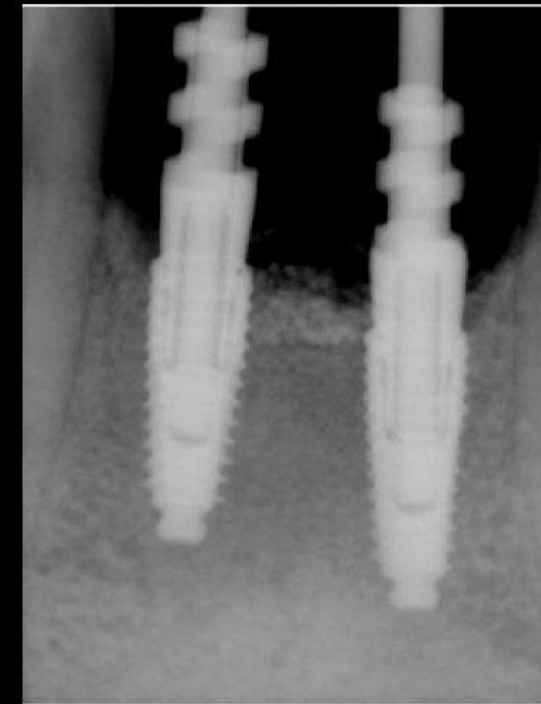
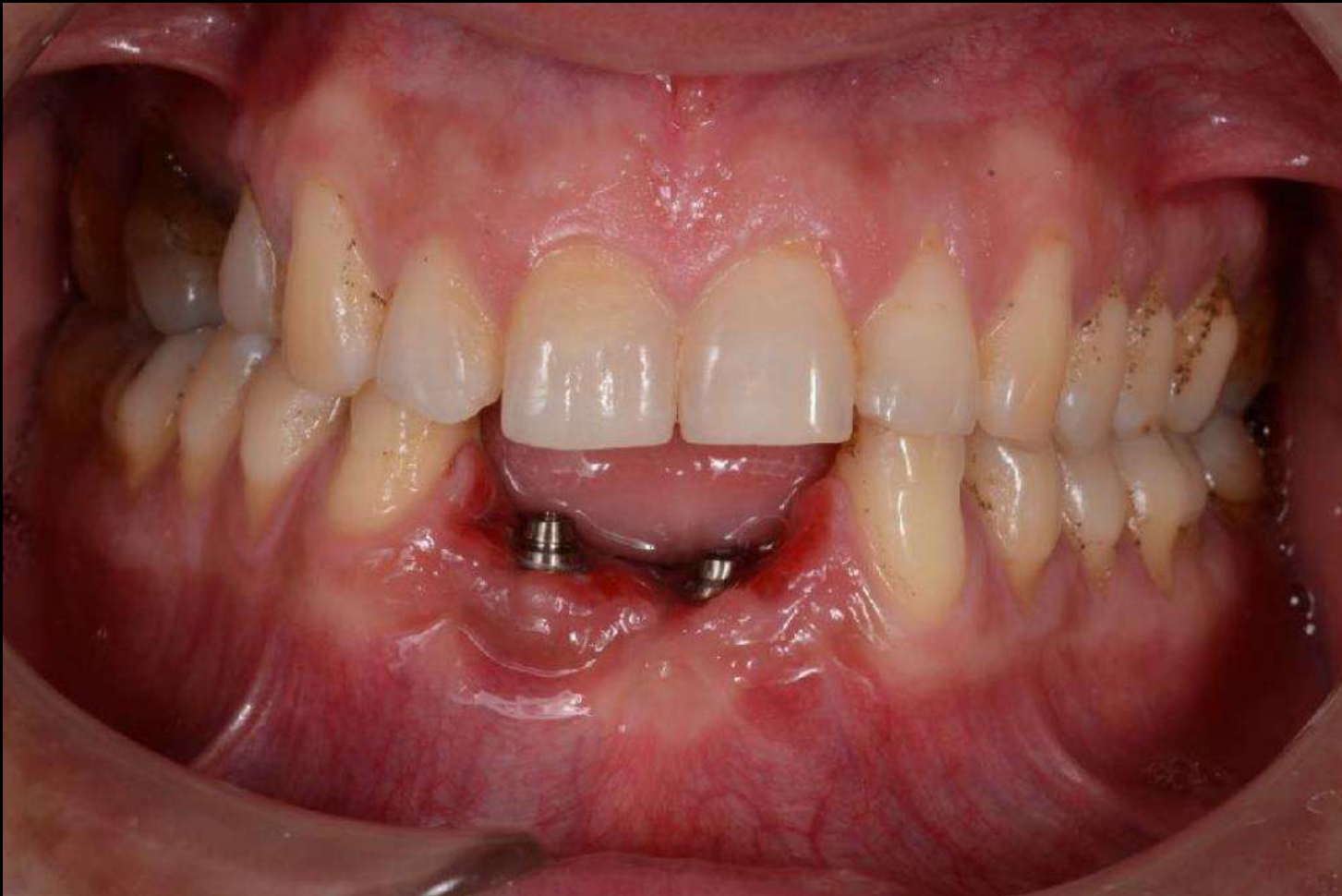

Dr. João Gaspar

Dr. João Gaspar



www.medbone.eu



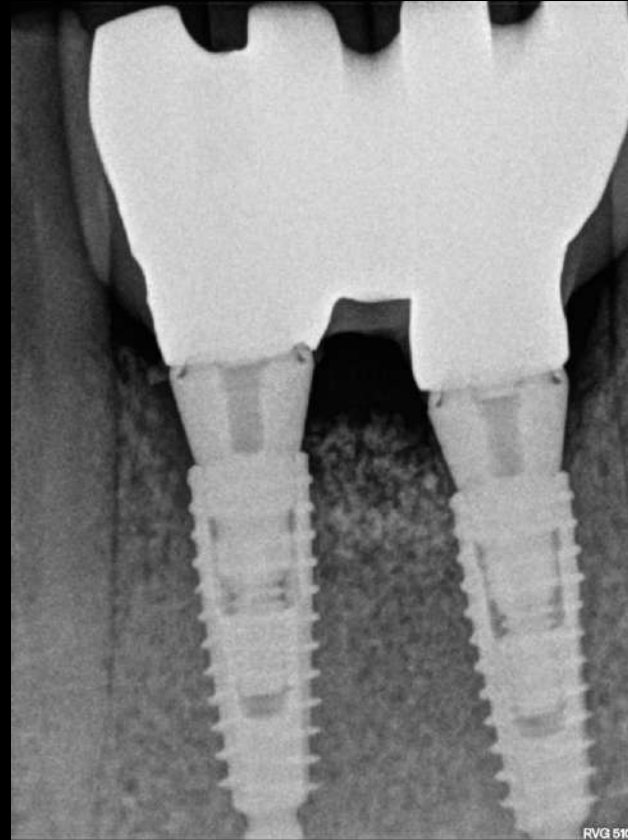
3 meses depois

Dr. João Gaspar



www.medbone.eu


1 ano pós-op



Dr. João Gaspar



www.medbone.eu



Medbone®
BIOMATERIALS

Centro Empresarial Lusoworld II
Rua Pé de Mouro, nº26-Linhó
2710-335 Sintra, Portugal
Tel: +351 211 941 737 | Mob: +351 913 511 583
e-Fax: +351 211 946 681
e-mail: info@medbone.eu

www.medbone.eu



Medbone® | Biomaterials, engineering life.™