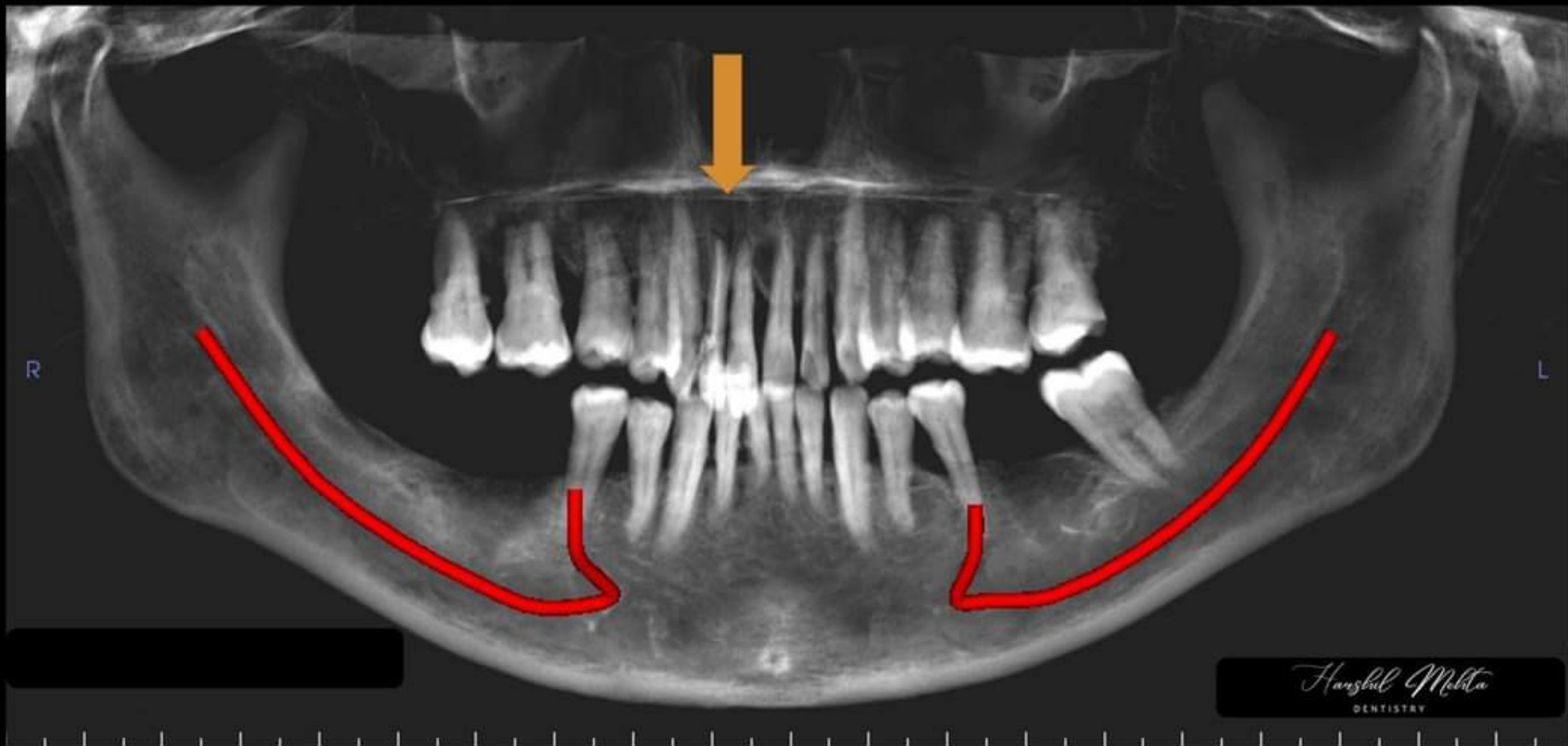


# Restoring with Implants In Aesthetic Zone



*Harshil Mehta*  
DENTISTRY

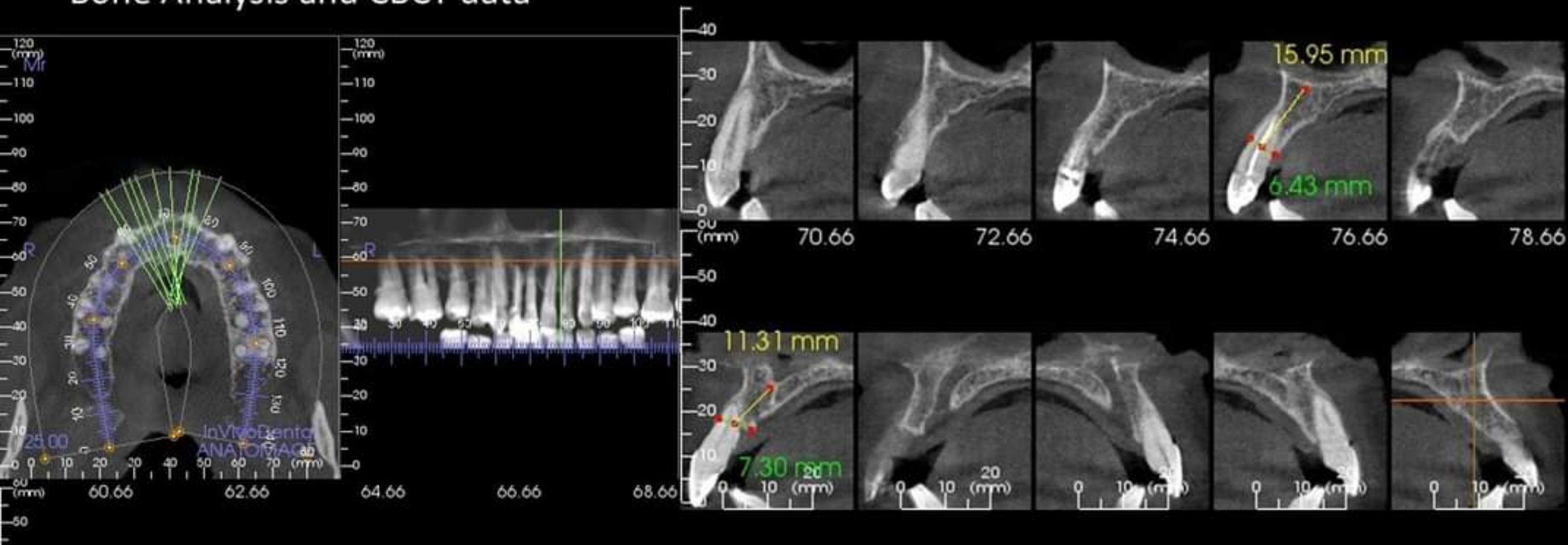




Pre-Operative Scenario: Age 71/M Patient  
Failing Upper Right central and lateral incisor ..

Clinically Grade II Mobility with mild supra-eruptions. History of Splint done to reduce mobility two years back

# Bone Analysis and CBCT data



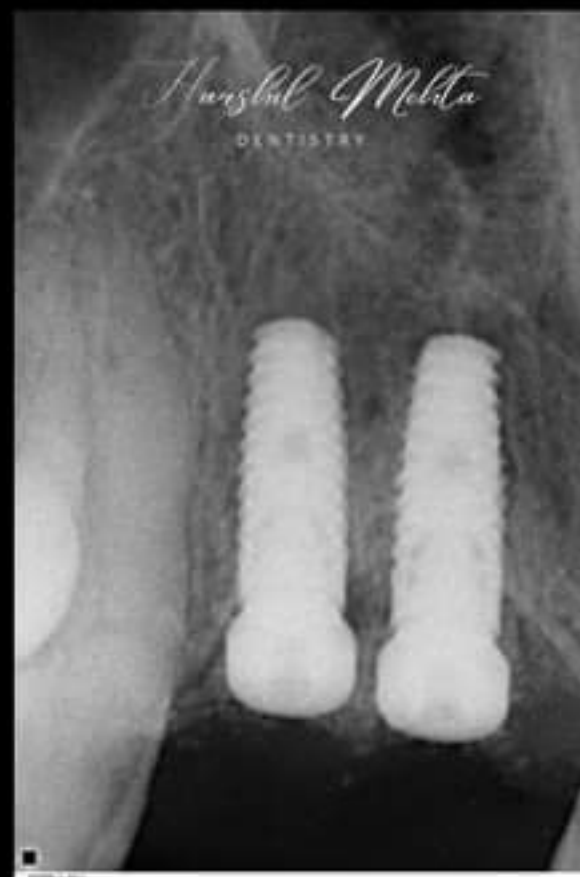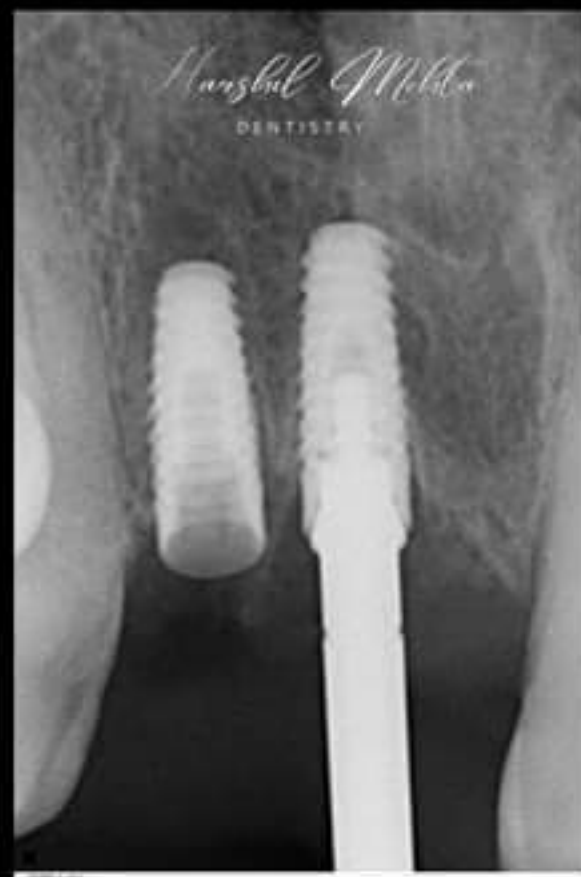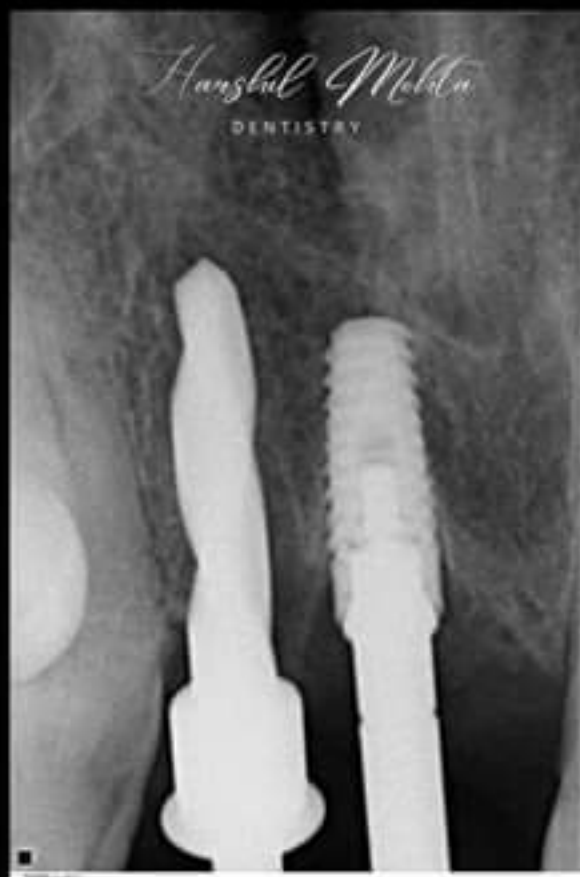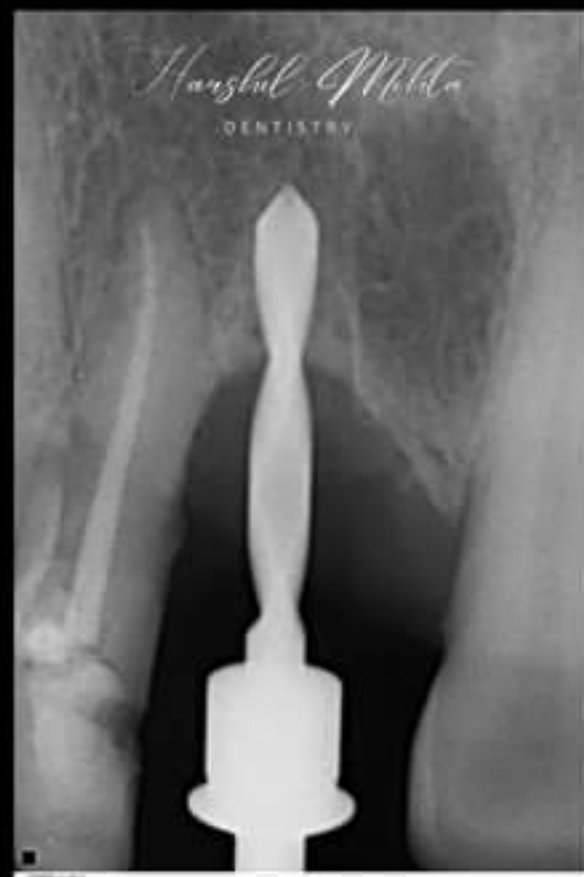## Treatment Plan:

Immediate Implant placement with IFIX..

Healing time for 5 months ( patient travelling abroad post implant placement )

DMLS Cement Retained Prosthesis

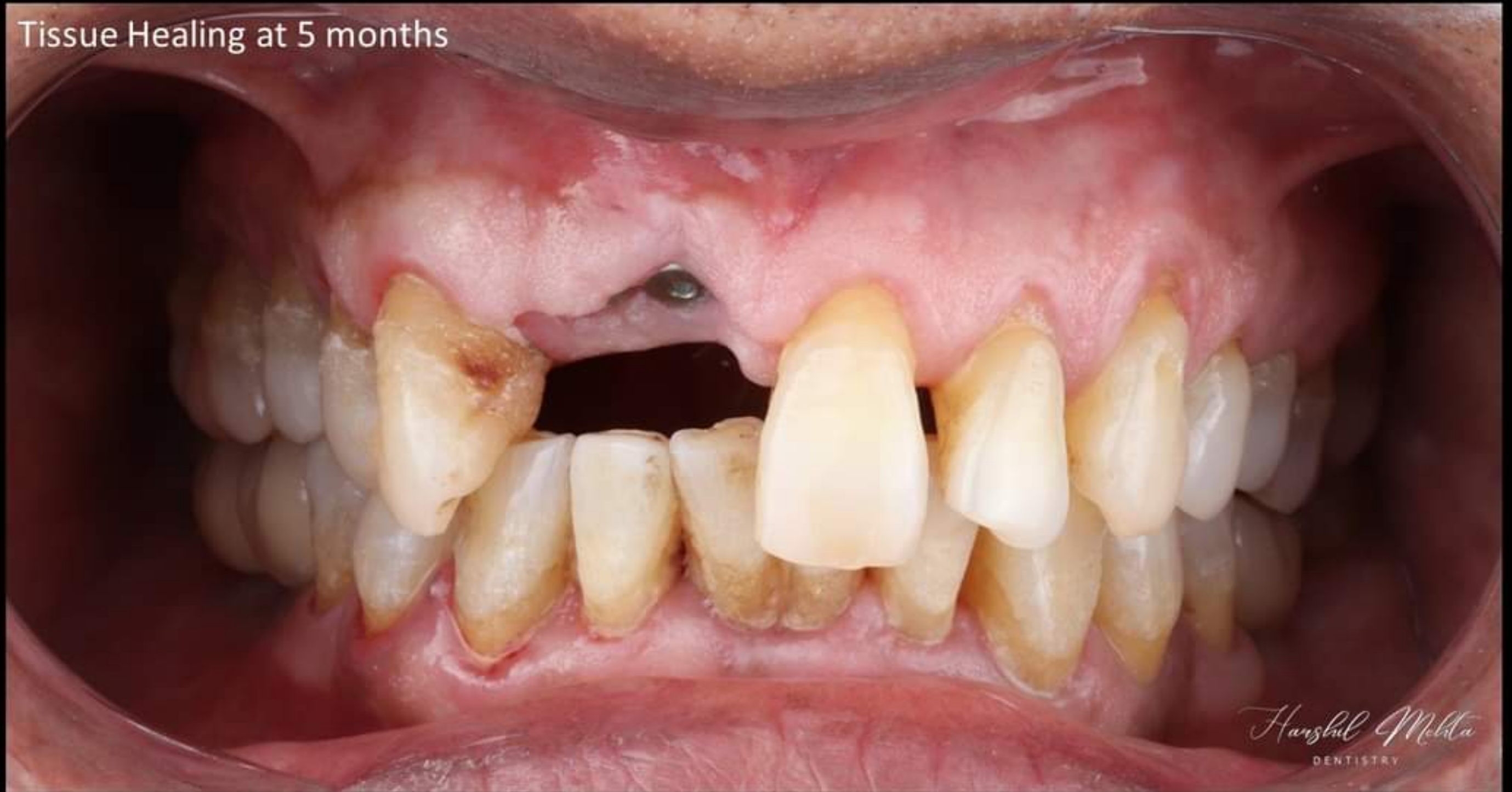# Implant Placement Protocol



Healing time was 5 months

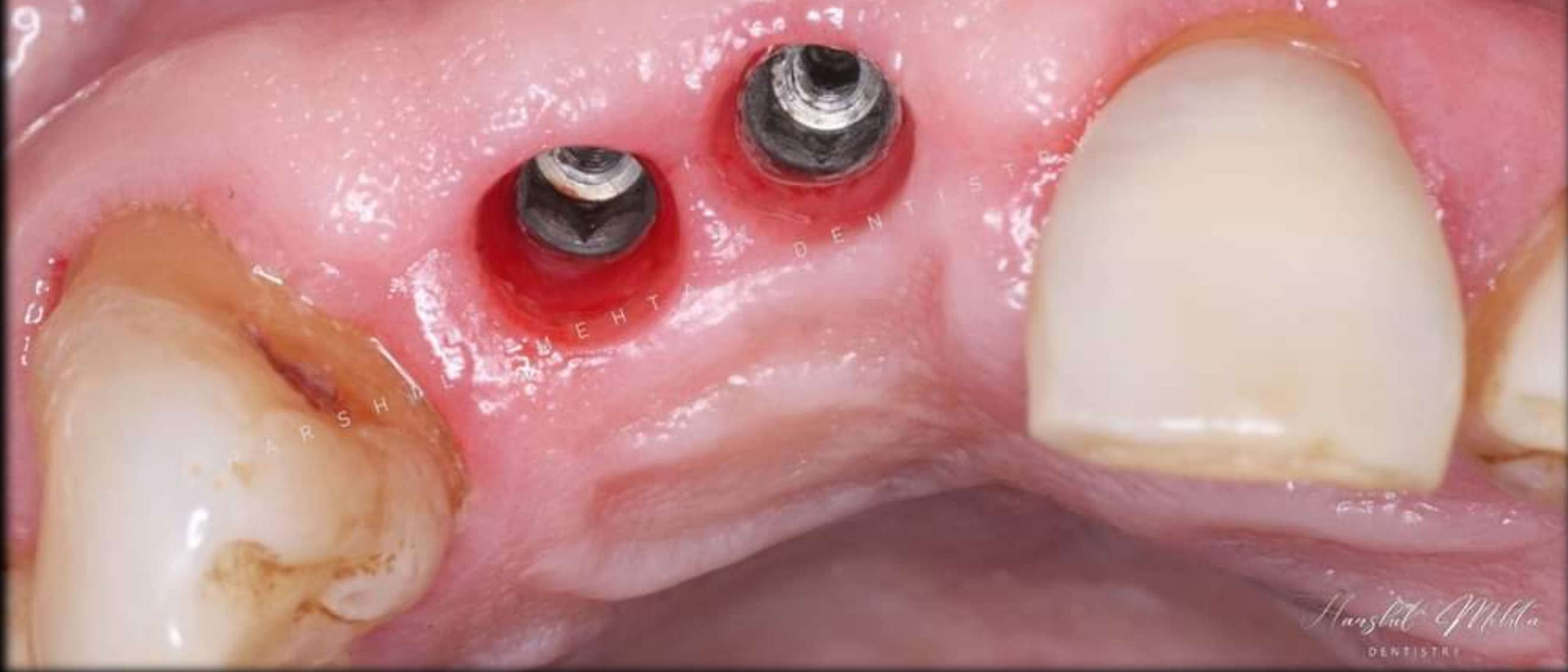Patient was given a flexible RPD for this time

Tissue Healing at 5 months

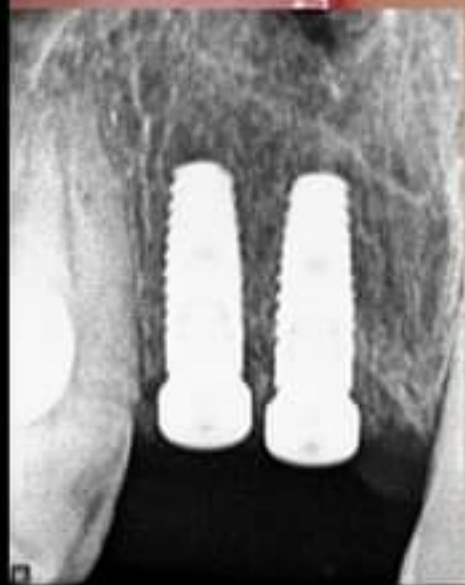

*Hanshil Mehra*  
DENTISTRY

# Tissue Contour



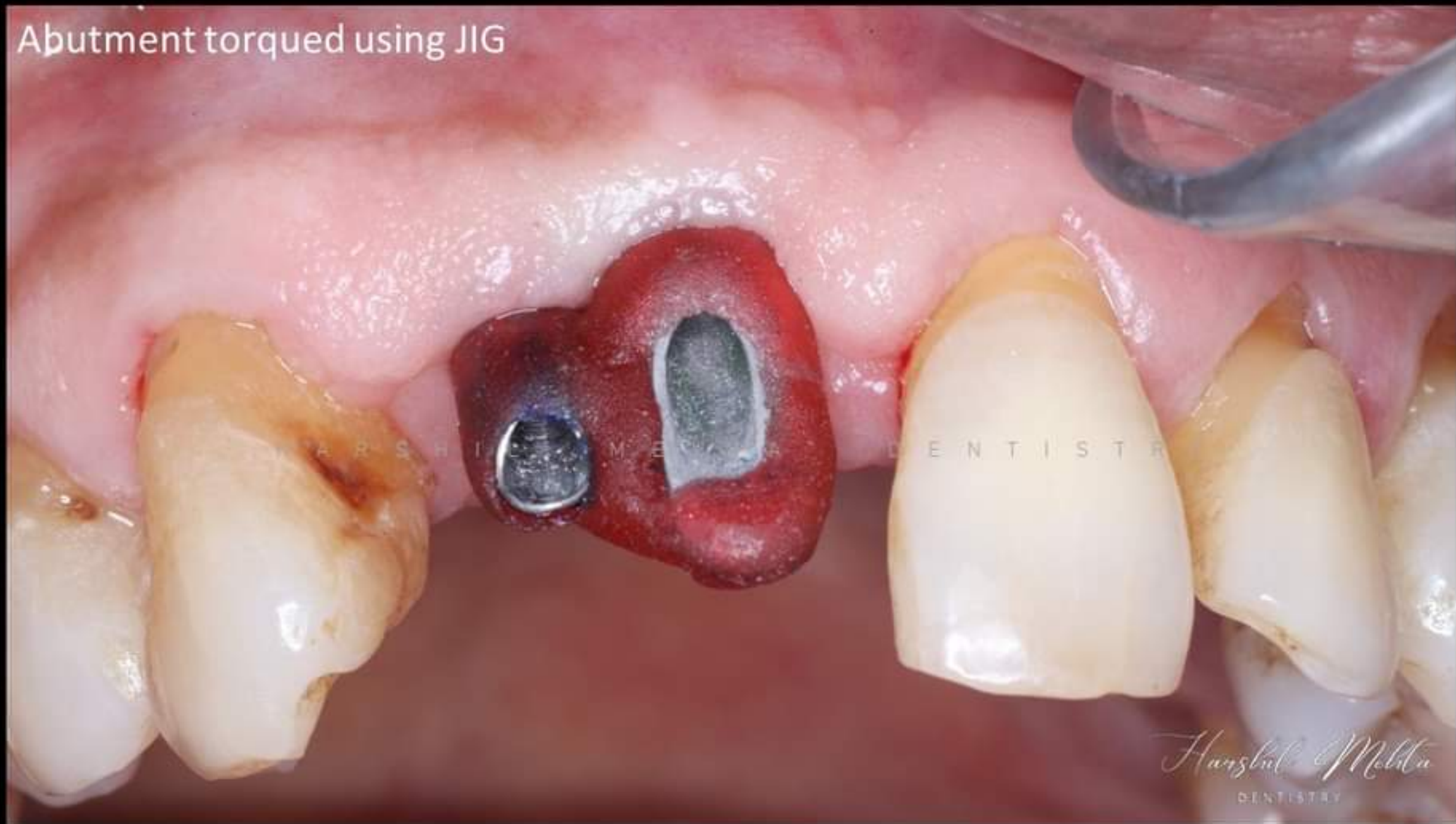Integration looks good . . !!



*Harshul Mohita*  
DENTISTRY

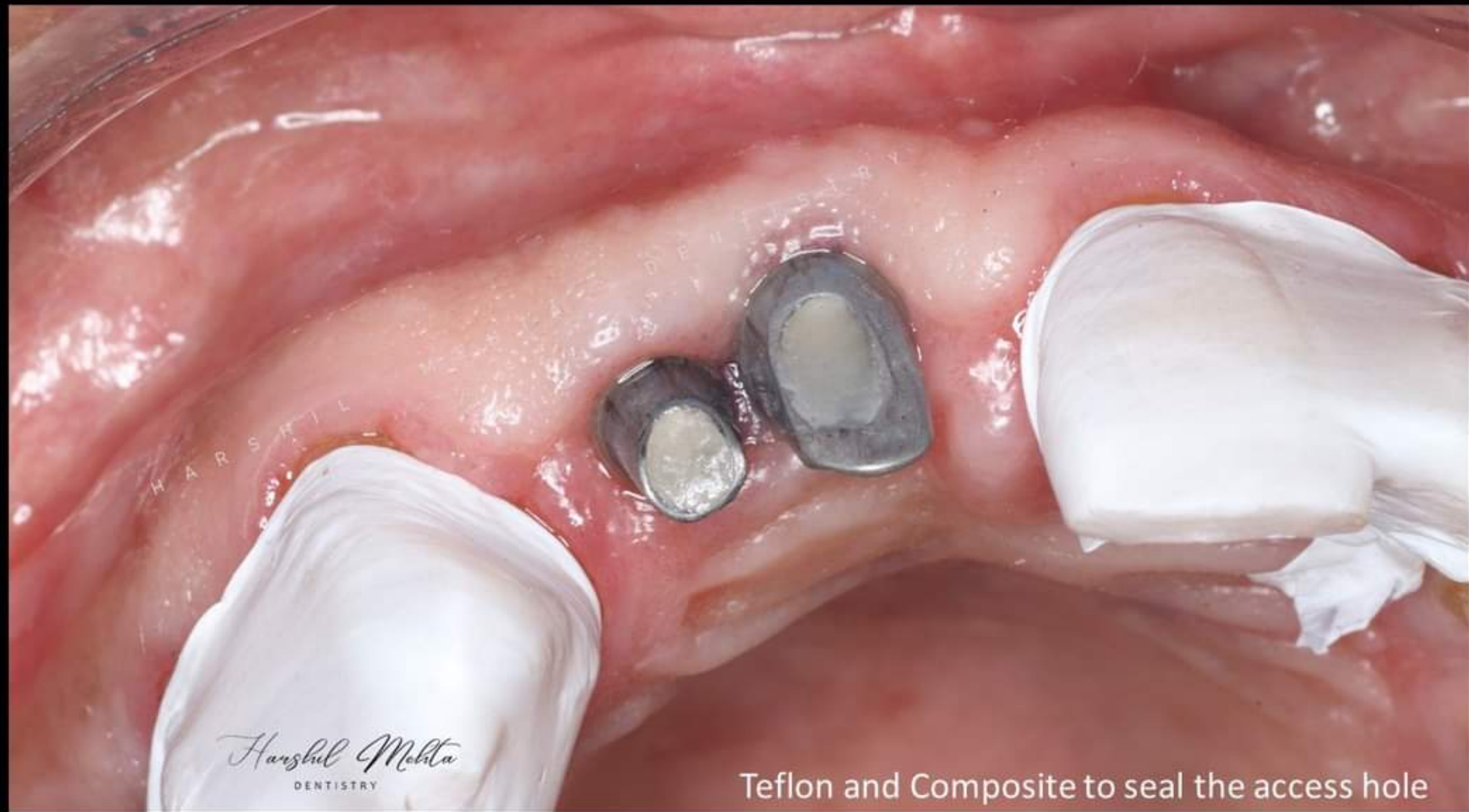

Abutment torqued using JIG



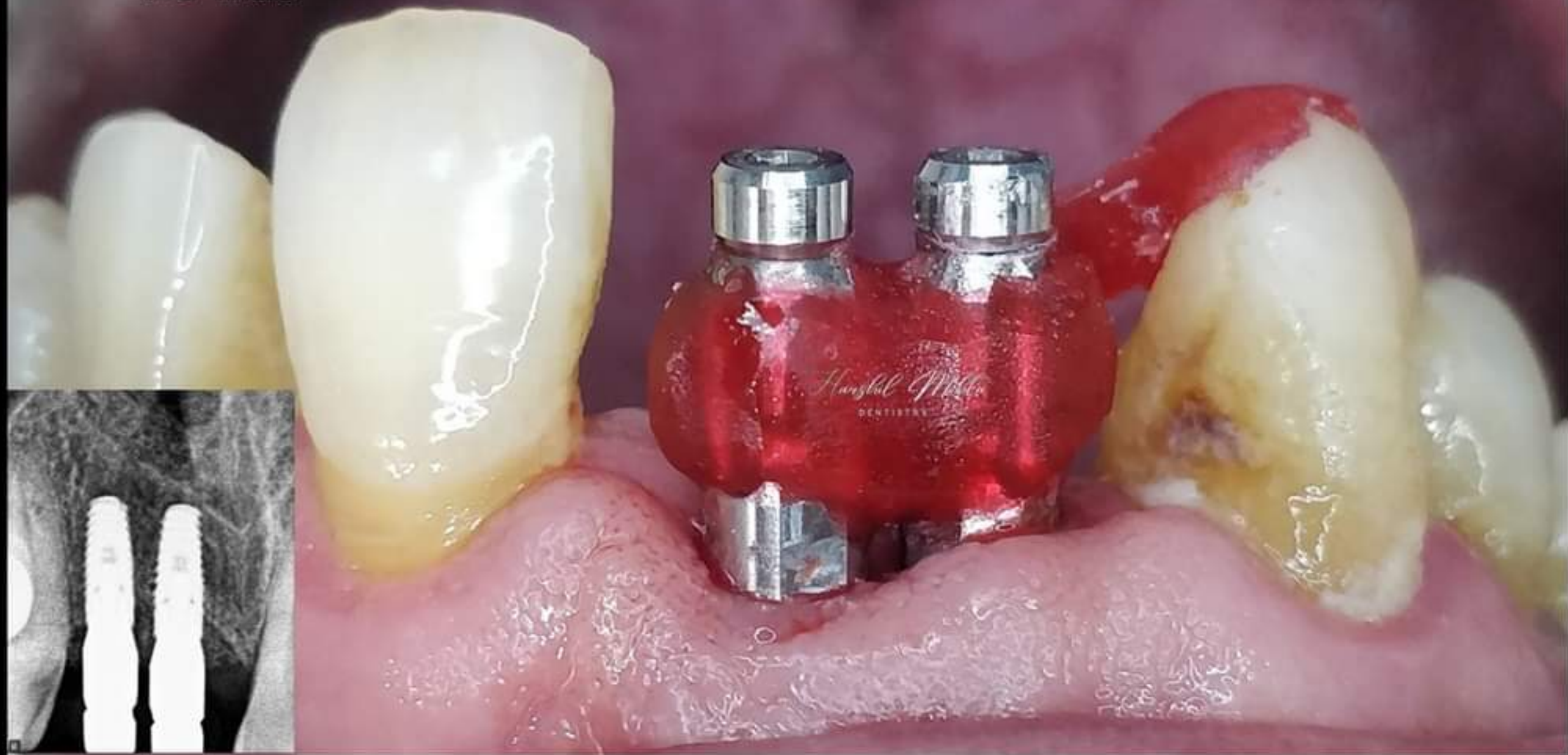DENTISTRY

*Hansbül Mehta*  
DENTISTRY

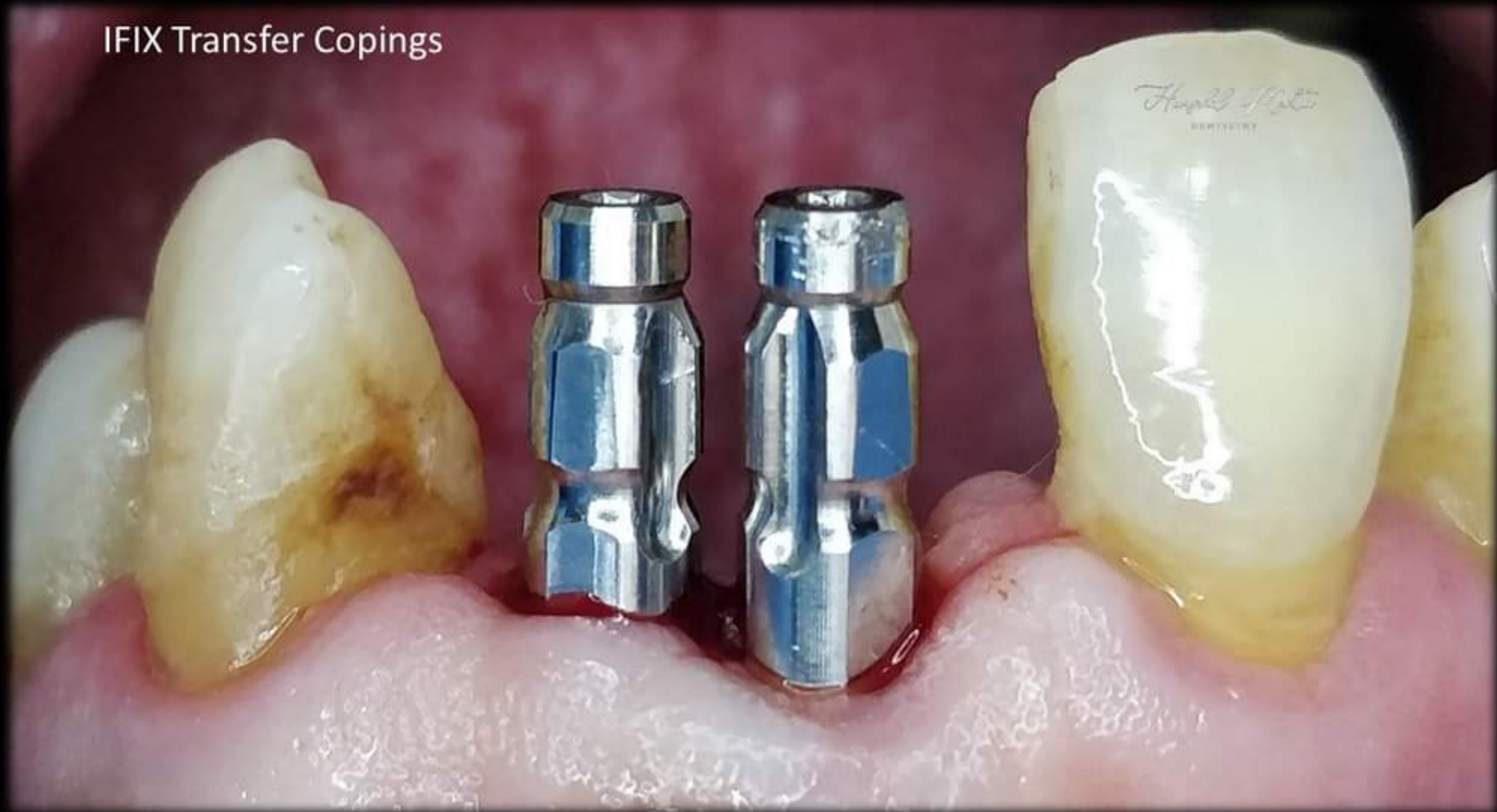

Teflon and Composite to seal the access hole

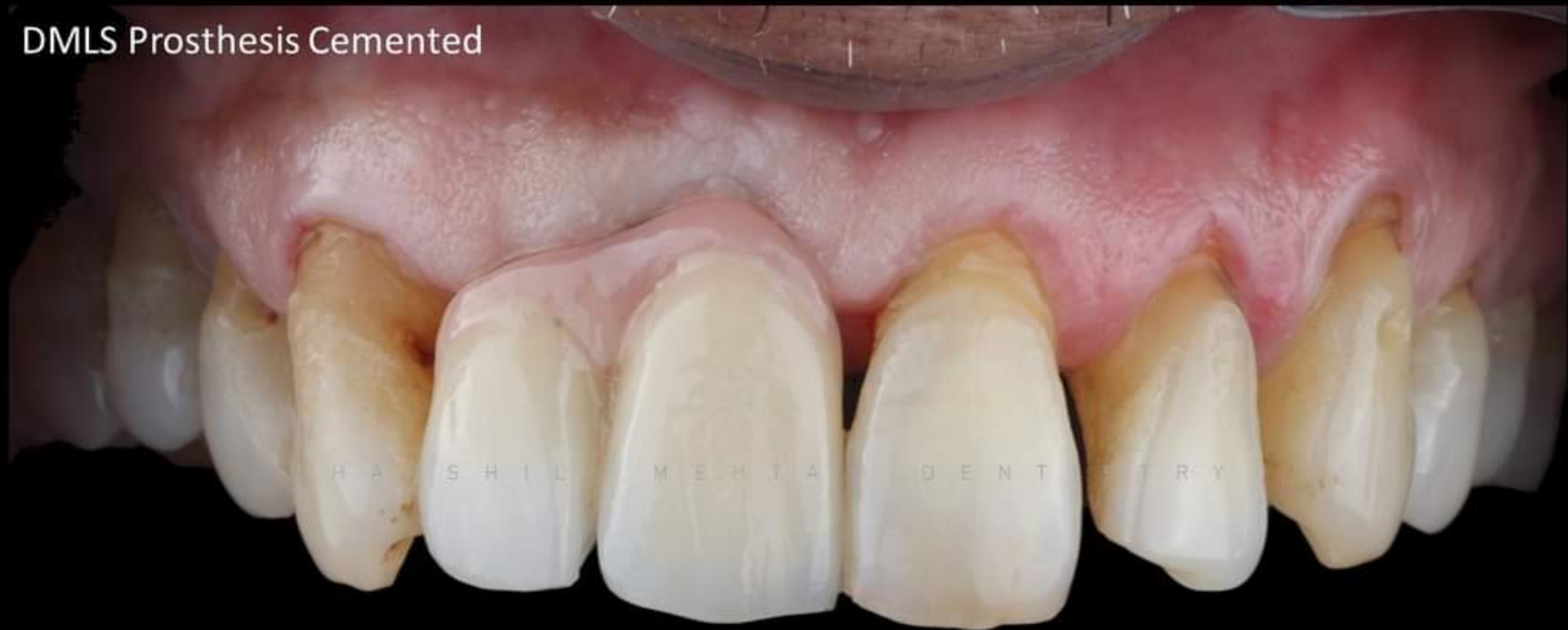JIG Trials



IFIX Transfer Copings



DMLS Prosthesis Cemented



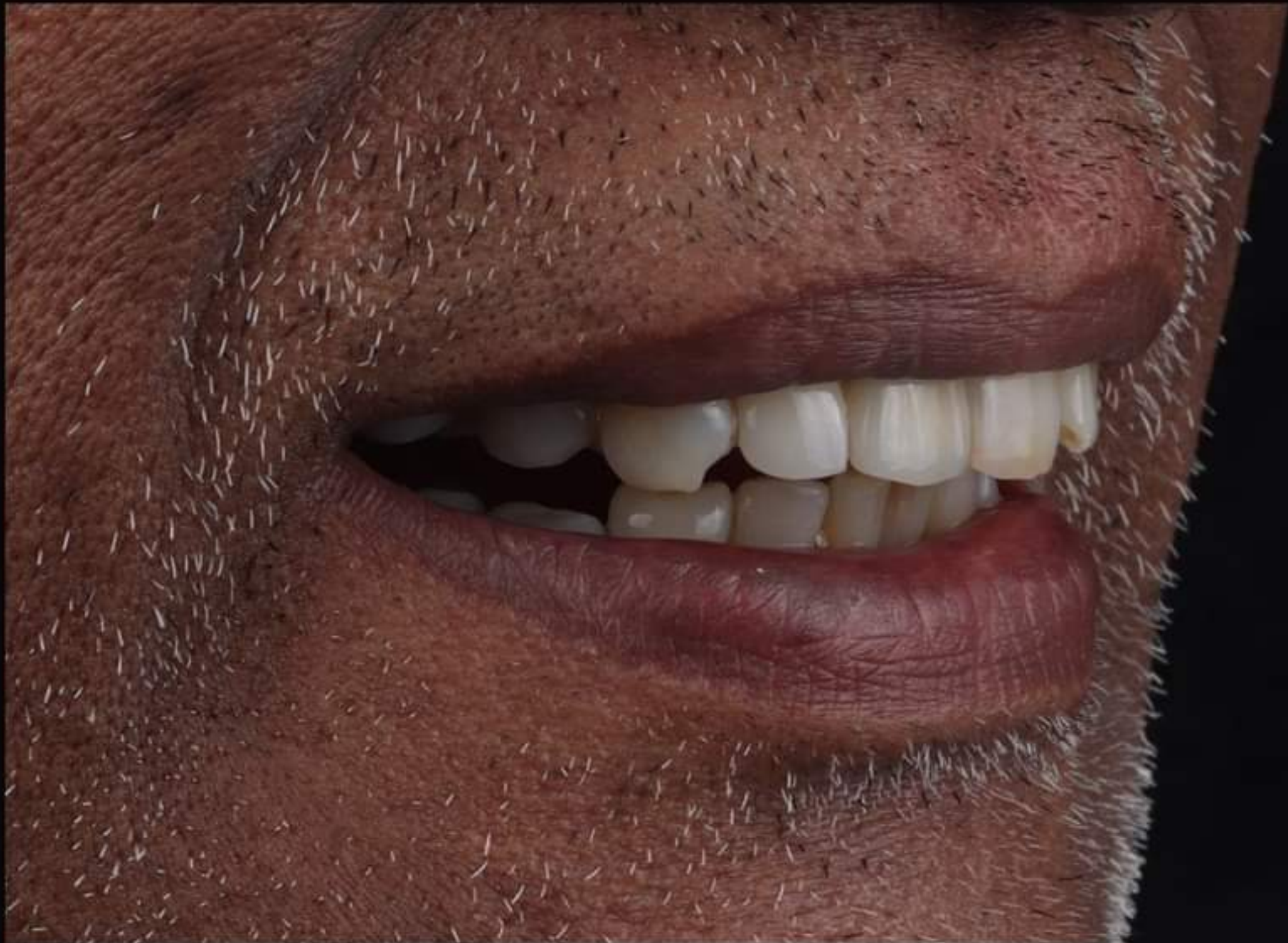
*Hashil Mehta*  
DENTISTRY

R S H L M E T A D E N T I S T R Y

*Harshul Mehta*  
DENTISTRY

H A R S H U L M E H T A D E N T I S T R Y

*Harshul Mehta*  
DENTISTRY



*Hanshil Mehta*  
DENTISTRY



*A journey of a thousand miles . .  
Begins..  
Just with a single Smile . !!*

Thank You

*Hanshil Mehta*  
DENTISTRY

