

Medbone®
BIOMATERIALS

Medbone® | Biomaterials, engineering life.™

Clinical Cases



Maxillary Sinus Lift- Dr. Fabião Castro Silva
Peri-Implantitis Regeneration – Dr. Hiram Fischer
Atraumatic Sinus Lift – Dr. Hiram Fischer

Maxillary Sinus Lift

Bone Graft: adbone®BCP (0.5 – 1mm) 0,5g

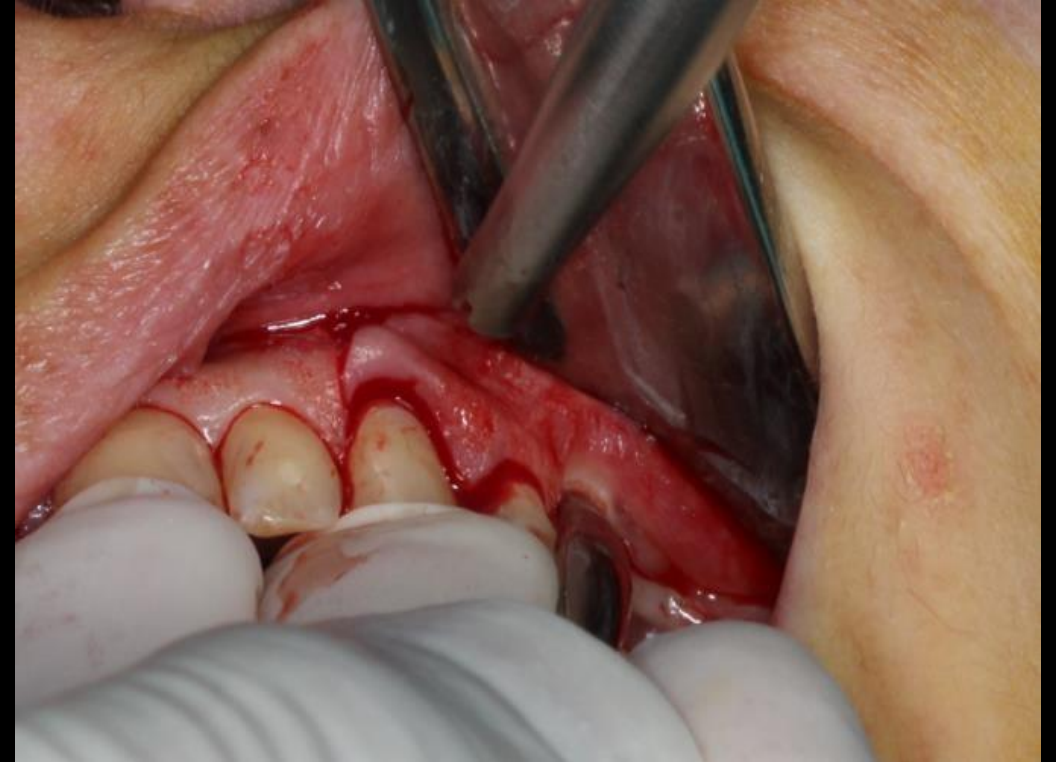
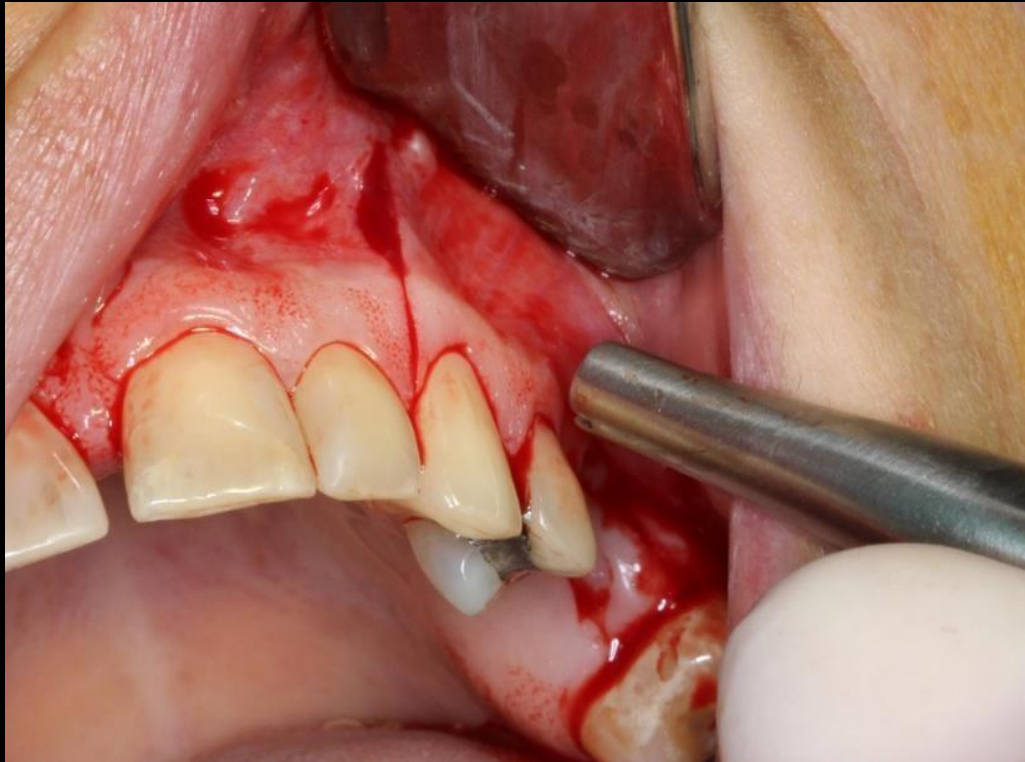
Patient: Female, 42 years

Company Profile

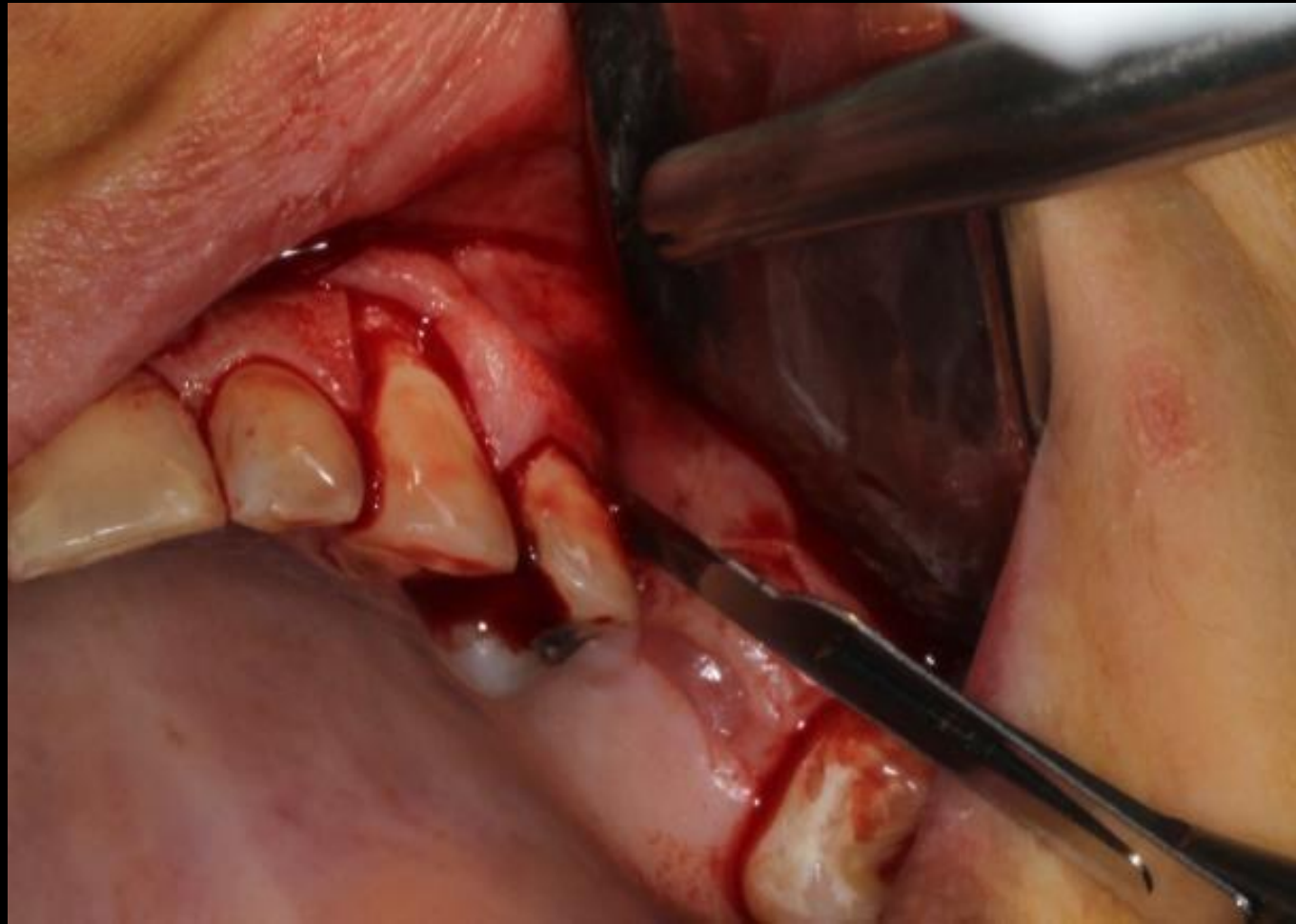

Medbone®
BIOMATERIALS

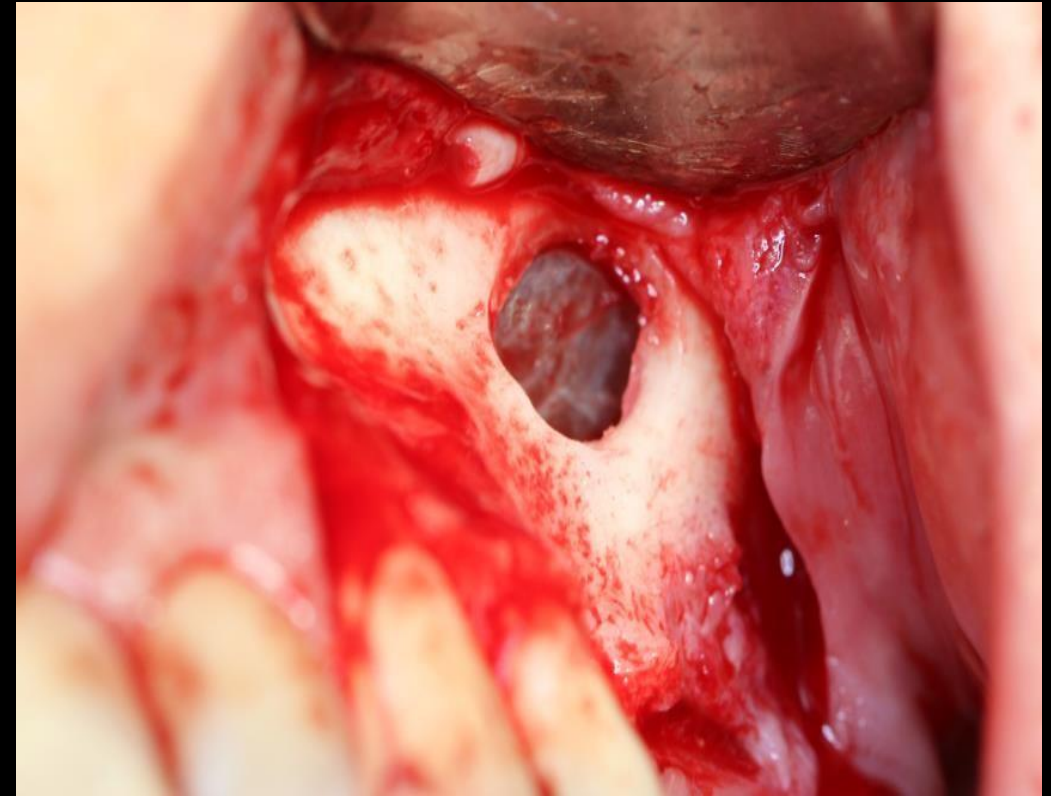
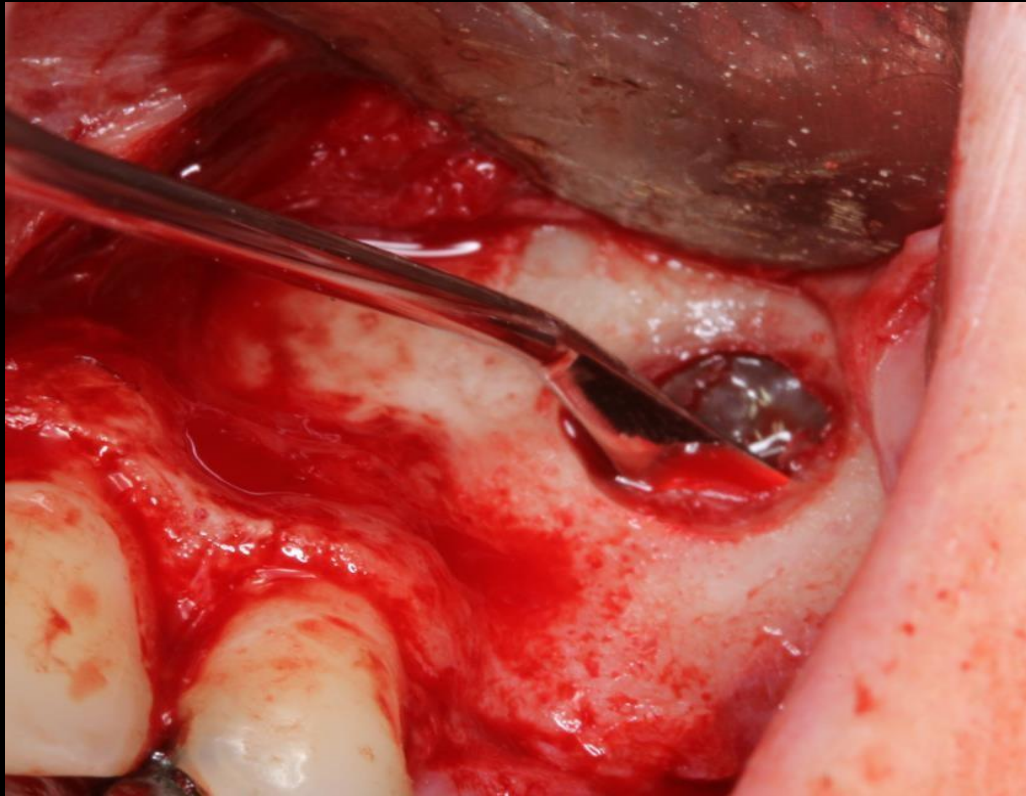
Dr. Fabião Castro Silva
Dentocarmo - Clínica Dentária do Carmo
Portugal



Maxillary Sinus Lift
Dr. Fabião Castro Silva - Portugal



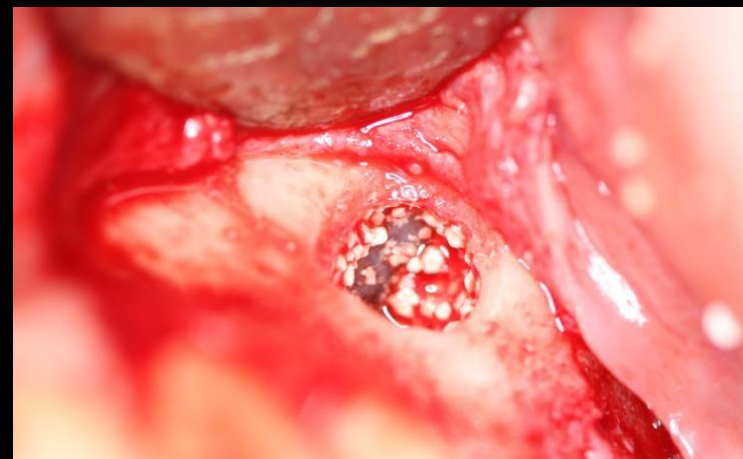
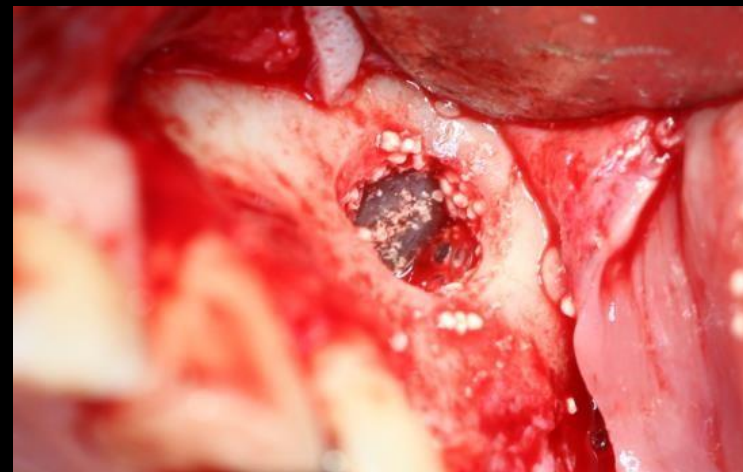
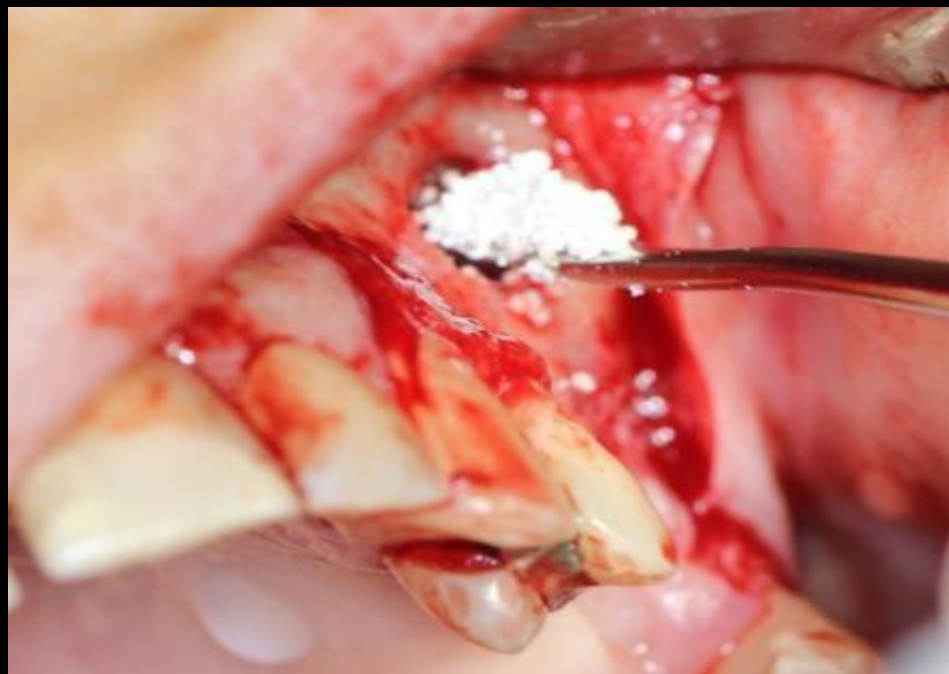Maxillary Sinus Lift
Dr. Fabião Castro Silva - Portugal



Maxillary Sinus Lift
Dr. Fabião Castro Silva - Portugal

Bone Grafting

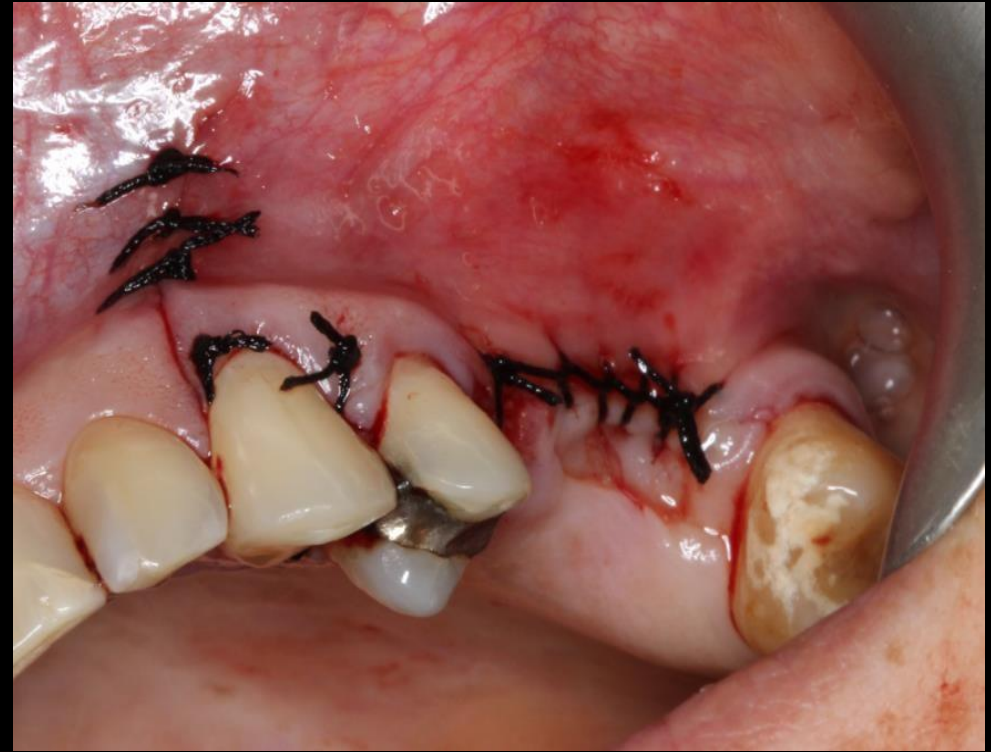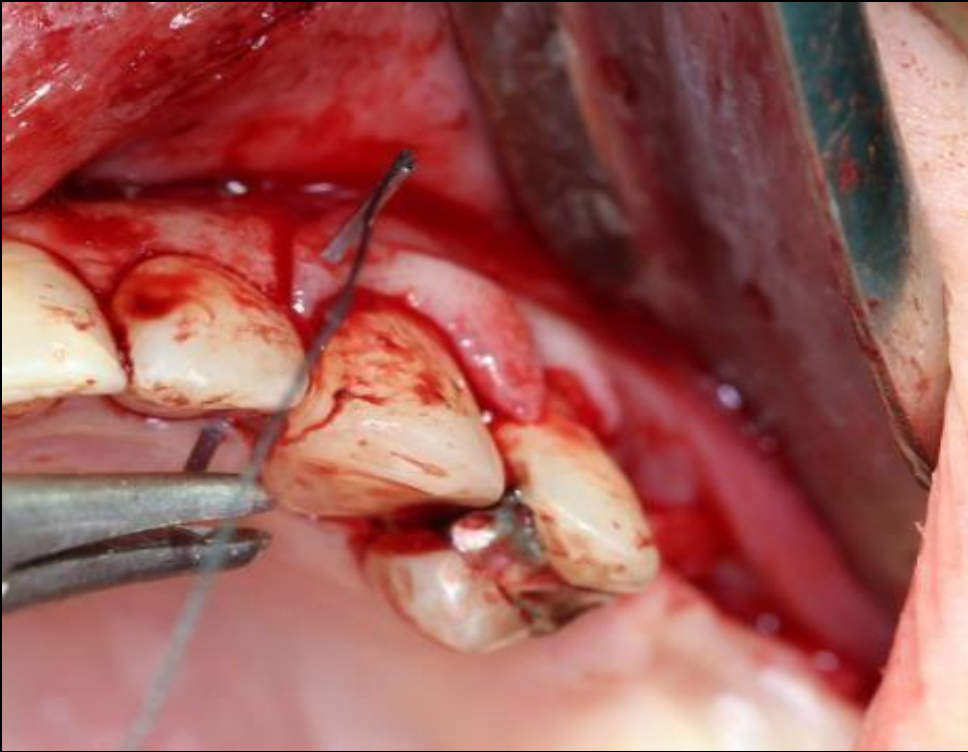
Filling of the sinus cavity with
adbone BCP



Maxillary Sinus Lift
Dr. Fabião Castro Silva - Portugal



Suture



Maxillary Sinus Lift
Dr. Fabião Castro Silva - Portugal



Peri-Implantitis Regeneration

Bone Graft: adbone ® BCP (0.1-0.5 mm) 0,5g

Pacient: Male, 41 years old



Medbone®
BIOMATERIALS

Dr. Hiram Fischer Trindade European
Implantology Center EIC
Portugal

Peri-Implantitis

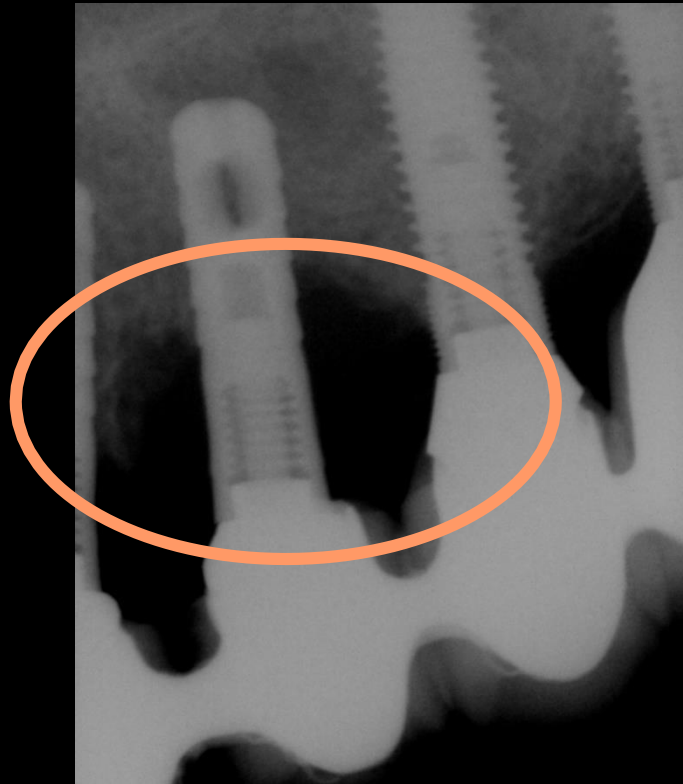
- Peri-implantitis is not only frequent, but a serious complication.
- Defined as a destructive inflammatory reaction that affects soft and hard tissues surrounding dental implants.
- Involves the loss of supporting bone in the tissues surrounding a functioning implant.

Outcome

- Male patient with 41 years old presented a severe peri-implantitis condition. And the bone around the previously placed implant was lost.
- Due to that severe bone loss, bone grafting ([adbone](#)® BCP, 0.1 – 0.5mm, 0,5g) was used as a surgical treatment of peri-implantitis.
- Radiographic follow-ups allow to observed the improvement in bone density in this case.

Peri-Implantitis

Implant with Peri-Implantitis and Hydroxyapatite Surface.



Bone defect around the dental implant, due to a inflammatory process



Laser treatment followed by bone grafting with adbone BCP 0.1-0.5 mm (0.5g)

**Peri-Implantitis Regeneration
Dr. Hiram Fischer Trindade - Portugal**

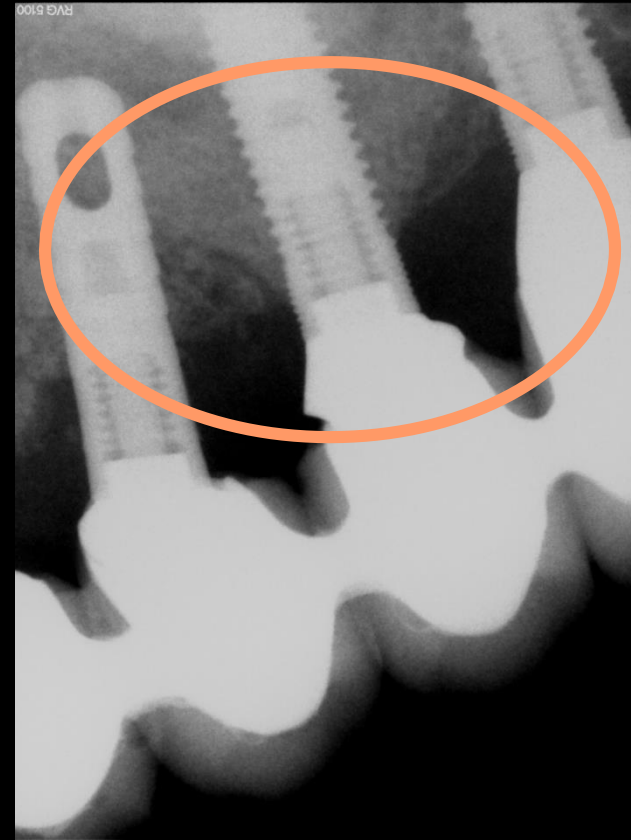


Peri-Implantitis

**2 months follow-up
(after grafting)**



**No signs of
inflammation or
contamination**



**Peri-Implantitis Regeneration
Dr. Hiram Fischer Trindade - Portugal**



Atraumatic Sinus Lift

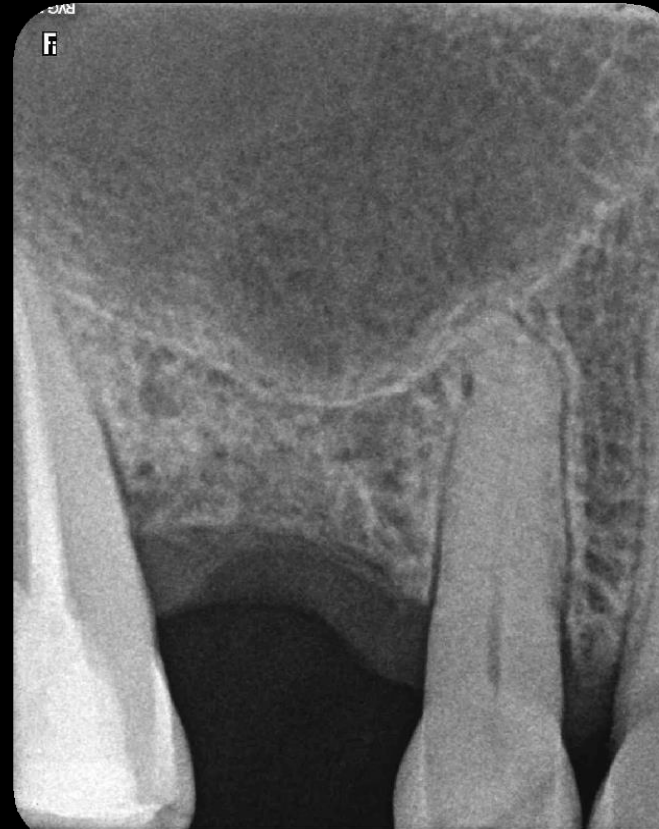Bone Graft: adbone®BCP (0,5-1 mm) 1g

Patient: Female, 50 years old



**Dr. Hiram Fischer Trindade European
Implantology Center EIC
Portugal**

Initial x-ray
image showing
the extension of
crestal defect

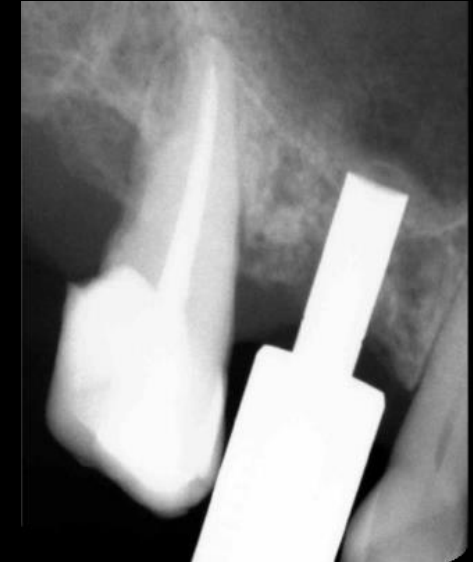
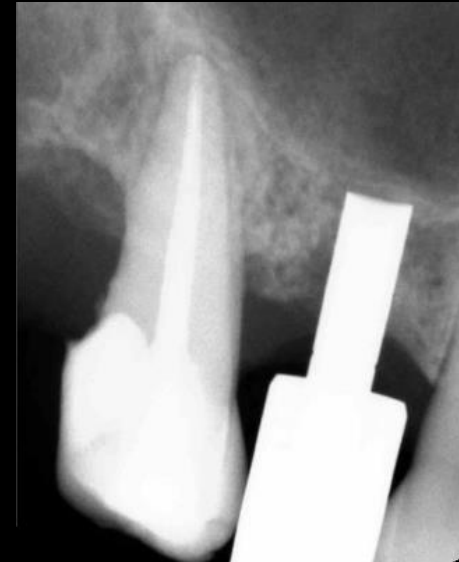
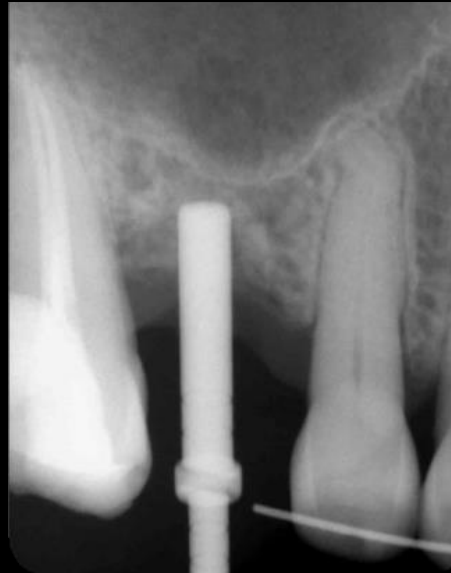
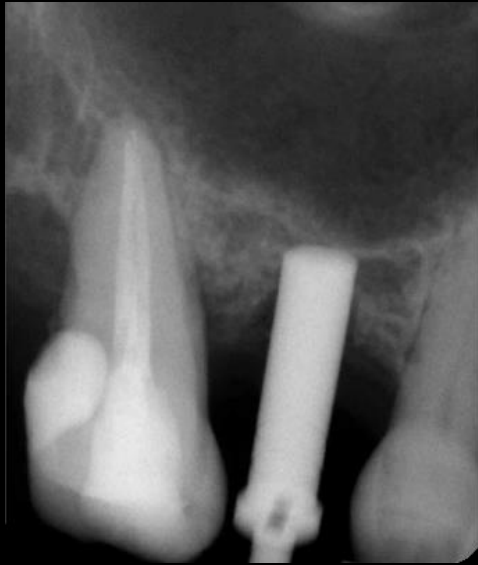Atraumatic Sinus Lift
Dr. Hiram Fischer Trindade - Portugal



www.medbone.eu

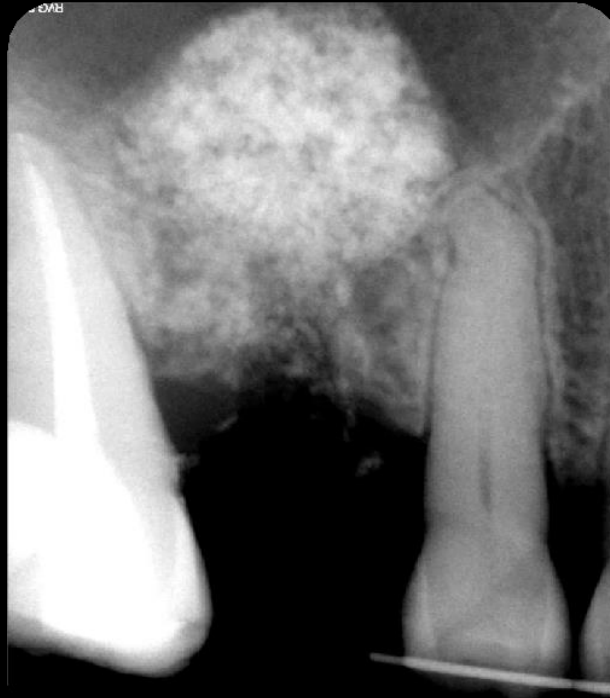Placement of adbone BCP in the defect.



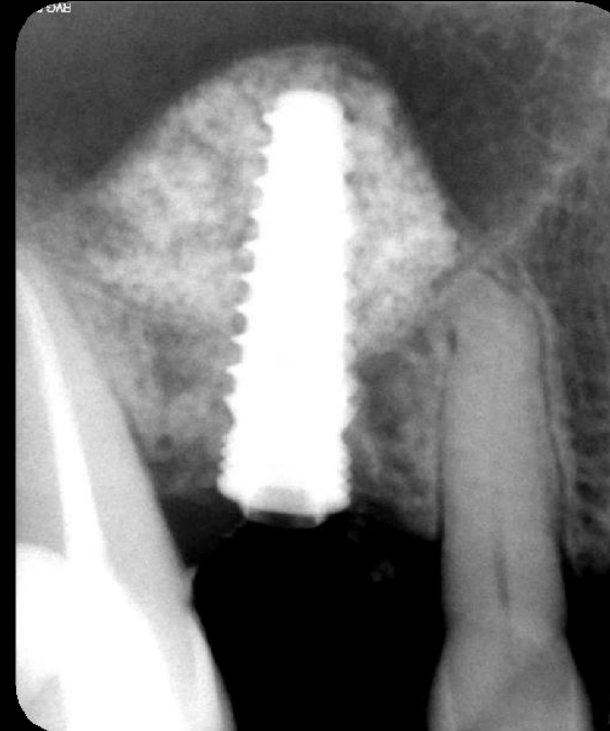
Atraumatic Sinus Lift
Dr. Hiram Fischer Trindade - Portugal



Adbone BCP



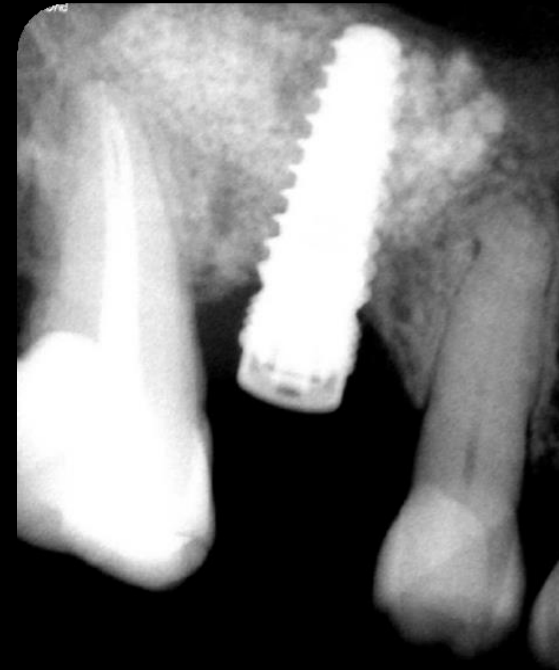
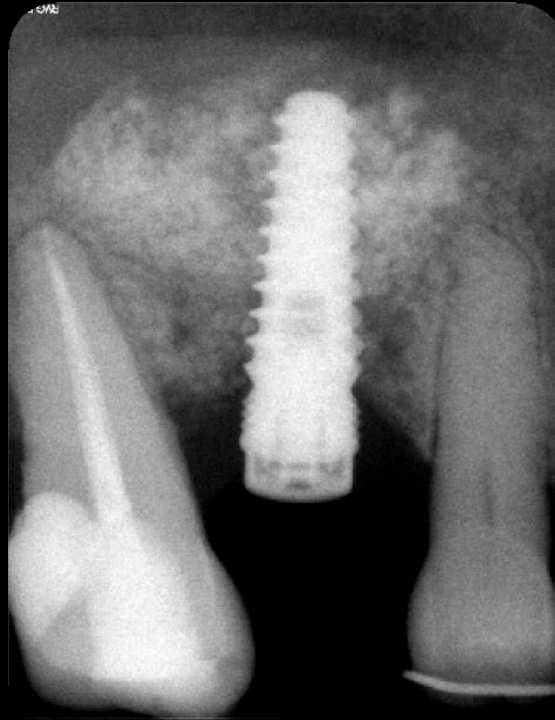
Implant Placement following bone grafting procedure



Atraumatic Sinus Lift
Dr. Hiram Fischer Trindade - Portugal

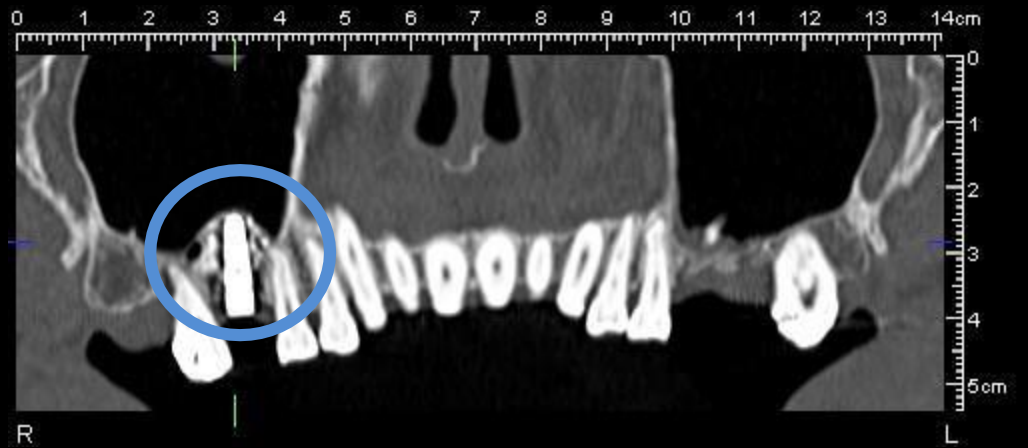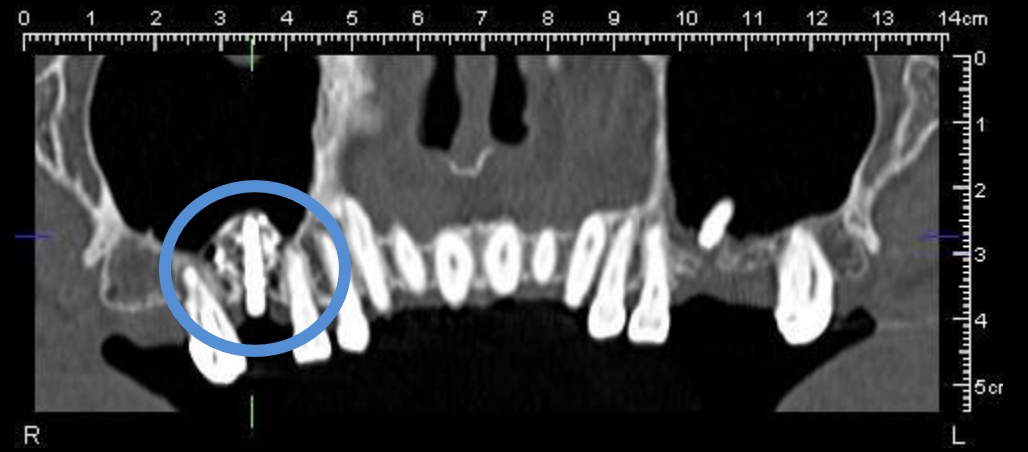
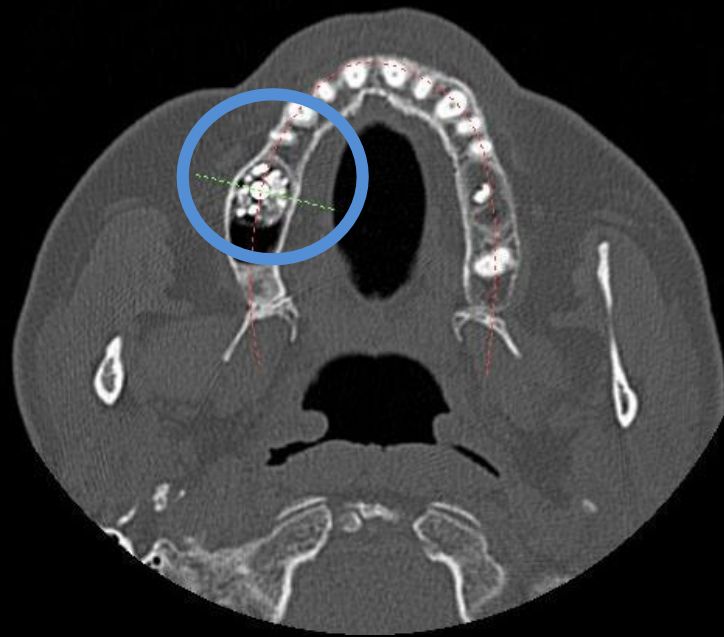
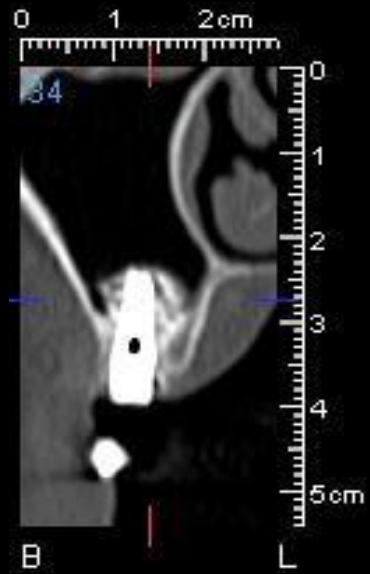


Control X-Ray after 12 months from surgery
evidenced the graft integration



Atraumatic Sinus Lift
Dr. Hiram Fischer Trindade - Portugal





Atraumatic Sinus Lift
Dr. Hiram Fischer Trindade - Portugal





Medbone®
BIOMATERIALS

Centro Empresarial Lusoworld II
Rua Pé de Mouro, nº26-Linhó
2710-335 Sintra, Portugal
Tel: +351 211 941 737 | Mob: +351 913 511 583
e-Fax: +351 211 946 681
e-mail: info@medbone.eu

www.medbone.eu



Medbone® | Biomaterials, engineering life.™